

Toxic changes in some organs of rats exposed to hypervitaminosis A during different gestation period

F. M. K. AL-Rekabi

Dep. of Physiology & Pharmacology College of Vet. Med. Uni. of Baghdad

Summary

Forty females albino rats divided into four groups, three of them (T1, T2, T3) dosed orally with 10000 IU Vitamin A according to different gestation periods while the fourth group dosed with distilled water and considered as control (C). Statistical changes in the weight of different treated groups organs were observed specially in the T3 group that represent period of major organo-functional development and minor organogenesis. Also the histopathological study revealed sever liver necrosis and sever pulmonary hyperplasia in T1 group. Also there was subcutaneous abdominal tumor (fibroma) noticed in one female of T2 group. We concluded from our results that high dose of vitamin A may cause cellular, histological and functional defects with possible cryogenic effect in some internal organs and tissue.

التغيرات السمية في بعض أعضاء الجرذان المعرضة لجرعة عالية من فيتامين A خلال

مراحل الحمل المختلفة

فلاح موسى كاظم الركابي

فرع الفسلجة والأدوية/ كلية الطب البيطري/ جامعة بغداد

الخلاصة

استخدمت في هذه الدراسة أربعون من إناث لجرذان المهقاء وقسمت إلى أربع مجاميع، جرعت المجاميع الثلاث الأولى منها بعشرة آلاف وحدة دولية من فيتامين A عن طريق الفم وكانت مدة التجريب حسب مراحل الحمل المختلفة في حين اعتبرت المجموعة الرابعة مجموعة سيطرة وجرعت بالماء المقطر. لقد أظهرت نتائج التحليل الإحصائي هناك فروقات معنوية في أوزان الأعضاء الداخلية المجاميع المعالجة وكانت بصورة ملحوظة في حيوانات المجموعة الثالثة التي مثلت مرحلة التطور الوظيفي في الأعضاء الداخلية. بينما أظهرت نتائج الفحص النسيجي المرضي تنكس شديد في خلايا الكبد وفرط تنسج رئوي شديد أيضا في حيوانات المجموعة الأولى، تم تسجيل حالة ورم ليفي تحت الجلد في منطقة البطن في إحدى حيوانات المجموعة الثانية. نستنتج من دراستنا هذه بان الجرعة العالية لفيتامين A قد تؤدي إلى عيوب أو تغيرات خلوية ونسجية ووظيفية مع احتمال وجود تغيرات وراثية خلوية.

Introduction

The term vitamin A is used generically to include number of compounds which have certain effect in the body of living organism, They divided into two main categories performed vitamin A which is mostly retinal or retinol that concentrated almost in butter and liver while provitamin A that known as carotenes concentrate in plant pigment as betacarotene and converted inside the body into vitamin A. (1), (2).

Habitual food intakes of many nations such as Eskimo depended on polar bear liver consumption which has high level of vitamin A as well as many vitamin A toxicosis reported in explorers of aquatica and selder dogs wick consumed polar bear liver. Vitamin A toxicity reported due to uses of its pharmaceutical preparation and its analogs such as retinoic acid, tretinoin and isotretinoin especially in pregnant females that are suffering from psoriasis, lcthyosis and acne vulgaris (3).

Poultry mass production increases use of vitamin A as food additive and supplement for improving growth and production which may lead public health hazard for the consumer since most of vitamin A are stored in liver & fat as well as it reported to be resist heat processes.

The aim of this study is to explore the possibility of histopathological and weight changes in different organs of treated pregnant rats ingested high dose of vitamin A .

Material and Methods

Forty females and twenty males albino rats was used .The females were divided into four groups according to Protocol of FDA (4). The treated groups (T1, T2, T3) represented Three trimesters of pregnancy while the fourth group (C) considered as control.

The females of the first group (T1) given by stomach tube with 10000 IU of water soluble retinal (Roch)* for fourteen days before pregnancy till the day fifth of it which consider as period of implantation and plastocyst formation and mated with males given by the same dose for two months before mating. The females of the group (T2) given also by same dose but from day sixth 6th till the day sixteenth 16th of pregnancy representing major organogenesis period of embryo, the females of third group (T3) considered as period of minor organogenesis and major functional development and given the same dose from the day sixteenth 16th till the end of pregnancy.

The fourth group (C) was given distilled water fourteen days before pregnancy till the delivery, Females of (T2 , T 3 ,C) groups mated with control males (given distilled water orally), all animals housed one month before treatment in (4x5) m² room in cages (20 x 30 x 5) cm³ diameter at ratio of three animals per- cage and provided with the food and water ad-libitum at

temperature of (22 ± 3) C° and 14/10 hours light/darkness(5).Analysis of variance (F- test) used to compare the results of treated and control groups.

Results

There sults of this study showed:

1-The statistical changes in weight of different treated groups organs (liver, spleen, lung, uterus, ovaries, kidneys) were observed specially in T3 group (Table 1).

Table : 1 The organs weights of different female rats gruops ingested 10000 . IU Vit. A in different period of pregnancy .

Groups	Left Kidney /gm M ± SE	Right Kidney /gm M ± SE	Left ovary /gm M ± SE	Right ovary /gm M ± SE	Uterus /gm M ± SE	Lungs /gm M ± SE	Spleen /gm M ± SE	Liver/gm M ± SE
T1	1.07 ± 1.1 ac	1.003± 0.12 b	0.44± 0.4 a	0.53± 0.5 a	1.39± 1.7 c	2.46± 0.42 a	0.9± 0.42 a	10± 1.2 ab
T2	0.76 ± 0.05 a	0.84 ± 0.1 b	0.2± 0.05 a	0.25± 0.5 b	1.06± 0.9 c	2.58± 0.79 a	0.76± 0.2 a	9.53± 1.1 ab
T3	0.85 ± 0.05 a	0.83± 0.08 b	0.65± 0.05 ab	0.8± 0.14 ab	3.57± 0.45 d	1.79± 0.9 b	07± 0.15 b	11.13± 0.42 b
C	0.89 ± 0.05 a	0.93± 0.1 b	0.24± 0.11 a	0.29± 0.01 a	3.58± 0.23 d	2.42± 0.6 a	0.85± 0.1 a	9.54± 1.4 b

The different letters mean statistical differences at $p < 0.01$.

2-Histopathological study revealed:

A- Liver: - sever pathological changes founded in group T1 included odema in between Liver cells, congestion, liver cores, mass tissue in center of central vein and some cells undergo degenerative necrotic changes(Figure 1)

B-Lungs : - different changes noticed in different groups included sloughing of epithelial lining bronchioles, hyperplasia of epithelial bronchiol, bronco pneumonia, emphyzema, but more sever and typical lessions noticed in the group (T1) animals as abscess, hyperplasia changes of interalveolar tissue and liquifective type of necrosis (Figure 2) .

C-Fibroma: - A subcutaneously abdominal tumor mass, weighed 10.97 gm with diminitions (2x2) cm noticed in group (T2) female (Figure 3). The histological picture indicated fibrocystic proliferation, new highly formed tunnels or vessels with thickness that considered as highly collagenous and fibrous tissue with the presence of glands in area (Figure 4).

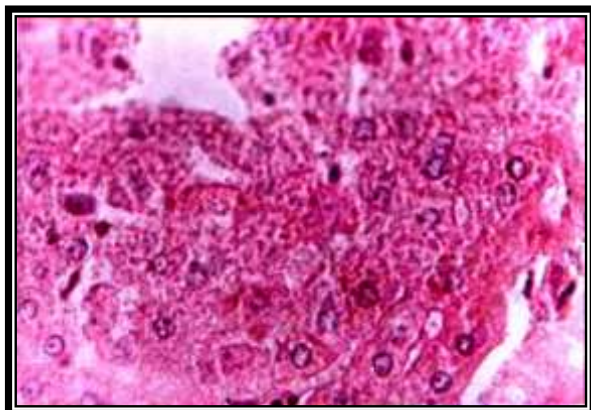


Figure 1 : cross section in rat liver (T1) observe necrosis. H& E X 40

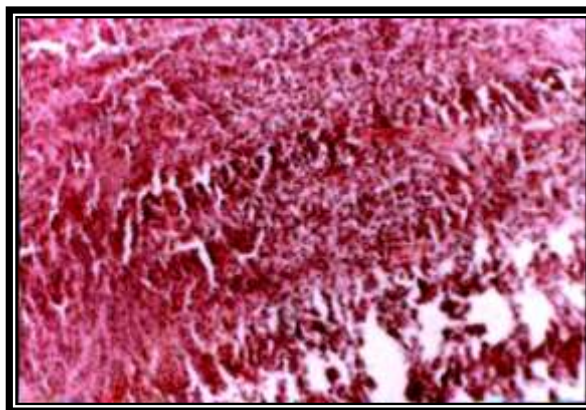


Figure 2 : cross section in rat lung (T1) observed hyperplasia. H&E X40

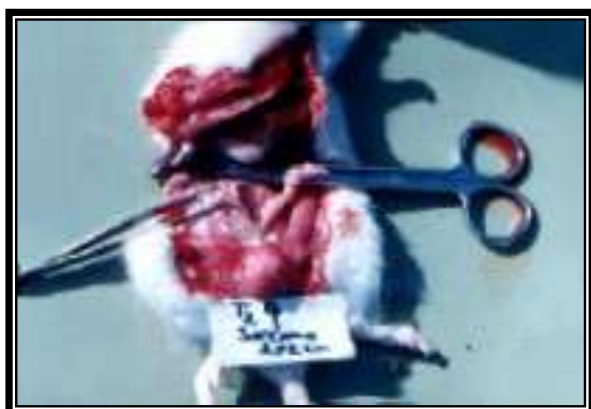

Figure 3 : Abdominal sub coetaneous fibroma in rat (T2)

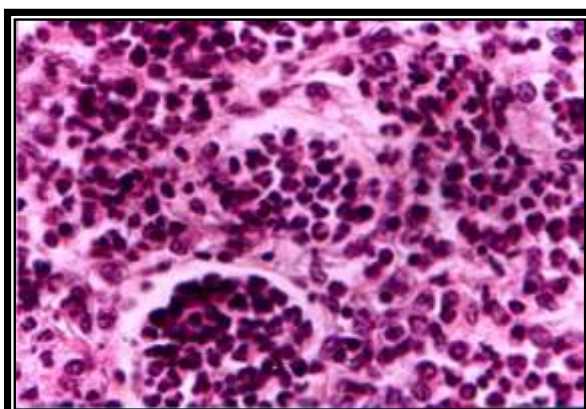


Figure 4 : cross section of fibroma in rat (T2) H&EX40

Discussion

The present results of organs weight showed that liver and ovaries weights of group T1 & T3 were more than group T2 & C this may be due to the large dose of vitamin A taken by group T1 according to the period of dosing (19 days) while in group T3 the effect may be due to functional; & histological changes that occur in fetuses at this stage of pregnancy as a result of hypervitaminosis A (6,7). also the physiological changes in mother specially in this advance stage of pregnancy may lead to hormonal imbalance in highly perfuse organ (liver) as well as reproductive organ (ovaries) (8). The uterus weight of groups T1&T2 were smaller than T3 & C may be as consequence of failure in fullterm embryonic development with high rate of fetal resorbtion & low number of neonates that observed by us in previous study (9). While groups T3 & C showed nearly complete full term embryonic development without any resorbed fetuses which may cause increasing the thickness of uterine muscle & blood supply for normal fetal growth (10).

The histopathological changes in liver (congestion and necrosis) are in agreement with AL-Obiadi (7) who founded blood vessels congestion and liver cell necrosis due to vitamin A overdosage in chicken with an increase of GOT and GPT levels (11) (12). Other study also revealed same hepatocyte necrotic changes due to 8000 IU vitamin A dosing in rat (6). The lung hyperplasia may be due to increase in epidermal growth factor of lung cells, fibroblast and interleukin-2 in activated glands due to vitamin A analogue (retinoic acid) over dosage in infants (13, 14). Dolle (15) found that the binding of retinoic acid into intracellular receptors leads to suppress the Hox Genes, G hox gene -8 and m RNA b2 which may causes apoptosis and explain the necrosis in lung and other tissues.

Several studies revealed the ability of natural and synthetic retinods (Vit.A.) in decreasing carcinogenicity (2) . but Omenn (16) indicated that the serum level of beta ,carotene (precursor of vitamin A under certain condition such as smokers suffering from lung carcinoma produce failure of A-Tocopherol- Beta carotene cancer prevention. A pseudo tumor cerebri registered in fourteen years adolescent after three weeks treatment by synthetic retinods and tetracycline (17) and in woman of twenty years age was consuming diets contain (4000-40000 IU) of vitamin A for two years (18). The high dose of vitamin A (10000 IU) during embryonic organogenesis in pregnant rat revealed chromosomal aberration. (Clastogenesis) (9) . Which may lead to mutation in genetic material and may explain the histopathlogical changes in organs and tissues and development of cancer (fibroma).

References

1. Harber , H.A.(1975). Review of physiological chemistry ;15th Ed.Middle East Ed. Ptinted in Lebanon .
2. Donald, S. ; McLaren , M.D. and Martin, F.(2001).Sight and life manual on vitamin A deficiency disorders.
3. Cameron, C and Angela,C.(1998).Hypervitaminosis, Emergency toxicity 2nd Ed. PP 607-624. Edited by Peter Viellio; Lippon,Raven Publishers Philadeliphia .
4. Casarett and Doull's (1986). Toxicology , the basic science of poisons3rdEd.: Macmillan (Ed)Publishing company New York.
5. Hafez, E.S.E.(1970). Reproduction and breeding techniques for laboratory animals . Lea and Febiger, Philadelphia .
6. Shuntaka.T, Murata.T,Yamaguch.K and Makita,T, (1998). Hepatic histopathology of vit.A over dose in mouse liver, J. of electron microscop, Tokyo, 47: 3,263-7.
7. AL-Obiadi, R.AH, M.J. (2003).Toxic and teratologic effects of hyper vitaminosis-A on the chicks embryo and hatched chicks resulted from

- broiler mother. MS thesis. College of Vet. Medicine, University of Baghdad.
8. Maknen, R.T. and Stener, B.R. (2002). Principle of Gynecology and Obstetric : PP.20-34 Philadelphia , Mexico
 9. AL-Rekabi ;F.M.K.(2002). The teratogenic and cytogenic effects of high dose of vitamin A upon the pregnant rats .MS. thesis . College of of Vet Medicine, University of Baghdad.
 10. Jame; E.R. (1971).The femal reproductive system.In: Text book of Veterinary Physiology Ed. James, E, Beriazile, C; G; Beames ,P ;T; Cordielhac and W; C; New comer. PP: 524-533. LEA& FEBIGER. Philadiliphia.
 11. Farrell, G.C; Bathal,P.S; Powell, L.W; (1977). Abnormal liver function in chronic hyper vitaminosis A , Diag. Dis., Sci,22,724-800.
 12. Russel, R.M; Boyer, J.L; Bagheri, S.A; (1974). Hepatic injury from chronic hyper vitaminosis A resulting in portal hypertension and ascites, N.Eng.J.Med;291:435-40.
 13. Oberg , K.; Saderquist, A.M. and Carpente ,G.(1988).Accumulation of epidermal growth facteor receptors in retinoicacid- treated fetal rat lung cell is due to enhanced receptor synthesis. Mol.Endorinal.2:959-65.
 14. Petkovich, M.; Brand, N.I.; Krust,A.; chambon,P.A. (1987a) Human retinoic acid receptor. Nature.330:444-50.
 15. Dolle, P.; Rubert,E.; Kastner, P. (1989). Difffferential experssion of the genes encoding the retinoic acid receptors,a,b,G, and C R A B P in developing limbs of the mouse Nature: 342: 702 .
 16. Omenn, G.S. ; Guodman, F.E.; Thomquist, M.D. (1986). Risk factor for lung cancer and for intervention effects in CARET ,the beta arotene and retinol effecting trial. J.Natl. cancer. inst 88 : 1550-59.
 17. Lee, A . (1995). Pseudo tumor cerebri after treatment with tetracycline and isotretinion for acne cutis. 55: 156-168.
 18. Medeioros, D.M. (1991). Long term Supplement users and dosage among adult Westerness .J.AM. Diet.Assoc.91 (8):980.