

Study the pathological and Residual Toxic effect of Malathion in Mice Nervous System

Soad Abdulkareem Mohammed

Dept. of Pathology and Poultry diseases-college of Vet.Med.- Baghdad
University – Baghdad - Iraq

Summary

In present experiment , study was done on the pathological and residual effect of malathion in mice 50 white mice randomly divided into 3 group : 1st group including (20)mice was given single oral dose .1.5 ppm in drinking water 2nd group contain (20) mice given single dose 1.5 ppm malathion orally in drinking water and repeated the same dose at 2nd and 3rd week i.e (three repeated doses), the 3rd group (10) mice act as control group .The long of experiment was 60 days , the following parameter were done .

- 1- Clinical Signs: treated group 1st and 2nd groups showed nausea and diarrhea
- 2- Pathological changes : 1st and 2nd group showed lesion which were more significant in 2nd group .Pathological changes characterized by neuron necrosis , Brain odema , and mononuclear cell present with spinal cord damage .
- 3- Residual investigation: which were more significant in 2nd group at 60 days of treatment, the Malathion residual reach 0.90 ppm in brain and spinal cord.

دراسة التأثير السمي لمبيد الملاثيون ومتبقياته في الجهاز العصبي للفئران

سعاد عبد الكريم محمد

فرع الامراض والدواجن - كلية الطب البيطري - جامعة بغداد - بغداد - العراق

الخلاصة

اجريت الدراسة الحالية لتحديد التأثير السمي المرضي لمبيد الملاثيون ومتبقياته في الفئران 50 فأراً أبيض اللون ، قسم عشوائياً الى ثلاثة مجاميع : المجموعة الاولى 20 فأراً أعطيت 1.5 ppm من مبيد الملاثيون عن طريق ماء الشرب ، اما المجموعة الثانية 20 فأراً فقد اعطيت 1.5 ppm مبيد الملاثيون عن طريق ماء الشرب في الاسبوع الاول والثاني والثالث من التجربة (اي ثلاث جرع متتالية) ، المجموعة الثالثة 10 فئران تركت كسيطرة ، درست خلال مدة التجربة 60 يوماً المعايير الاتية :

- 1- الاعراض السريرية
- 2- التغييرات المرضية في الجهاز العصبي (الدماغ ، النخاع الشوكي) في نهاية التجربة ، حيث لوحظ النخر والاوديما في الدماغ وكانت الافات اكثر شدة في المجموعة الثانية مع تلف وتحطم النخاع الشوكي .
- 3- تحديد متبقيات الملاثيون في الجهاز العصبي حيث كانت اعلى مستوياتها 0.90 ppm في المجموعة الثانية في المدة 60 يوماً .

Introduction

Malathion is organophosphorous pesticides which cause an irreversible inhibition of acetyl cholinesterase (1).

Malathion can actually breakdown into compound which are more poisonous than the malathion itself(2).it was found that repeated exposure to lower doses can insidious cumulative toxicity (3).

The toxicity of malathion due to it's oxidation to malaaxon which is 1000 times more active than malathion and act as an anti cholinesterase (4).

It had been found that the malathion in highest concentration in adipose tissue(7.6ppm),in kidney (106 ppm)nerve cord and brain after topical application in mice (5).Malathion cause neuron damage characterized by necrosis , odema and vacculation of neurons(7).

The oral LD₅₀ value for mice range from 0.8-4.5 ppm (10)showed clinical poisoning in injected mice with malathion mostly muscular weakness , salivation and coma , its found that malathion is neurotoxic action may be cause prostration and death(6).

Materials and Methods

Animal groups: 50 white male mice were used weighting (150-175 gm) : randomly were divided into 3 groups : The 1st group contain (20) mice were given a single oral dose of 1.5 ppm malathion in drinking water , the 2nd group(20) mice was given 1.5 ppm malathion in drinking water at 1st , 2nd and 3rd weeks i.e. three repeated doses , the 3rd group (10 mice) were used as control group.

Results

- 1. Clinical Signs** :- treated mice 1st and 2nd groups showed during experimental period symptoms of poisoning include loss of appetite , nausea and diarrhea and its very strong in 2nd group , (9) found oral LD₅₀ value for mice rang from (0.8 – 4.5 ppm) .(10) showed clinical poisoning in injected mice with Malathion mostly muscular weakness , salivation and Coma .and death (6)
- 2. Residual investigation** :- table (1) showed Malathion residues in brain and spinal cord tissue at 30 and 60 days after treated mice .

Days	1 st group	2 nd group	Control
30	0.02 ppm	0.05 ppm	0
60	0.01 ppm	0.90 ppm	0

In 2nd group the residue is highest at 60 of treatment than 30 days and than the 1st group . the never cord and brain contained the greatest concentration of Malathion .

- 3. Pathological changes** :- The brain and spinal cord of 1st and 2nd group showed at the end of experiment pathological changes which were move significant in 2nd group the brain neuron vasculated and Pyknotic , some

neurons suffer from necrosis figure (1) cuffing lymphocyte presented a round blood vessels figure (2) . Clotted of blood vessels and brain odema lymphocytes and mononuclear cells present in spinal cord with areas of necrosis and mostly damage of spinal cord figure (3) .

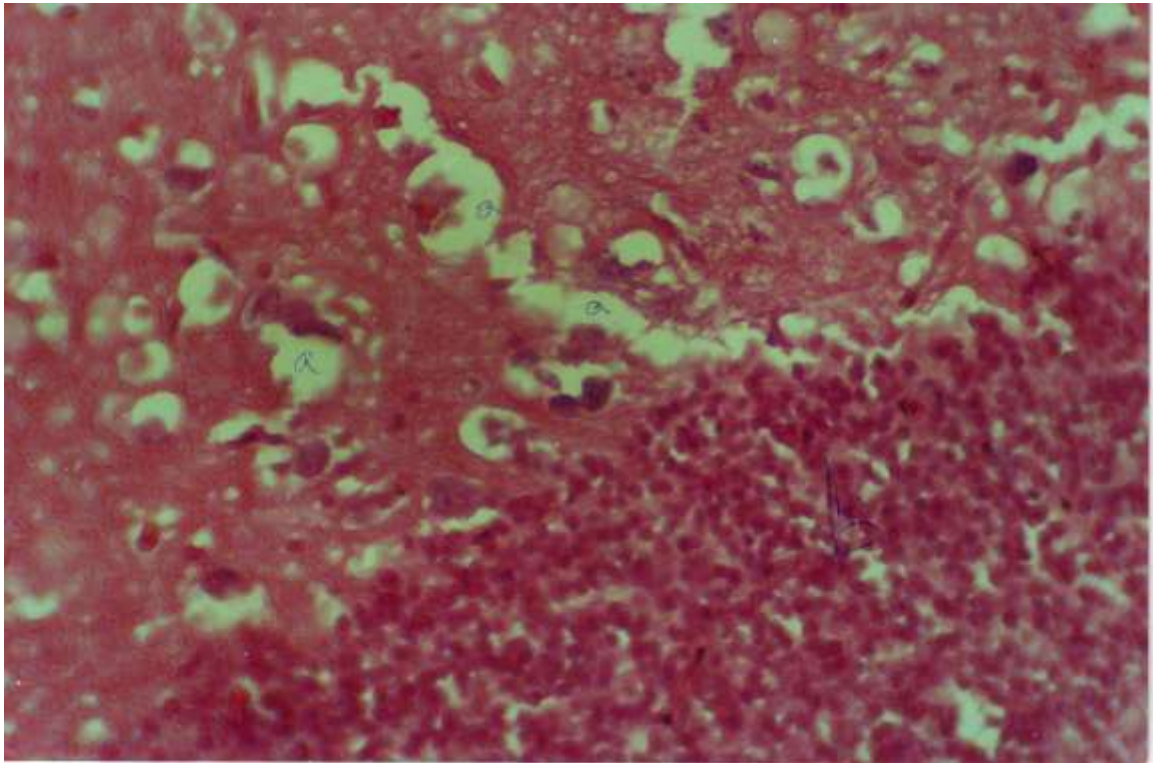


Figure (1):Brain of Mice , 2nd group see:(a) Neuron necrosis (b) Cuffing lymphocytes (X40 H& E stain)

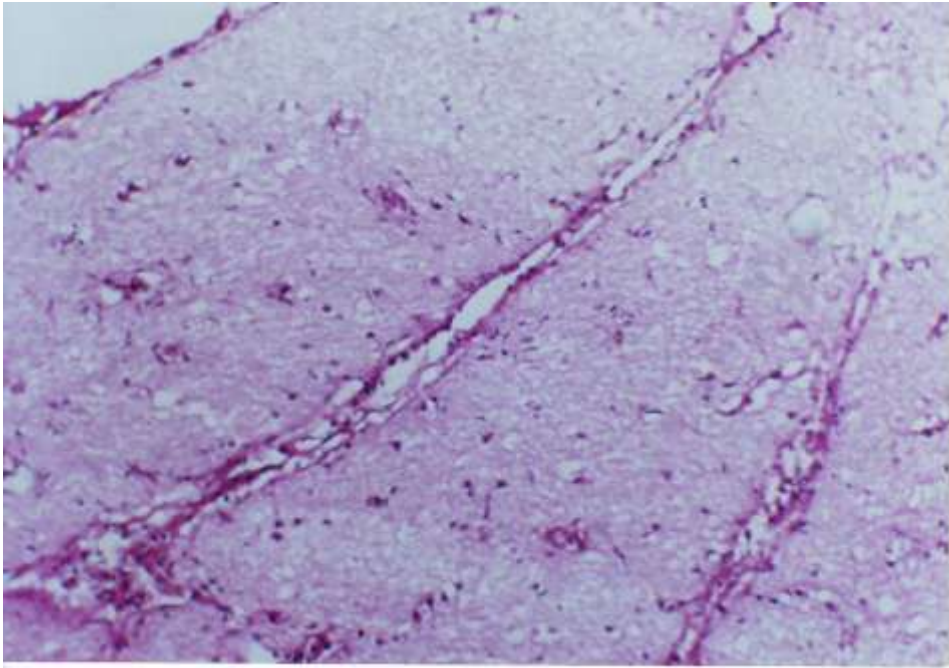


Figure (2):Brain of Mice , 1st group see:(a) Brain odema (X20 : H& E stain)

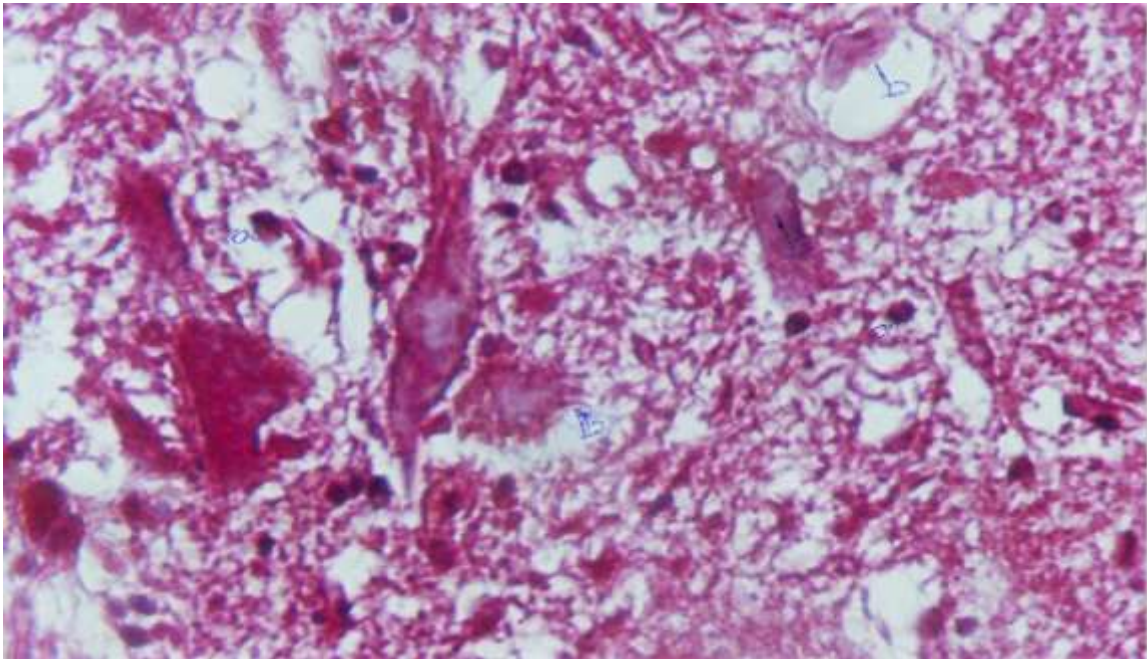


Figure (3):Brain of Mice , 2nd group see:(a) Monouclear cell in spinal cord and (b) Necrosis (X 40 H& E stain)

Discussion

The present of greatest concentration of malathion in never cord and brain is due to accumulative of malathion about 18% of (14) . C. malathion label partitioned in to the tissuo aqueous phase up to 24 hrs after topical application (6) .The clinical signs of poisoning which occur in injected mice with malathion due to neurotoxic action of malathion which cause prostration and death (6) .

Malathion is cholinesterase inhibitor pesticides which allows to depression of cells necrosis (11). So the pathological changes in 2nd group indicated that malathion residues in never tissue have danger effect than single dose.

REFERENCES

1. Murty, A.S.(1986).toxicity of pesticides to fish, 1:V191 Bocarotan.
2. Hayes, W.J.; Laws, J.R; Jr, E.R. (1991). Handbook of Pesticides toxocology. 2classes of pesticides .New York, NY; Academic Press, Inc.
3. Driesbach, R.H. (1987) handbook of poisoning, 12th ed. Norwalk, Ct Appleton and Lange.
4. Park, D.V.(1968).the biochemistry of foreign compound Oxford: Pergamon ,Press:P204
5. Morgade ,C.and barguest a.(1982)Toxicol Environ health .,10 (2) :321-5
6. Dales, M. J (1989).Boch. physiol. parmacol toxicol .,92(1):155-162.
7. Limbird P.B.(2000)Pathological and pharmacological basis of malthion clinical toxicology.9th ed:120-132.
8. Humanson,G.(1967).Animal tissue techniques 596.2nd ed. Sanfranciscow W.H Freeman.
9. Goyer, H.D.; Wilson R.A.; Goyer R.(1998).toxic sings of organophosphorous pesticides .arch.pathol.,90:205-219.
- 10.Fukuto,D.L.(1995).Action and metabolism of malathion Arch. Environ Health.,30:292-302.
- 11.Smith,R.P and Limbird G.c.(2001).malathion after prolonged toxicity .
- 12.Murty, A.S.(1986).toxicity of pesticides to fish, 1:V191 Bocarotan.
- 13.Hayes, W.J.; Laws, J.R; Jr, E.R. (1991). Handbook of Pesticides toxocology. 2classes of pesticides .New York, NY; Academic Press, Inc.
- 14.Driesbach, R.H. (1987) handbook of poisoning, 12th ed. Norwalk, Ct Appleton and Lange.
- 15.Park, D.V.(1968).the biochemistry of foreign compound Oxford: Pergamon ,Press:P204
- 16.Morgade ,C.and barguest a.(1982)Toxicol Environ health .,10 (2) :321-5
- 17.Dales, M. J (1989).Boch. physiol. parmacol toxicol .,92(1):155-162.
- 18.Limbird P.B.(2000)Pathological and pharmacological basis of malthion clinical toxicology.9th ed:120-132.

19. Humanson, G. (1967). Animal tissue techniques 596. 2nd ed. San Francisco W.H Freeman.
20. Goyer, H.D.; Wilson R.A.; Goyer R. (1998). Toxic signs of organophosphorous pesticides. Arch. Pathol., 90:205-219.
21. Fukuto, D.L. (1995). Action and metabolism of malathion Arch. Environ Health., 30:292-302.
22. Smith, R.P and Limbird G.C. (2001). Malathion after prolonged toxicity .