

Gossypol Effect in Some blood parameters, enzymes and pathology of male common carp *Cyprinus carpio L.*

Omar B.A. Al-Tayyar

, Muhannad A. Al-Beati

And Sana A. Al-Ubade

Dept. of Pathology and Poultry Dis. College of Vet. Med

**, *

*College of Vet. Med. University of Baghdad ** University of Baghdad Dept. of Pharma. And Physiology

Summary

Gossypol is a substance found in the cottonseed. Recently in Iraq and in other countries the cottonseed was used as a concentrate for fish and other animals without awareness of the risk. The present study is designed to shed the light on the deleterious effect of gossypol on some hematological parameters and enzymes of male common carp *Cyprinus carpio L.* Oral administration of gossypol 20 mg./kg. b.w. for ten days was found to be a strong lyses for red blood cell, reduced packed cell volume and increased erythrocyte sedimentation rate and decreased total white blood cell. Furthermore alkaline phosphatase, alinine aminotransferase and aspartate aminotransferase were increased which reflect liver and kidneys damage caused by gossypol coincided with the histopathological changes in which there was mainly degeneration as well as inflammatory cells infiltration.

تأثير الكوسيبول (gossypol) في بعض قياسات الدم والانزيمات والامراضية لذكور الكارب الشائع *Cyprinus carpio L.*

عمر باسم احمد الطيار* ، مهند عبد الستار البياتي** ، سناء عبد العزيز العبيدي*

*فرع الامراض و امراض الدواجن ، كلية الطب البيطري ، جامعة بغداد

** فرع الادوية و الفسلجة ، كلية الطب البيطري ، جامعة بغداد

الخلاصة

توجد مادة الكوسيبول في بذور القطن. استعملت حديثا في العراق و في بلدان اخرى بذور القطن في عليقة الاسماك و الحيوانات الاخرى من غير الحذر من اثاره . صممت الدراسة الحالية لتسليط الضوء على الاثار السالبة للكوسيبول في بعض قياسات الدم و الانزيمات لذكور الكارب الشائع . اعطاء الكوسيبول من خلال الفم بجرعة ٢٠ ملغم/كيلو غرام من وزن الجسم لمدة عشرة ايام وجد انه محلل قوي لخلايا الدم الحمر و اختزل حجم الخلايا المرصوص و زاد من معدل تثقل خلايا الدم الحمر و قلل من العدد الكلي لخلايا الدم البيض. فضلا عن انه زاد من Alkaline phosphatase و Alinine aminotransferase و Aspartate aminotransferase الذي يدل على الاذى الذي سببه الكوسيبول في الكبد و الكلى و الذي يتوافق مع التغيرات المرضية النسيجية التي تمثلت بصورة رئيسة بالتتكس فضلا عن ارتشاح الخلايا الالتهابية.

Introduction

Numerous investigations have been established the high nutritive value of cottonseed (CS), fed to livestock as a valuable source of protein and oil. It is used primarily in ruminant diets because of their partially tolerance for gossypol (1), (2).

Notions in literature pointed out that the oil and the meal have some effects on the male reproductive system (3). (4) reported that the extensive use of crude CS oil in cooking caused decreased in fertility, this is caused by a phenolic pigment "Gossypol" (5) . Gossypol is a lipid soluble, polyphenolic yellowish pigment, which is in the intact seed (6). Gossypol (C₃₀H₃₀O₈) is located within the pigment or oil glands in the cotton plant. In CS these glands appear as brown to black specks within the white matrix of the seed. The content of gossypol in whole CS ranges from 0.2% to 6.64% and is thought to provide resistance to insects (7).

Some notions in literature indicate that gossypol has some effect on erythropoietic system (8). (9) reported that Gossypol has a hemolytic effect on erythrocytes. Further studies reported that this deleterious action in erythroid system is caused by the direct effect of gossypol on blood cells forming organs (10). (11), (1) reported that CS caused growth and feed conversion retardation in fish.

Recently in Iraq and other countries CS were used as a concentrate in fish diets without restriction and without awareness of its risk. Since the CS contain gossypol which may be affect human indirectly through consumption of fish meat which contain residue of gossypol or its metabolites (12) .

This study is designed to shed the light on some deleterious effect of gossypol on the blood picture and function of other body organs at short term of treatment by using of 20 mg. /kg. b.w. of gossypol to investigate the above mention biological disruption in fish .

Material and method

Twenty colony, common carp male fish, were used in this experiment at three month of age with total body length ranged between 18 to 24 cm. and body weight ranged between 220 to 260 gm., the male fish were divided into two equal groups, each group placed in two tanks (160×60×45) cm. with a capacity of (430) liters supplemented with tap water and oxygenated artificially, water temperature was 22 ± 2 °C, fish were fed fish pellets. The first group served as a control and the second group as gossypol treatment group. Fishes were adapted for one week in the laboratory of pathology\Baghdad veterinary college.

The duration of treatment was ten days (short term of treatment). Gossypol (gossypol acetic acid prepared according to Campbell method (13) mixed with gossypol free CS oil prepared by Dr. Muhannad during his PhD study) was given orally by plastic stomach tube at a dose of 1ml. (20 mg./kg. b.w.), control group was given 1ml. distilled water orally.

Blood collection was made in each group after ten days of treatment from the caudal tail blood vessels using a 2 ml. sterile plastic syringe (21 G. needle) transferred to heparinized tube and mixed well.

Blood cell count was done by using Neubauer counting chamber diluted by Dacie's fluid, packed cell volume measured by drawn the blood into hematocrit tube and performed according to (14).

Hemoglobin value and erythrocyte sedimentation rate were done according to (14). Differential white blood cell count was made by staining the blood film with Write-Gimza stain, scoring and assessment of the cell was done according to (15).

Blood serum was isolated to determine alkaline phosphatase (ALP), alanine aminotransferase (ALT), and aspartate aminotransferase (AST) and performed according to (16). After sacrifice of fish the liver, spleen, kidneys and skeletal muscle had been excised and immersed in 10% neutral buffered formalin histological architecture of these tissues was studied by staining with eosin hematoxylin stain. Statistical analysis was done by using one-way analysis of variance (17).

Results

Results of the effect of gossypol on a concentration of (20 mg./kg. b.w.) in some blood parameters are shown in table (1). Hemoglobin value, red blood cell count, packed cell volume in treatment group were significantly decreased ($p < 0.05$) after ten days as compared with control group. A significant increase ($p < 0.05$) in ESR. between the treatment and control group was recorded.

The total white blood cell, lymphocytes and neutrophils in treatment group were significantly decreased ($p < 0.05$) after ten days as compared with control group.

Table (1): Gossypol effect in blood parameters of male common carp

	Control group	Treatment group
Hb g./dl.	8.76 ± 1.037	6.54 ± 1.650 a
RBC. 10	1.061 ± 0.291	0.805 ± 0.211 a
PCV %	21.80 ± 2.94	18.61 ± 3.36 a
ESR. mm./hr.	2.20 ± 0.20	3.56 ± 0.45 a
TWBC.10 ³	6.40 ± 0.75	5.01 ± 0.99 a
Lymphocyte %	86.87 ± 9.50	68.90 ± 7.14 a
Neutrophil %	11.61 ± 1.60	8.15 ± 1.41 a

Letter a mean it is statistically different at $p < 0.05$ between row.

The results of serological test are shown in table (2). The activity of ALP, ALT and AST. increased in treatment group at the ten days of treatment .

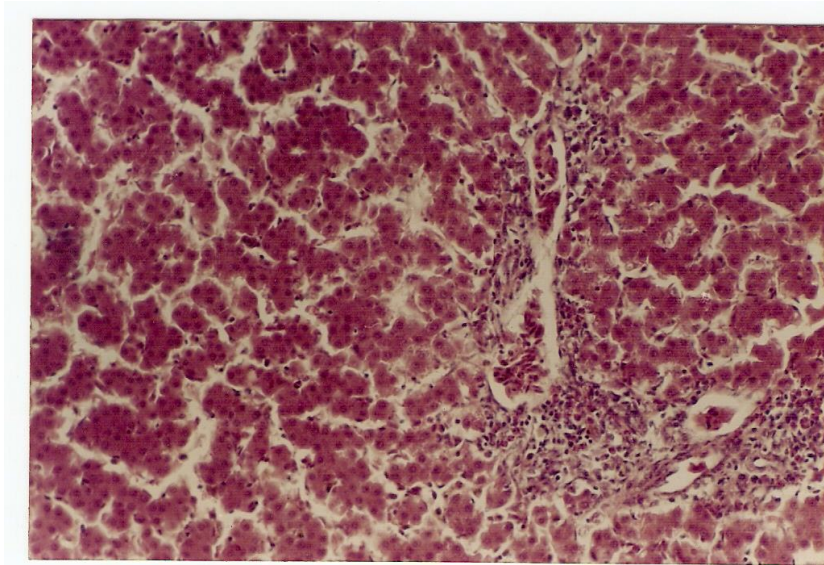
Table (2): Gossypol effect in some enzymes of male common carp

	Control	Treatment group
Alkaline phosphatase (ALP.)	26.6	31.4
Alanine aminotransferase (ALT)	5.81	12.71
Aspartate aminotransferase (AST.)	30.96	37.33

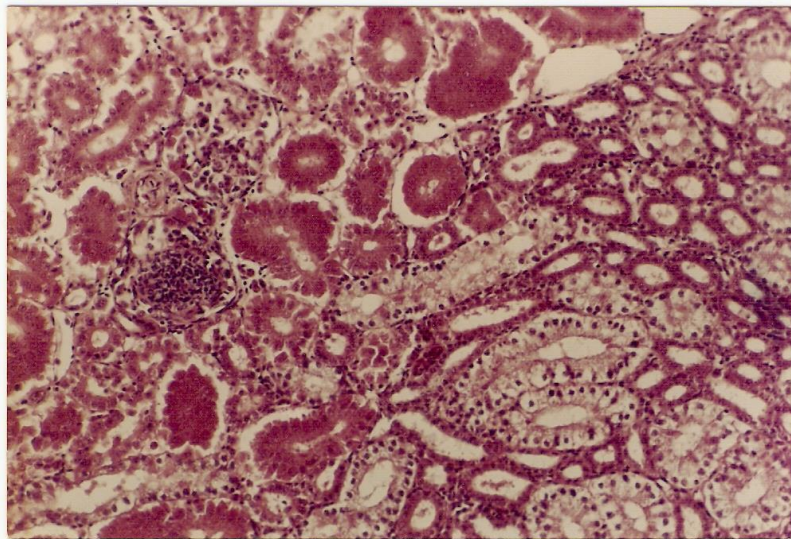
The total body weight in treatment group decreased ($p \leq 0.05$) after ten days from 2460 gm. to 1940 gm. while there was little change in the body weight of the control group from 2330 gm. to 2390 gm. .

The major histopathological findings were general findings like degeneration, edema, and inflammatory cells infiltration of the studied tissues liver, kidneys and spleen where as in muscle there

were slight pathological changes. Cloudy swelling and cell degeneration in several point of tissue architecture in liver (picture 1) and in kidney (picture 2) with increase in the thickening of the glomerular basement membrane in kidney.

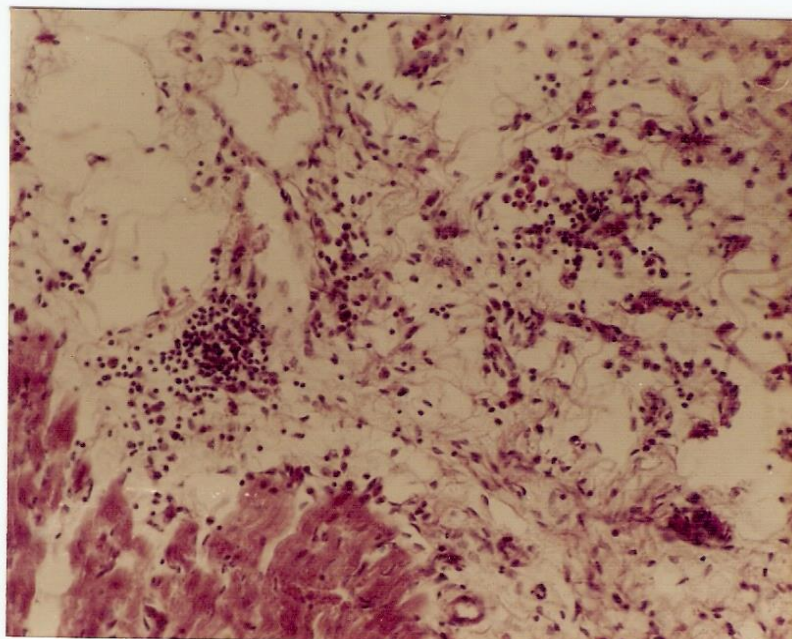


Picture (1): liver tissue showing cells degeneration and inflammatory cells infiltration (macrophages and lymphocytes) 100x.



Picture (2): kidney tissue showing cells degeneration and slight inflammatory cells infiltration (macrophages and lymphocytes) and slight congestion 100x.

An interesting observation was that the testes weight decreased by about 30% in the treatment group as compared with the control group.



Picture (3): skeletal muscle tissue showing inflammatory cells infiltration (neutrophils and lymphocytes) and slight degeneration 100x.

Discussion

Hematological picture showed that the red blood cell count after gossypol treatment (20) mg./kg. b.w. for short term (10) days was decreased in count as compared with control group. This result is in agreement with (12), (18) and (8) in rainbow trout, channel cat fish and rat respectively who attributed the reduction in red blood cell count to alteration in the structural function and integrity of cell membrane by direct binding of gossypol in red blood cell membrane. (19) found that gossypol binding may be led to loss of fluidity and elasticity of membrane and facilitate the cell destruction through increase membrane fragility. (20) attributed increases membrane fragility to direct alteration in the chemical structure of red blood cell membrane. (21) attributed the reduction of red blood cell count to impairment of hemopoietic system; kidney, liver and spleen. The basis for this effect may be attributed to primary deleterious effect of gossypol to structural and functional properties of liver and kidney.

Hemoglobin levels result showed a significant decrease in concentration of hemoglobin in treatment group as compared with control group (table 1). This result is in agreement with the result of (22) where fishmeal proteins were gradually replaced with cottonseed meal (CSM) proteins at 100% and (23) where fish fed 25–100% CSM protein replacement and (8) who attributed this reduction of hemoglobin level to liver dysfunction and animal health retardation. Where as (12) attributed the hemoglobin level reduction to erythrocyte hemolysis and extensive oxygenation of hemoglobin through the impairment of oxyhemoglobin transferred to unsaturated hemoglobin. It is may be presumably associated with enhancement of losing the structural and biological activity of hemoglobin and globin deformity through the ability of gossypol as proton donor and facilitate the hemoglobin degradation which then reduce hemoglobin concentration (24). Where as (25) attributed the reduction of hemoglobin to decrease plasma iron level through chelating effect of gossypol to iron and prevented its association in hemoglobin formation. The result of this study disagree with (26) where three basal diets containing 0%, 27.5% and 55.0% solvent-extracted CSM as replacements of 0%, 50% and 100% of solvent-extracted soybean meal on an equal nitrogen basis were each supplemented with three levels of iron (40, 336 and 671 mg/kg) from ferrous sulfate heptahydrate (3×3 factorial experiment). Each diet was fed to juvenile channel catfish hematocrit and hemoglobin were not affected by dietary levels of CSM.

Packed cell volume reflects the relative percentage of number and size of red blood cell to the volume of blood plasma and total volume of blood. The result of our research showed a decrease in packed cell volume in treatment group as compared with control group this result is in agreement with (27) who attributed this effect to decrease of red blood cell formation through decrease formation and increase cell lysis and then increase plasma protein level.

Total white blood cell and differential white blood cell percent reflects functionally to the body immune system and closely related to humeral and cellular immunity (28). The result of this study showed a decrease in total white blood cell, lymphocyte and neutrophil. The reduction of total white

blood cell may be due to the damaged caused to blood forming organs (kidney, liver and spleen in fish) which are responsible for white blood cell formation. (23) reported lymphocytic depletion of the white pulp areas in the spleen of tilapia which were observed among fish fed 50–100% CSM protein diets. (9) attributed this white blood cell picture to an inhibition of the activity of adenylate cyclase -c- AMP which delay the immune response. Where as (29) and (30) attributed the reduction of white blood cell and their fractions to reduction in arachidonic acid derived product through inhibition of lipooxygenase enzyme this may be presumably associated with impairment in chemotacting releasing factor. (26) found that agglutinating antibody titers were significantly higher for juvenile channel catfish fed diets containing CSM, but the values did not differ for those fed the 27.5% or 55.0% CSM diets and that no differences were observed among mortality of fish fed the CSM-containing diets at 15 days post-challenge with *Edwardsiella ictaluri*.

Our histopathological result of liver exhibited cloudy swelling of hepatocytes and sinusoidal infiltration with lymphocytes and neutrophils, where as kidney picture showed interstitial nephritis and diffuses lymphocytes infiltration. Furthermore our result of serological test indicated an increase in ALP, ALT, and AST as a markable enzymes of damaged liver and kidney tissues, this result is coincided with the disruption of histological architecture. This result is in agreement with the result of (8) who attributed this result to increase in glycogen enrichment and impairment liver detoxification. Where as (24) and (30) attributed this histopathological picture to inhibition of Na-K pump through inhibition ATPase enzyme and blocking of volume-sensitive permeable channel in kidney tubules by gossypol; i.e. play an important role in osmolarity balance of cells. (31) attributed this histopathological picture to reduction of c-AMP. due to impairment of adenylate cyclase though gossypol is a competitive inhibitor of ATP, and stated that gossypol is a general inhibitor of nucleotide metabolizing enzyme. (32) attributed this injurious effect to the ability of gossypol to promote the formation of free radicals and as a proton carrier in biological membranes. (33) and (34) who attributed the ability of gossypol to induce DNA breakage and inhibition DNA synthesis at high exposure of gossypol.

Fish in treatment group showed growth reduction after ten days of treatment. This result is in agreement with (1) who reported that growth suppression occurred in rainbow trout fed diets containing 290 ppm. or more free gossypol, whereas *Tilapia aurea* could not tolerate gossypol and growth reduction occurred at any level, and with (26), (23) and (35) in which there was significant decline in b.w. of channel catfish, tilapia, and juvenile rainbow trout after total replacement of protein meal with CSM. While (12) and (36) reported no adverse effect on the growth of rainbow trout fed gossypol acetate at 0.025% (250 ppm.) nor by complete replacement of fish meal protein with CSM. Effects of gossypol in other fish species are unknown.

Finally this study displayed more pronounced deleterious effect of gossypol on hemopoietic system at short term of treatment. This fact may probably due to possible enhancement of gossypol absorption by oil, which was used in our experiment as a vehicle. This result is in one step with the result of (37) who attributed the increased in gossypol toxicity by about two to four times when administered in oil which may be increase the gossypol absorption and potentiate its toxicity.

If the commercial processing of cottonseed involves heating and moisture the glands will disrupt and cause conversion of much of the free gossypol (80-99%) to bound forms which are considered nontoxic to animals except the very sensitive (1).

References

- 1- Halver, J.E. (1989) Fish nutrition, 2nd edition. Academic press, Inc.
- 2-Chase, C.C. Jr.; Bastidas, P.; Ruttle, Jr.; Lony, C.R. and Randel, R.D.(1994) Growth and reproductive development in Brahman bulls fed diets containing gossypol. J. Anim. Sci. 40, 647-663.
- 3- Zelski, R.Z.; Rothwell, J.T.; Moore, R.E. and Kennedy, D.J. (1995) Gossypol toxicity in preruminant calves. Aust. Vet. J. 72, 10; 394-398.
- 4- National coordination group on male antifertility agents of China (1978) Gossypol- A new antifertility agent for males. Chinese med. J. 4(6): 417-428.
- 5- Kim, H.L.; Calhon, M.C. and Stipanovic, R.D. (1996) Accumulation of gossypol enantiomers in ovine tissues. Comp. Biochem Physiol. B. Biochem. Mol. Boil. 113(2): 417-420.
- 6- Zheng, D.K.; Meng, J.K.; Si, Y.K.; Ma, S.Y. and Huang, L. (1990) Studies on the resolution of racemic gossypol, IV of threo (-) or (+) α -1-*p*-nitrophenyl-1, 3-dihydroxy propylamine₂ as the resolving agent. Yao, Hsueh, Pao. 25, 6; 430-434.
- 7- Steven S. Nicholson (2007) Veterinary Toxicology Basic and Clinical Principles. Elsevier B.V.
- 8- Akingbemi, R.; Rose. S. and Rang M. (1995) Gossypol (review). Biochem. Techn. 71 : 12.
- 9- Nwoha, P.U. (1995) The blood constituents of gossypol treated protein-malnourished Wister rats. Contraception 52 (4) : 249-254.

- 10- Lanfang, D.; Suran K.; Rittman H. and Robinson G. (1980) e effect of gossypol on hemopoitic and hemodynamic activity. *Lancet* 66: 5-11.
- 11- Warrren, j; Robinette, H.R. and Robinson, G. (1982) Effects of dietary cottonseed meal and gossypol on growth of young channel catfish. *Trans. Am. Fish Soci.* 111: 655.
- 12- Roehm, J; La, D. and Sinnhuber, R. (1967) Accumulation and elimination of dietary gossypol in the organs of rainbow trout. *Nutrition* 92; 425.
- 13- Campbel, K.N.; Morris, R.C. and Adams, R. (1937) The structure of gossypol. *J. Am. Chem. Soc.* 59, 1723-1728.
- 14- Blaxhall, V.S. and Daisley, K.W. (1973) routine hematological methods for use with fish blood. *J. Fish. Bio.* 5; 771-781.
- 15- Hayhoe, F.G.J.; Quaglins, D. and Doll, R. (1964) The cytology and the cytochemistry of acute leukaemias. *Spec. Rep. ser. Med. Res.* No 304.
- 16- Wootton, I. D. P. (1964) *Microanalysis in medical biochemistry.* J. and A. Churchill Ltd. 104 Gloucester phase London W.I.
- 17- Steel, R.G.D. and Torrie, J.H. (1980) *Principles and procedures of statistics. A biometricallab roach* (2nd edition).
- 18- Yildirim, M.; Lim, C.E.; Wan, P.J. and Klesius, P.H. (2002) Growth performance and immune response of channel catfish (*Ictalurus punctatus*) fed diets containing graded levels of gossypol acetate. *Proceedings of Fish Nutrition and Feeding Symposium Proceedings.* p. 162.
- 19- Reyes, J.; Allen, J.; Tanphaichitr, N.; Bellue, A.R.; Benos, D.J. (1984) Molecular mechanisms of gossypol action on lipid membranes. *J. Boil. Chem.* 259 : 15 , 9607- 9615 .
- 20- Myong, K.V.K.S. and John Bland, M (2001) pH effect on gossypol complex with phospholipids: gossypol phosphotidylethanolamine. *Teckran United States Department of Agriculture. Agricultural Research Service.*
- 21- Haipeng, J.S.; Bernard, M. and Hall, R. (1980) The main alteration in biochemical and hematological picture after injury of hematopoitic organs. *National Academy.* 38.7:11.
- 22- Rinchar, J. K.; Lee, J.; Dabrowski, K.; Ciereszko, A.; Blom, J.H. and Ottobre, J.S. (2003) Influence of gossypol from dietary cottonseed meal on haematology, reproductive steroids and tissue gossypol enantiomer concentrations in male rainbow trout (*Oncorhynchus mykiss*). *Aquaculture Nutrition* 9 (4), 275–282.
- 23- Garcia-Abiado, M. A.; Mbahinzireki, G.; Rinchar, J.; Lee, K. and Dabrowski, K. (2004) Effect of diets containing gossypol on blood parameters and spleen structure in tilapia, *Oreochromis sp.*, reared in a recirculating system. *Journal of Fish Diseases* 27 (6) , 359–368.
- 24- Yun-Fung, X. (1987) Annotation of sperm osmolarity balance. *Federation Process.* 47.2:9.
- 25- Nwoha, P.U. and Air, T.A. (1995a) the effect of gossypol and chloroquine interaction on serum electrolytes of protein-malnourished rats. *Contraception* 52 (4) : 255-259.
- 26- Barros, M.; Limand, C. and Klesius, P.H. (2002) Effect of soybean meal replacement by cottonseed meal and iron supplementation on growth, immune response and resistance of Channel Catfish (*Ictalurus punctatus*) to *Edwardsiella ictaluri* challenge. *Aquaculture* 207 (3-4): 263-279.
- 27- East, N.E.; Anderson, M. and Lowenstine, L.J. (1994) Apparent gossypol induced toxicosis in adult dairy goats. *J. Am. Vet. Med. Assoc.* 15 : 204 (4) : 642-645.
- 28- Roitt, I.; Brostoff, J. and Male, D. (1998) *Immunology*, 5th edition. Mosby International.
- 29- Winkler, J.D.; McCarte, R.A.; Huang, L.; Sung, C.M.; Bolognese, B. and Marshall L.A. (1994) Biochemical and pharmacological comparison of acytosolie, high molecular weight phospholipase A2 , human synovial fluid phospholipase A2 and CoA-independent transacylase. *J. Lipid. Mediat. Cell. Signal.* 10, 3; 315-330.
- 30- Ballatori, N.; Truong, A.T.; Jackson, P.S.; Sarange, K. and Boyer, J.L. (1995) ATP depletion and inactivation of an ATP-sensitive taurine channel by classic-ion channel blockers. *Mol. Pharmacol.* 48(3): 472-47.
- 31- Oligiati , K.L.; Hoffer, A.P. and Toscano, Jr. W.A. (1984) gossypol modulation of nucleotide metabolizing enzymes in the reproductive tract of male rats. *Biol. Reprod.* 31, 759-770.
- 32- Peyster, A. Quitanilha, A.; Packer, L. and Smith, M.T. (1984) Oxygen radical formation induced by gossypol in rat liver microsomes and human sperm. *Biochem. Biophys. Res. Commun.* 118, 2, 573-579.
- 33- Srivestava, A.K. and Padmanaban G. (1987) Gossypol mediated DNA degradation. *Biochem. Biophys. Res. Commun.* 146, 3, 1515-1522.
- 34- Teng, C.S. (1992) Biological activity in the repopulating rat spermatocyte after withdrawal of gossypol treatment : III. The activity for transcription of messenger DNA. *Contraception* 48, 2: 167-176.

- 35- Dabrowski, K.; Rinchar, J.; Lee, K-J.; Blom, J.H.; Ciereszko, A. and Ottobre, J. (2000) Effects of Diets Containing Gossypol on Reproductive Capacity of Rainbow Trout (*Oncorhynchus mykiss*). Biol. Reprod. **62**, 227-234.
- 36- Luo, L.; Xue, M.; Wu, X.; Cai, X.; Cao, H. and Liang, Y. (2006) Partial or total replacement of fishmeal by solvent-extracted cottonseed meal in diets for juvenile rainbow trout (*Oncorhynchus mykiss*). Aquacul. Nutri. 12 (6), 418-424.
- 37- Nwoha, P.U. and Air, T.A. (1995b) Reduce level of serum cholesterol in low protein-feed Wister rats administered gossypol and chloroquine. Contraception 52 (4) 261-265.