

Anatomical and histological changes in the spleen of post hatching indigenous chicken in Iraq

Ali Faris Reshag and Rabab Adnan Hamza

Department of Anatomy and Histology, College of Veterinary Medicine, Baghdad University, Iraq.

E-mail: rabab1991927@gmail.com

Received: 15/12/2016

Accepted: 7/3/2017

Summary

The structure of the indigenous chickens spleen during the post-hatching period was determined by gross and light microscopical examination by using Hematoxylin and eosin and Massons Trichrome staining techniques. At one day old chicks the spleen was rounded in shape, pink in color. At two weeks old chicks the spleen was triangular in shape. At the progress of the aged the color of spleen became red-brown. In all ages the spleen consisted of white pulp and red pulp which were fused together. The spleen was encapsulated by thin connective tissue capsule contain few smooth muscles, the trabiculi were rare and thin. The red pulp consisted of venous sinuses surrounded by lymphatic cords. The white pulp consisted of peri-artery lymphoid sheath, peri-venous lymphoid sheath, peri ellipsoid lymphoid sheath, and Lymphatic follicles. The appearance of these elements was age dependant. At the first week of age the peri-artery lymphoid sheath and peri-venous lymphoid sheath were developed. At the third week, the peri ellipsoid lymphoid sheath, Lymphatic follicles were noticed and the plasma cells were scattered in the white pulp in addition to the lymphocytes. At one month of age, the germinal center appeared in some lymphatic follicle. The present study revealed that the spleen was well developed lymphatic organ at the age of three weeks.

Keywords: Red pulp, White pulp, Lymphocytes, Plasma cells, Germinal center.

Introduction

The spleen is lymphatic organ of avian immune system, and its importance in disease resistance (1). It is presumably accentuated by the scarcity of avian lymph nodes. There is some variation in size reflects species, age and seasonal changes in spleen morphology and activity mainly due to changes in the volumes of the lymphoid, the avian spleen is very dynamic organ in structure (2). The spleen in general is large hemal lymph node concerned with blood filtration and blood reservoir in addition to its main role in immunity; in avian, spleen act as blood storage (spleen storage of erythrocytes) is unrecorded, and the spleen contribution to oxygen supply is less important function than in mammals (3). The special role of spleen in development of the hemopoietic system is restricted in embryonic stage, after hatching the heamopoises in spleen is completely stopped (4). The spleen is enclosed by fibrous connective tissue capsule, with many thick septa going through the organ parenchyma. The spleen in all animals species is made of two areas, the white pulp which represents the lymphatic region, and the red pulp which consists of veins and blood sinuses

surrounded by lymphatic cords. The white pulp appeared as islands enclosed by red pulp and there was no distinct marginal zone between the red and white pulp (5). The main cells population of birds spleen are T-lymphocytes and B-lymphocytes distributed in network of reticular connective tissue which forms the back bone of the spleen stroma structure (6 and 7). Because of the great role of the spleen as secondary mixed organ in cellular and humeral avian immune response to infection and vaccination, this work was designed to study the histological changes in spleen with age.

Materials and Methods

Five healthy indigenous chickens at each of the following ages (1, 7, 14, 21, 30 and 60) days old were randomly selected for this study. The birds were obtained from local farm in Al Tagii north Baghdad. All birds were euthanized by administration of overdose of sedatives. The birds lay on back, the abdomen was opened and spleen was quickly removed. Washed spleen was cut into (4×4×4×4) mm pieces, fixed in 10% formalin two changes 24 hr. for each, dehydrated in a graded ethanol

series, clarified in xylene two changes, and embedded in paraffin wax. Then sectioned by rotary microtome at a thickness of (5-7) μm . After being deparaffinised and hydrated, the sections were stained with the Hematoxylin and eosin (H and E) stain for general histological structures, Massons Trichrome for connective tissue. The stained tissue sections were examined by conventional light microscopy (8).

Results and Discussion

The morphological observations at one day-two week old chicks, the spleen appears round in shape, pink in color. The spleen was located at right side of the abdomen, near the junction between the ventriculus (gizzard) and proventriculus, covered with the right lobe of liver. The spleen was extended from base of the lung to the cranial edge of the right cranial renal lobe (Fig.1). At (2-3) weeks old and older chicks the spleen was pale brown in color, triangular in shape, the two lateral sides were flat, the free surface was curved. This shape was constant with age, the color of the spleen changed, it appeared dark red- brown at (1-2) month old chickens (Fig.2). The morphological observations in the current study were similar to the observations mentioned by (7) and the result of (9) in broiler chicks, with one exception that the shape of the spleen was round in all ages, in the current study this was true in the first two weeks of the chicks life, in older chickens the shape of the spleen changed from round to triangular. The shape of the spleen in the indigenous chick was different from the shape of the spleen in the Guinea fowl, which was bean in shape by (10), in Ostrich the shape of the spleen was dark red elongated oval (11).

In all ages the spleen of the indigenous chickens was integument by splenic capsule which consisted of collagen fibers and smooth muscles; there was few thin trabeculi which originated from the capsule and passed through the spleen parenchyma, the splenic trabeculi hold the blood vessels (trabecular arteries and veins). Sub capsular sinus could be noticed as narrow space contained erythrocytes and lymphocytes. The general histological structures of the spleen parenchyma consisted of two indistinct areas

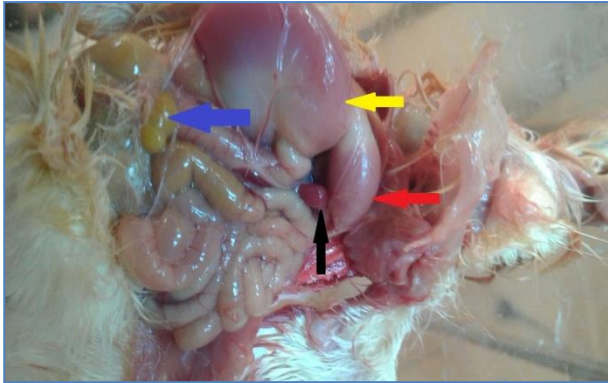
white and red pulps (Fig.3). These results were in agreement with results of (5 and 12-15). The splenic capsule and the two pulps were noticed and improved in the embryonic life and before hatching, these facts were mentioned by (16). In Partridge (*Alectoris Chukar*) they noticed the presence of complete capsule at the sixteen day of incubation, the red and white pulps were noticed at the twelve day of incubation center artery was noticed too by (17) who found that the spleen of quail embryo at the last stage of incubation had thin capsule covered the parenchyma. The parenchyma of the spleen consisted scattered red and white pulps.

At one day old chicks, the spleen was integument by thin connective tissue capsule. The splenic parenchyma consisted of diffused white and red pulps, there were marked line between the two areas, the peri-artery lymphoid sheath (PALS) was noticed, the peri-venous lymphoid sheath (PVLS) was not obvious and the peri ellipsoid lymphoid sheath (PELS) did not exists at this age. The venous sinuses surrounded by lymphatic cord were present (Fig. 4). The histological structure of spleen at the first day post hatching was similar to what was mentioned by (18) in duckling, and the results of (10) in guinea fowl, and disagree with the results of (17). They mention that the PELS was developed during the last day of incubation.

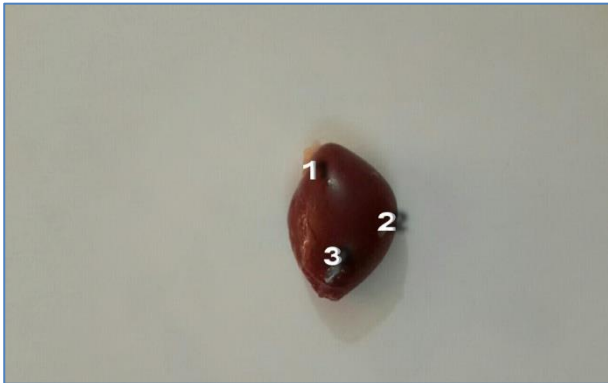At one week old chicks the PALS and the PVLS were present. The PELS and lymphatic follicles were absent, they were not developed in this age (Fig. 5). The white pulps cell population consisted mainly of small lymphocytes. This result was in parallel with results of (19) in chickens at the first day of age, they noticed the development of PALS and the PVLS occurring between two to six days after hatching (Fig. 6). The current study was in agreement with the results of (10) in Guinea fowl. The result of current study was different from the results of (20) who noticed that the PELS developed during the first week of chicks age.

At the age of two weeks the PELS started to develop, the pencilliform capillary was lining with cuboidal cells with round nucleus lay on basement membrane and surrounded by

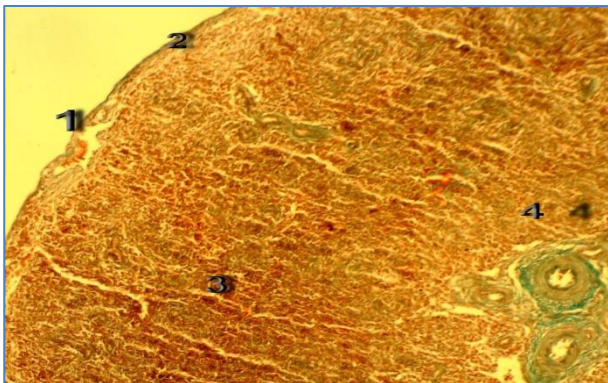
collagen fibers, few reticular cells were noticed (Fig. 7).



(Figure, 1): Photography of spleen at 1 day after hatching showing spleen (black arrow), proventriculus (red arrow), gizzard (yellow arrow) and yolk sac (blue arrow).



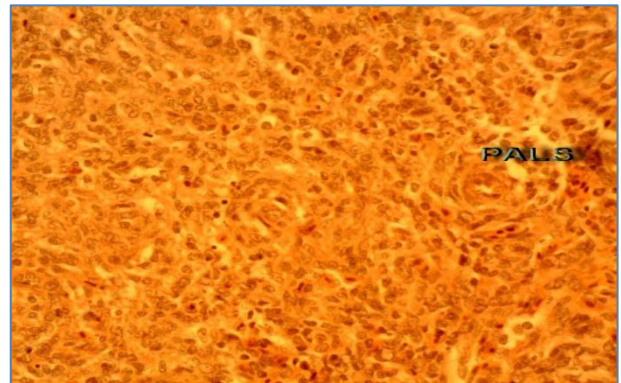
Figure, 2: Photography of spleen at 60 day showing 1.hillus, 2. Free surface and 3. Lateral surface.



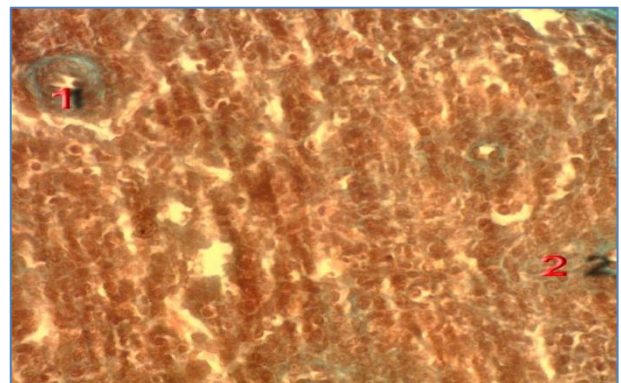
Figure, 3: At 1 day after hatching showing 1.Capsule, 2.Sub-capsular tissue, 3.Red pulp and 4.White pulp, Masson Trichrome x100.

This result was incompatible with the results of (9 and 21) in broiler chickens, they found that the red and white pulp were developed at two weeks old chickens. The spleen pulps development was incompatible with results of (10) in two weeks old Guinea fowl, who noticed that the development of the spleen pulps were complete at two to three weeks of age. At the age of (3-4) week, the

PELS was well developed; it consisted of (2-3) layers of large rounded cells and collagen fibers net work, lymphocytes were noticed too. The lymphatic follicles were there, it was without germinal center at three weeks age. At one month there was a germinal center in the center of some lymphatic follicles (Fig. 8). The plasma cells were noticed, the plasma cells were distributed through the whit pulp. At one month the presence of the plasma cells was obvious (Fig. 9).

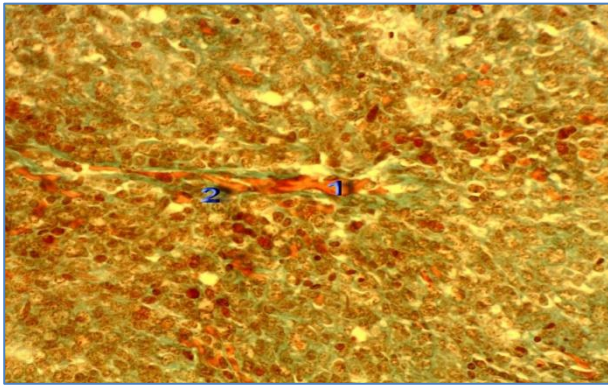


Figure, 4: At 1 day after hatching showing PALS, Masson Trichrome x400.

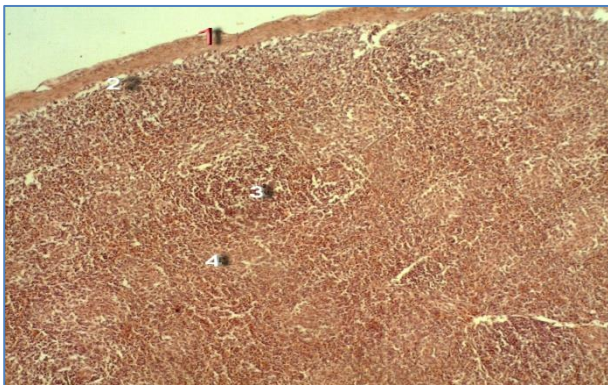


Figure, 5: At 7 day after hatching showing 1. PALS and 2.PVLS, Masson Trichrome x400.

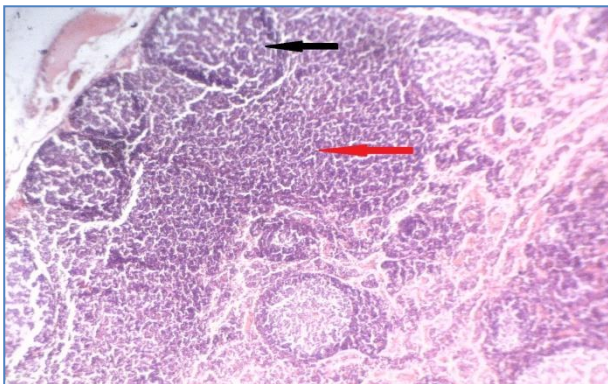
This finding was in agreement with the finding of (18) in duckling, (9, 17 and 22) in broiler chickens. The results of the current study about the appearance of plasma cells was different from what was mentioned by (19) who stated that the plasma cells appeared at two days after hatching, and disagreed with (10) who mentioned that the plasma cells appeared in the spleen of Guinea fowl at the seventh weeks of age.



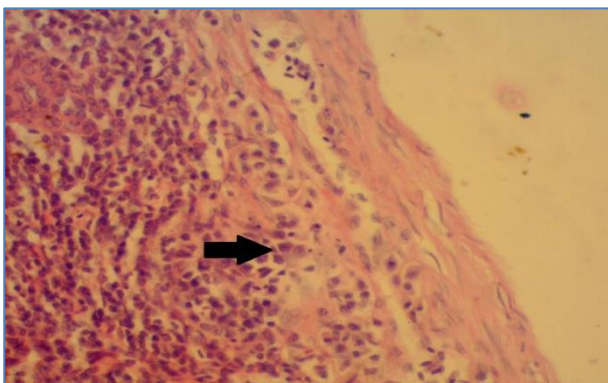
Figure, 6: At 7 day showing 1. Vein and 2, PVLS , Masson Trichrome x400.



Figure, 7: At 15 day showing 1. Capsule, 2.Sub-capsular tissue, 3.Red pulp and 4.White pulp, H and E X100.



Figure, 8: At 30 day showing: Follicle with germinal center (black arrow) and Follicle without germinal center (red arrow), H and EX100.



Figure, 9: At 60 day showing plasma cell (arrow), H and E X400.

References

1. Tiron, A. and Vasilescu, C. (2008). Role of the spleen in immunity. Immunologic consequences of splenectomy. *Chirurgia (Bucur)*, 103(3):255-263.
2. Silverin, B.; Fänge, R.; Viebke, P.A. and Westin, J. (1999). Seasonal changes in mass and histology of the spleen in Willow Tits *Parus montanus*. *J. Avian Biol.*, 30(3):255-262.
3. John, J.L. (1994). The Avian Spleen: A Neglected Organ. *The Quarterly Rev. Biol.*, 69(3):327-351.
4. Nicolas-Bolnet, C.; Yassine, F.; Cormier, F. and Dieterlen-Lièvre, F. (1991). Developmental kinetics of hemopoietic progenitors in the avian embryo spleen. *Exp Cell Res.*, 196(2):294-301.
5. Kannan, T.A.; Ramesh, G. (2015). Light and Electron Microscopic Details of blood-Spleen Barrier in Nandanam Chicken (*Gallus domesticus*). *Int. J. Sci. Res.*, 4(6):2203-2206.
6. Hoffmann-Fezer, G.; Rodt, H.; Götze, D. and Thierfelder, S. (1977). Anatomical distribution of T and B lymphocytes identified by immunohistochemistry in the chicken spleen. *Int Arch Allergy Appl. Immunol.*, 55(1-6):86-95.
7. Akter, S.H.; Khan, M.Z.I.; Jahan, M.R.; Karim, M.R. and Islam, M.R. (2006). Histomorphological study of the lymphoid tissues of broiler chickens. *Bangl. J. Vet. Med.*, 4(2):87-92.
8. Bancroft, J. and Stevens, A. (1986). *Theory and practice of histological technique*. (2nd ed.) Churchill living stone, London.
9. Khan, M.Z.I.; Masum, M.; Bin Aziz, A.R.; Nasrin, M.; Siddique, M.N.H. and Bin Arshad, M.M. (2014). Histomorphology of the lymphoid tissues of broiler chickens in Kelantan, Malaysia. *Sains Malaysiana*, 43(8): 1175-1179.
10. Onyeanusi, B.I. (2006). The Guinea fowl spleen at embryonic and post-hatch periods. *Anat. Histol. Embryol.*, 35:(3):140-143.
11. Song, H.; Peng, K.; Li, S.; Wang, Y.; Wei, L. and Tang, L. (2012). Morphological characterization of the immune organs in ostrich chicks. *Turk. J. Vet. Anim. Sci.*, 36(2): 89-100.
12. Hodges, R.D. (1974). *The histology of the fowl*. Academic press, New York. Pp:35-108.

13. Romppanen, T. and Sorvari, T.E. (1981). A Morphometrical study of chicken spleen with special reference to the bursa dependence of the white pulp. Int. Arch. Allergy Appl. Immun., 65:349-358.
14. Jeurissen, S.H.M. (1991). Structure and function of the chicken spleen. Res. Immunol., 142:352-355.
15. Kannan, T.A.; Geetha R.; Ushakumary, S.; Raj, G.D. and Vairamuthu, S. (2015). Light microscopic studies on spleen of chicken (*Gallus domesticus*). Haryana Vet., 51:114-115.
16. Haydarian, S.; Pousty.; Gilanpour, H. and Mortazavi, P. (2015). Histogenesis study on prenatal development of the spleen and thymus of partridge (*Alectoris Chukar*). Saussurea, 31:363-369.
17. Liman, N. and Bayram, G.K. (2011). Structure of the quail (*Coturnix japonica*) spleen during pre-and post-hatching periods. Rev. Med. Vet., 162:(1): 25-33.
18. Hashimoto, Y. and Sugimura, M. (1977). Histological and quantitative studies on the postnatal growth of the duck spleen. Japanese J. Vet. Res., 25(3-4):71-82.
19. Ogata, K.; Sugimura, M. and Kudo, N. (1977). Developmental studies on embryonic and post hatching spleens in chickens with special reference to development of white pulp. Jap. J. Vet. Res., 25: 83-92.
20. Mast, J. and Goddeeris, B.M. (1999). Development of immunocompetence of broiler chickens. Vet. Immunol. Immunopathol., Pp:245-56.
21. Khan, M.Z.I.; Hashimoto, Y. and Asaduzzman, M. (1998). Development of T-cell sub-populations in postnatal chicken lymphoid organs. Vet. Arch., 68(5):183-189.
22. Sultana, N.; Khan, M.Z.I.; Wares, M.A. and Masum, M.A. (2011). Histomorphological study of the major lymphoid tissues in indigenous ducklings of Bangladesh Bangl. J. Vet. Med. 9(1):53-58.

التغيرات التشريحية والنسجية في الطحال بعد الفقس في الدجاج المحلي العراقي

علي فارس رشك و رباب عدنان حمزة

فرع التشريح والانسجة، كلية الطب البيطري، جامعة بغداد، العراق.

E-mail: rabab1991927@gmail.com

الخلاصة

حُد في هذه الدراسة تركيب الطحال في الدجاج المحلي بعد الفقس وذلك باستعمال الفحص العياني والمجهري باستعمال تقنيات تصبغ الهيماتوكسين والأيوسين وصبغة ماسون ترايكروم. بعمر يوم واحد بعد الفقس يكون الطحال مدور الشكل وذو لون وردي وعند الاسبوع الثاني من العمر يتغير شكل الطحال ليصبح مثلث الشكل ومع تقدم العمر يتغير لون الطحال ليصبح بني محمر ويكون ثابت الشكل. يتكون الطحال من اللب الأبيض واللبن الأحمر، ويكون اللبان مختلطان مع بعضهما وليس هناك حد واضح يفصل بينهما. يحاط الطحال بمحفظة من النسيج الضام يحتوي بعض الألياف العضلية الملساء، الحويصلات نادرة الوجود وقليلة السمك. اللب الأحمر يتكون من جيوب وريدية محاطة بحبال لمفية. اللب الأبيض يتكون من الجريبات اللمفاوية، الغمد اللمفاوي المحيط بالشريان والغمد اللمفاوي المحيط بالوريد والغمد اللمفاوي المحيط بالإهليج) ويكون ظهور هذه المكونات معتمدا على التقدم بالعمر. خلال الاسبوع الأول من العمر الغمد اللمفاوي المحيط بالشريان والغمد اللمفاوي المحيط بالوريد يتطوران ويظهران. في الاسبوع الثالث يمكن ملاحظة الغمد اللمفاوي المحيط بالإهليج والجريبات اللمفاوية وتظهر خلايا البلازما منتشرة خلال اللب الأبيض فضلاً عن الخلايا اللمفاوية اما بعمر شهر يلاحظ ظهور المركز الانتاشي في بعض الجريبات اللمفاوية. يستنتج من نتائج البحث أن الطحال يصبح عضواً لمفاوياً كاملاً التركيب في عمر ثلاثة اسابيع.

الكلمات المفتاحية: اللب الأحمر، اللب الأبيض، الخلايا اللمفاوية، خلايا البلازما، المركز الإنتاشي.