

The Effect of Experimental *Escherichia coli* Infection on Some Blood Parameters and Histological Changes in Male Rats

Hayder AL – Zamely *

Shayma'a Z falh**

*Department of Physiology – College of Veterinary Medicine - University of AL- Qadisiya. Iraq.

**College of Science – University of Thicar. Iraq.

Accepted on 21/6/2011

Summary

This study was carried out to investigate the effect of experimental infection by *Escherichia coli* on some blood parameters and histopathological changes in male rats to reach this objective twenty male rats (*Rattus norvigicus*) were divided into two groups, housed under same conditions of water, feed, temperature, light and humidity. The first one served as control group, while the second was experimentally infected with *Ecoli* by administration of 2ml / rat of (1×10^9) colony forming unit/ml of *E-coli*. Five days later blood were obtained from animals by cardiac puncture to measure the total and differential white blood cells count hemoglobin concentration packed cells volume red blood cells count, and thrombocytes count. One animal from each group was killed and histopathological examination was done for intestine kidney liver and spleen to detect the effect of infection on these organs. The results revealed a significant increase in total leukocytes count ($P < 0.05$) in infected group while the differential count showed a significant increase in neutrophils and significant decrease in lymphocytes ($P < 0.05$) in same group. There were a significant decrease in hemoglobin concentration packed cell volume and non significant decrease in red blood cells count. While thrombocytes count showed a significant decrease in infected group compared with control group ($P < 0.05$). The histopathological examination of infected male rats intestine was demonstrated mild diffuse inflammation which include increased numbers of neutrophile in tissue intraepithelial lymphocytes and goblet cells In kidney renal tubules showed extensive epithelial swelling with decreased lumen space and generalized necrotic changes with interstitial hemorrhage in renal cortex. In liver hepatocytes were swollen with decreased sinusoidal spaces and widely distributed necrotic foci were seen. There is extensive splenic necrosis with infiltration of leukocytes from white pulp to red pulp of spleen.

Key words: *Escherichia coli*, male rats

تأثير الإصابة التجريبية بالايشريشيا القولونية في بعض المعايير الدموية والتغيرات النسيجية في ذكور الجرذان

** شيماء زغير فالح

* حيدر عبد الكاظم نغيش الزامل

** كلية العلوم/ جامعة ذي قار.

* فرع الفلسفة – كلية الطب البيطري – جامعة القادسية.

الخلاصة

أجريت هذه الدراسة لتحديد تأثير الإصابة التجريبية بالايشريشيا القولونية *E coli* في بعض المعايير الدموية والتغيرات النسيجية التي تحدثها في الجرذان ولتحقيق هذا الهدف استخدم اثنا عشر ذكرا من الجرذان قسمت الى مجموعتين متساويتين ووفر لها نفس الظروف البيئية (الماء الغذاء الأضاءة الحرارة والرطوبة) تركت الأولى كمجموعة سيطرة والمجموعة الثانية أصيبت تجريبيا بالايشريشيا القولونية عن طريق تجريعها (2ml) من الجرعة المحضرة (1×10^9 cfu). وبعد خمسة أيام من التجريع تم سحب الدم من القلب مباشرة من كلا المجموعتين بعد تخدير الحيوان لقياس المعايير الدموية التي شملت العد الكلي والتفريقي لخلايا الدم البيض والعد الكلي لكريات الدم الحمر تركيز

الهيموغلوبين حجم كريات الدم المرصوفة وعدد الصفائح الدموية ، وكذلك تم تشريح حيوان واحد من كل مجموعة واجراء تقطيع نسجي لكل من الأمعاء الكلية والكبد والطحال لمعرفة مدى تأثر هذه الأنسجة بالأصابة. أظهرت النتائج ارتفاع معنوي في عدد الخلايا الدم البيض في المجموعة المصابة تجريبيا بالاشيريشيا القولونية مقارنة بمجموعة السيطرة في حين أظهر العد التفريقي زيادة معنوية في نسبة خلايا العدلات وانخفاض معنوي في نسبة الخلايا اللمفية في المجموعة المصابة تحت مستوى احتمال (0.05) في حين أظهرت معايير كريات الدم الحمر انخفاض معنوي في كل من تركيز الهيموغلوبين وحجم خلايا الدم المرصوص وانخفاض غير معنوي في العدد الكلي لكريات الدم الحمر في حين أظهر عدد الأقراص الدموية انخفاضا معنويا في المجموعة المصابة مقارنة مع مجموعة السيطرة. أظهرت نتائج التقطيع النسيجي في مجموعة الأصابة ألتهاب بسيط منتشر مع زيادة في عدد العدلات داخل نسيج الأمعاء مع وجود خلايا لمفاوية وكأسيه في الظهارة في حين أظهر التقطيع النسيجي للكلى تورم في ظهارة النبيبات الكلوية وتضيق في تجويف الانبوب مع تنخر في عموم النسيج مع نزف في الفراغ البيني لقشرة الكلى ، كما أظهر نسيج الكبد في المجموعة المصابة تورم في الخلايا الكبدية مع تضيق في جيبانبات الكبد مع بؤر تنخرية منتشرة بشكل واسع في النسيج ، ولوحظ تنخر واسع في نسيج الطحال مع ارتشاح في خلايا الدم البيضاء من اللب الأبيض الى اللب الأحمر للطحال.

Introduction

Escherichia coli is the most numerous aerobic bacteria commensally inhabitants of the large intestine Certain strains cause diarrhea *E coli* normally inhabit the intestinal tract however some strains have acquired genes that enable them to cause intestinal infection When ingested can cause diarrhea (1). Each of these categories of diarrheagenic *E coli* had a specific O antigen Members which differ in different reference laboratories according to the purities and specificities of the antiserum used and some are non typeable (2 and 3). They produce active toxins once established in the host but all cases are food and water borne infections (3). There are hundreds strains causing diarrhea or hemorrhagic watery diarrhea in infants round the world (4). *Ecoli* O111:B4 was the predominant *Ecoli* serogroup and this serotype was isolated from healthy and diarrheic calves and from mastitic cows in Brazil (5). Enteric disease (white score) in calves caused by specific serotypes namely O8O9 and O20 these enteropathogenic *Ecoli* infections is a very serious disease during the first few weeks of life it occurs in all breeds of dairy calves (6). Pathogenic strains of enteropathogenic *Ecoli* are associated with disease of the gastrointestinal tract and with fulminating septicemia of the newborn calves or young animals (7). The objectives of the study are to identify:- The effect of *Ecoli* infection on some blood parameters which are include; Total White Blood Cells count, Differential White Blood Cells count, Red Blood Cells count, Platelets count, Packed Cells Volume and Hemoglobin concentration. In addition to: Histological changes that caused due to *E.coli* infection in; Intestine, Liver, Spleen and Kidney.

Materials and Methods

Twelve male rats (*Rattus norvigicus*) were obtained from animal house of Education College Thiqr University they were 10-12 weeks old and weighted around 220-250 gm and placed in cages labeled as control and infected. They were left for 5 days for a adaptation, and fed with standard rodent chow and provided with distil water. All animals were housed under controlled conditions (temperature [21 ± 2°C], humidity and a 12-hours light-dark cycle). *E coli* isolate was obtained from (AL Imamm ALHussin teaching hospital in Thiqr) and sub - cultured in a selective culture media (MacConkey Agar medium) and Brain heart infusion broth with glycerol as stock culture for bacterial isolates. Api-20E system (Analytical profile index for Enterobacteriaceae test) was used to identify the isolates (it is isolated from child clinical case). Infection was induced by oral administration of 2 ml sterile phosphate-buffered saline containing 1×10^9 colony forming units of *E coli* per gram (8). Control animals received distal water following the same protocol as *E coli*

infected animals. Animals were observed daily for activity level food and water intake. Blood were obtained from rats 5 days after inoculation. Blood were collected by cardiac puncture with a sterile needle and syringe and then evacuated in collection vial containing anticoagulant (Potassium EDTA) anticoagulant tubes were inverted gently several times immediately after sample collection and before use of blood to ensure uniform mixing blood samples were prepared immediately after sample collection and using Beckman coulter apparatus to determine Complete Blood cells Count(CBC). The CBC consist of a series of tests that determine number variety percentage concentrations and quality of blood cells. One rat taken from each group (infected and Control) anaesthetized dissected and the. Visceral organs were harvested (intestine Liver spleen and kidney) The harvested organs were preserved in 10% formalin solution.

Histological examination: According to (9) Fixation Dehydration Cleaning Wax Infiltration Embedding sample in wax sectioning dewaxing and staining (Haematoxylin and Eosin).

Statistical Analysis: T test and Statistical Package for Social Science (SPSS) system were used to analyze the data of our study

Results and Discussion

The results revealed that there are many effects of *Ecoli* infection in male rats blood parameters these effects include significant ($P < 0.05$) increase in total white blood cells count in infected group to reach (10.150 ± 3045) in compared with (8.525 ± 2378) in control group table (1), this increase may be due to *Ecoli* infection causing increase total leukocytes count is agreement with (10), this increase in fact may be due to an increase neutrophils as shown in (table 2), pathologic leukocytosis as a rule is an increase in segmented neutrophilic granulocytes this increase in neutrophils may be relative due to increase in the percentage of neutrophils or absolute due to increase in total leukocytes count (11), neutrophilia may be due to systemic infections like collibacillosis and salmonellosis (12). The results also showed there is an decrease in lymphocytes in infected group (table 2) which is may be due to stress of infection, because lymphopenia may be caused by stress which produces an moderate to marked absolute decrease in lymphocytes (10). There is a significant decrease ($p < 0.05$) in hemoglobin concentration and packed cells volume (%) with non significant decrease in erythrocytes count (table 3,4 and 5) respectively this may be due to break down of erythrocytes by hemolysis enzymes which is produce by *Ecoli* (13), and this lead to decrease in number of erythrocytes which then lead to decrease in PCV % and hemoglobin concentration (11). Also there is a significant decrease in thrombocytes in infected group (table 6). The decrease in number of platelets in this study may be due to infection (14), because platelets may be destroyed in large number following antigen-antibody reactions on the platelets surface membrane this probably causes the majority of so-called idiopathic thrombocytopenia in animals (15). The histological examination of infected groups showed mild diffuse inflammation with high numbers of neutrophils (figure 1) which may be due to attachment of bacteria to the intestinal cells which cause lesion progressing with effacement of the microvillus and changing the cells morphology (16). In the kidney of infected group animal showed extensive epithelial swelling in renal tubules with decreased lumen space and necrotic changes with hemorrhage (figure 2), these changes may be due to alpha and beta – hemolysis which cause lysis of urinary tract cells (13), the liver showed swelling of their hepatocytes (figure 3) with decreased sinusoidal spaces and necrotic foci and this may be duo to *E coli* infection because there is same degree of liver necrosis displayed by the hepatic cells in all bacterial infections (17), also there is hemorrhagic foci and microthrombi which may caused by intra

–vascular –hemolysis (1), and this occur due to shiga like toxin that produce from *Ecoli* which cause vascular damage (18) in spleen there is necrosis with disappearance of leukocytes from white pulp and infiltrated to the red pulp of spleen (figure4). This agreement with (19) who say that there is discrete focal necrosis composed of centrally located neutrophil foci rimmed by macrophages and reactive fibroblasts and lesions included decreased white pulp area in spleen suffer from bacterial infection.

Table (1): Effect of *E coli* infection on mean of total white blood Cells count.

Parameter	Control group M±SE	Infected group M±SE
Total white blood cells count (x10 ³ /mm ³)	8.525 ± 2378	10.150 ± 3045*

*Significant differences (P<005) Number of animals = 6 for each group. The numbers = mean ± SE.

Tabel (2): Effect of *E coli* infection on mean of Neutrophils and Lymphocytes percentage.

Parameter	Control group M±SE	Infected group M±SE
Neutrophils (%)	3933 ± 479	5273 ± 906*
Lymphocytes (%)	5633 ± 182	4181 ± 616*

*Significant differences (P<005) Number of animals = 6 for each group. The numbers = mean ± SE.

Table (3) Effect of *E coli* infection on mean of Red Blood Cells (RBCs) count.

Parameter	Control group M±SE	Infected group M±SE
Red blood cells (x10 ⁶ /mm ³)	499 ± 05	43 ± 193

There is no Significant differences (P<005) Number of animals = 6 for each group.

Table (4) Effect of *E coli* infection on mean of Hemoglobin (Hb) concentration.

Parameter	Control group M±SE	Infected group M±SE
Hemoglobin (g/dL)	132 ± 026	*103 ± 091

*Significant differences (P<005) Number of animals = 6 for each group The numbers = mean ± SE.

Table (5) Effect of *E coli* infection on mean of Packed cell volume (PCV).

Parameter	Control group M±SE	Infected group M±SE
Packed cells volume (%)	3943 ± 099	*3008 ± 246

*Significant differences (P<005). Number of animals = 6 for each group.

Table (6) Effect of *E coli* infection on mean of Platelets count.

Parameter	Control group M±SE	Treated group M±SE
Platelets (x10 ³ /mm ³)	66283 ± 3114	*27016 ± 12402

*Significant differences (P<005). Number of animals = 6 for each group.



Figure – 1 – sections of intestine at 5days after *Ecoli* oral dosing arrows in panels (A) sparse IEL and lamina propria PMNs in control tissue the colon of *Ecoli*-infected rat showed increases in the numbers of intestinal IELs (B) and lamina propria PMNs (arrows) with crypt abscesses Hematoxylin-eosin (HE) (X40).

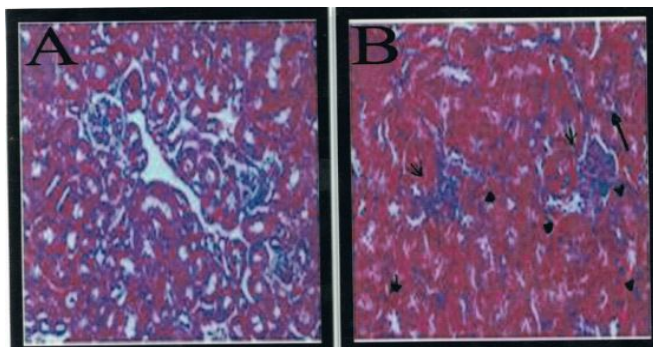


Figure – 2 – sections of kidney *Ecoli*- infected rat The renal cortex contained microthrombi (small arrows) and interstitial hemorrhages (small arrowheads) and glomeruli were congested (open arrowheads) (B)capillary lumina were frequently obstructed Renal tubular epithelial cells were also swollen with diminished lumen diameter and many were undergoing necrotic change (B) Hematoxylin-eosin (HE) (X40).

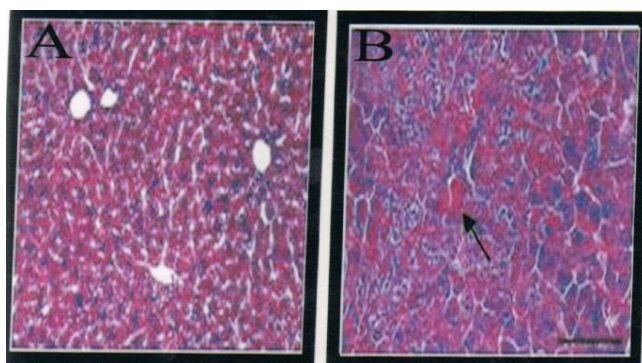


Figure 3 sections of liver *Ecoli*- infected rat Extensive microthrombi and hemorrhagic foci were found (large arrows) (B) Hematoxylin-eosin (HE) (X40).

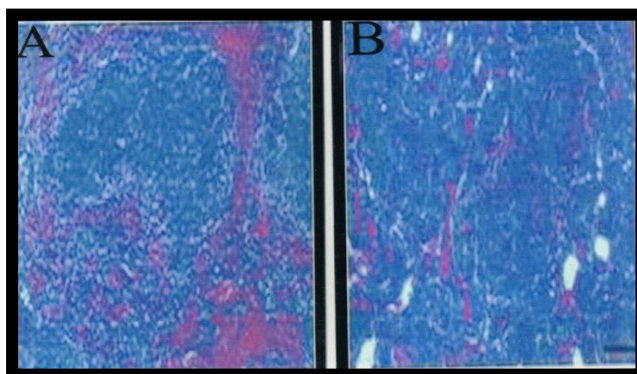


Figure 4 sections of spleen *Ecoli*- infected rat Extensive leukocyte infiltration after infected rat compared with normal control spleen tissue (A) Leukocytes disappeared from white pulp and infiltrated the red pulp (B) Hematoxylin -eosin (HE) (X40).

References

1. Nadim M An AL-Samarrae SAG Zafer SA Hanna AT and Khalf AM (1982). Clinical Veterinary medicine 1st ed AL-Resala-Kiwutpp: 2274 .
2. Mehlman IJ Romero A Atkinson JC Aulisio C Sanders AC Campbell W Cholenski J Ferreira J Forney E O'Brian K Palmieri M and Weagant S (1982). Detection of invasiveness of mammalian cells by *Escherichia coli* : Collaborative study. J Assoc Anal Chem .65:602-7.
3. Levine M M Nataro J P Karch H Baldini M M Kaper J B Black R E Clements M L and O'Brien A D (1985). The diarrheal response of humans to some classic serotypes of enteropathogenic *Escherichia coli* is dependent on a plasmid encoding an enteroadhesiveness factor .J Infect Dis. 152: 550-559.
4. Kerr M Fitzgerald M Sheridan JJ McDowell DA and Blair IS (1999). Survival of *Escherichia coli* O157:H7 in bottled natural mineral water. J Appl Microbiol 87:833-841.
5. Dosogne H Sturk A Vanloon J Massart Leen A and Buurvenich C (1997). Effect of enrofloxacin treatment on plasma endotoxin during bovine *E. coli* mastitis. Inflamm Res. 51:201-205.
6. Burvenich C Van Merris V Merhazd J Diez -Fraile A and Duchateau L. (2003). Severity of *E. coli* Mastitis is Mainly determined by cow factors. Vet Res. 34: 554-564.
7. Garch H Meyer Trussmann H and Hesemaan J (1992). Frequent loss of shiga -like toxin genes in clinical isolates of *E. coli* upon subcultivation. 60: 3464- (Abstract).
8. Ali MZ (2007). A bacteriological and Genetic of Enteropathogenic *E. coli* in AL-Najaf AL-Ashraf Governorate Collage of Education for Girls /University of Kufa .
9. Almas K (1999). Histopathology. Indian J 10: 23-6.
10. Coles EH (1986). Veterinary clinical pathology 4th ed W B Saunders company. pp: 6468105
11. Feldman BF Zinkl J C and Jain NC (2000). Schalm's Veterinary hematology 5th ed. Lippincott Williams and Wilkins pp: 38 .
12. Dale DC and Liles C (1998). .How many neutrophils are enough? Lancet. 351:1752-1753.
13. Justice S Hunstad D Seed P and Hultgren S (2006) . Filamentation by *Escherichia coli* subverts innate defenses during urinary tract..infection. Proc Natl Acad Sci USA 103 (52): 19884-9.
14. Green RA (1983). Bleeding disorders In : Text Bbook of Veterinary Internal medicine Diseases of the Dog and Cat. Edited by Ettinger SJ 2nd ed. Saunders company Philadelphia. pp: 41-49.
15. Dodds WJ (1980). Hemostasis and coagulation In: Clinical Biochemistry – of Domestic Animals. edited by Kaneko JJ 3rd ed. Academic press .New york pp:53-56.
16. Knutton S Baldwin T Williams P H and McNeish A S (1989). Actin accumulation at sites of bacterial adhesion to tissue culture cells: basis of a new diagnostic test for enteropathogenic and enterohemorrhagic *Escherichia coli* .Infect Immun .57: 1290-8 .
17. Griffin P M L C Olmstead and R E Petras (1990). *Escherichia coli* O157:H7-associated colitis: a clinical and histological study of 11 cases. Gastroenterology. 99:142-149 .
18. Cater A O Borczyk A A and Carlson J A K (1987). A severe outbreak of *Escherichia coli* O157:H7-associated hemorrhagic colitis in an nursing home N .Engl J Med .317:1496.
19. Dial SM (1995). The hematopoietic system lymph node and spleen. In: Geriatrics and Gerontology of the Dog and Cat. Goldston RT and Hoskins JD Eds. Philadelphia Saunders pp: 275 .