

Evaluation of selected parameters of rat liver injury following repeated administration of oseltamivir for different periods

Falah Muosa Kadhim Al-Rikabi

Department of Physiology and Pharmacology, College of Veterinary Medicine
Baghdad University, Iraq

Summary

The effects of oseltamivir administration, an anti influenza viruses A and B, on some functional parameters of rat liver were investigated, to evaluate the possible hepatotoxic effect. Eighteen (18) wister male albino rats with body weight ranged 150-190 gm were divided into three groups, the first group(T1) was treated orally with 1mg/kg.BW as therapeutic dose of Oseltamivir for 7 consecutive days. The second group (T2) was treated with the same dose for six weeks, while the control group dosed distill water. The results revealed, there was a significant increase in the onset of barbiturate sleeping time and a significant $p \leq 0.05$ decrease of the duration of barbiturate sleeping time of the T2 rats . The liver enzymes activity revealed a significant decrease in ALT in T1 rats and significant increased $p < 0.05$ in the T2 rats, while the AST activity showed only significant increased $p < 0.05$ in the T2 treated rats. The activity of ALP was $p < 0.05$ significantly increased in the rats of treated groups. The blood sugar was significantly decreased $p < 0.05$ only in the T2rats. Cholesterol level was significantly $p < 0.05$ increased in T2 treated rats, while the serum of both treated groups showed a significant increase $p < 0.05$ in the triacylglycerol concentration.

The HDL level was significantly decreased $p < 0.05$ only in the T1 rats. The treated T2 rats showed a significant decrease $p < 0.05$ in the LDL, while the VLDL level revealed a significant increase $p < 0.05$. The total serum protein level was significantly increased $p < 0.05$ in the rats of T2. Liver histopathological lesions of the T1rats revealed large amount of suppurative exudates, severe dilation and congestion of central veins and sinusoids with activation of kupffer cells. The liver of T2 rat showed multiple areas of focal necrosis, fibrous thickening of Glisson capsule with vacuolar degeneration of hepatic parenchyma. In:conclusion, Oseltamivir has hepatotoxic effect in rats treated with therapeutic dose 1mg/ kg.BW. orally in different periods.

Key words:- Oseltamivir, Liver injury ,Rat.

E.mail :-fab20062003@yahoo.com.

تقييم بعض معايير إصابة الكبد في الجرذان المجرعة لفترات مختلفة بعقار

الأوسلتيمافير

فلاح موسى كاظم الركابي

فرع الفسلجة والأدوية/كلية الطب البيطري / جامعة بغداد/العراق

الخلاصة

تم تقييم بعض معايير وظائف الكبد في الجرذان المعاملة بعقار الأوسلتيمافير المضاد للإنفلونزا A,B. أستعملت 18 من ذكور الجرذان المهفء بأوزان تراوحت 150-190 وقسمت إلى ثلاث مجاميع بصورة متساوية وجرعت جرذان المجموعة الأولى(T1) بالجرعة العلاجية لعقار الأوسلتيمافير 1ملغرام / كيلوغرام من وزن الجسم لمدة سبعة أيام. أما جرذان المجموعة الثانية(T2) كانت فترة التجريب لمدة ستة أسابيع وبنفس الجرعة. أما المجموعة الثالثة فعدت سيطرة وجرعت ماء مقطر. وقد أظهرت النتائج أن فحص وقت النوم المستحث بالثايوبنتال الصوديوم أظهر زيادة معنوية في فترة الكمون مع نقصان معنوي في فترة النوم $p \leq 0.05$ لجرذان المجموعة الثانية. أما فحص نشاط إنزيمات أذى الكبد فقد أظهرت نقصاناً معنوياً $p < 0.05$ في نشاط ALT لجرذان المجموعة الأولى. في حين أظهرت جرذان المجموعة الثانية زيادة معنوية في نشاط نفس الأنزيم وعلى نفس المعنوية بينما سجل نشاط أنزيم

AST زيادة معنوية $p < 0.05$ في جردان المجموعة الثانية، في حين سجل نشاط إنزيم ALP زيادة معنوية في كلتا مجموعتي المعالجة. وأظهر سكر الدم نقصانا معنويا $p < 0.05$ في جردان المجموعة الثانية. في حين كانت هناك زيادة معنوية $p < 0.05$ في مستوى الكولسترول في مصل دم جردان المجموعة الثانية، أما مستويات الدهون الثلاثية فقد سجلت زيادة معنوية $p < 0.05$ في مجموعتي المعالجة بالعقار. أما فحص مستويات نمط الدهون البروتينية في الدم فقد أظهرت نقصانا معنويا $p < 0.05$ في مستوى الدهون البروتينية عالية الكثافة (HDL) في جردان المجموعة الأولى، وسجلت نقصانا معنويا $p < 0.05$ في مستوى الدهون البروتينية واطئة الكثافة (LDL) في جردان المجموعة الثانية، أما مستوى الدهون البروتينية واطئة الكثافة جدا (VLDL) سجلت زيادة معنوية $p < 0.05$ فقط في جردان المجموعة الثانية أما فحص مستوى بروتين مصل الدم أظهر زيادة معنوية $p < 0.05$ في جردان المجموعة الثانية.

الفحص النسجي المرضي للكبد :- أظهر نضح تقيحي، توسع واحتقان الأوردة المركزية والجيبات ونشاط خلايا كفر في جردان المجموعة الأولى، أما أكباد جردان المجموعة الثانية فقد أظهرت بقع تنخرية متعددة، تتخّن ليفي لمحفظة كلايسون مع تغيرات فجوية في الخلايا البرنكيميائية. تستنتج الدراسة ان لعقار الأوسلتيمافير تأثير سمي في أكباد الجردان المعاملة بجرعة علاجية 1 ملغم/كغم من وزن الجسم ولفترات مختلفة.

الكلمات المفتاحية: الأوسلتيمافير، الجرذ، الإصابات الكبد.

Introduction

Oseltamivir is a potent and selective inhibitor of the neuraminidase enzyme of the influenza viruses A and B(1), and it is used in the treatment and prophylaxis of both influenza viruses (avian and swine influenza) (2). Oseltamivir is rapidly hydrolyzed to its active form oseltamivir carboxylate (Ro 64-0802), by human carboxylesterase 1 (hCES1) in the liver (3). After oral administration, oseltamivir is readily absorbed from the gastrointestinal tract. The active metabolite is detectable in plasma 30 minutes after dosing (4). Oral oseltamivir has generally been well tolerated in patients with influenza given the standard oral dosage of 75mg bid. Nausea (9.9%) and vomiting (9.4%) were the most frequently reported adverse events. Similar results were seen in children. Other events such as diarrhea, bronchitis, abdominal pain, dizziness and headache were seen in less than 7% of recipients. Gastrointestinal events generally appear within the first one to two days and resolve thereafter (5). The oseltamivir ethyl ester is well absorbed and rapidly metabolized to active oseltamivir carboxylate. The bioavailability of the oseltamivir carboxylate is about 80% after oral administration of the prodrug (6 and 7). The liver is prone to xenobiotic – induced injury because of its central role in xenobiotic metabolism., its portal location within the circulation, and its anatomic and physiologic structure (8). Drug – induced liver injury (DILI) is a major health problem that challenges not only health care professional, but also the pharmaceutical industry (9). Because of the significant patient morbidity and mortality associated with DILI, the USA Food and Drug Administration (FDA) have removed several drugs from the market (10). This work is set out to provide information on the effect, if any, of repeated administration of oseltamivir at the required therapeutic dose 1mg/kg.BW on selected functional indices of rat liver. This was evaluated by monitoring some functional tests for rat liver. The aim of the study is to evaluate the possible hepatotoxic effect of oseltamivir in male albino rats.

Materials and Methods

Preparation of Oseltamivir solution by dissolving one capsule-Oseltamivir (Flufly)[®] capsule 75 mg. (Julphar-Ras Al Khimah-UAE) in 75 milliliters of distilled water to achieve concentration of 1mg/ml. Each 100 gm of body weight of rat dosed 0.1 ml of drug solution which contained 0.1mg of Oseltamivir as therapeutic dose.

Wister male albino rats with body weight ranged 150-190 gm were procured from the animal house of the College of Veterinary Medicine, University of Baghdad,

maintained in an air conditioned room (25 ± 1)°C with a 12 hours light : 12 hours dark cycle. Standard pellet diet and water were provided ad libitum (11).

Barbiturate sleeping time :- eighteen rats divided into three equal groups (T1, T2, control) subjected to barbiturate induced sleeping time test which performed according to the method of (12). The T1 group dosed 1mg/kg.BW orally (by orogastric tube) as therapeutic dose of Oseltamivir for 7 consecutive days. The T2 group also dosed the same dose but for six weeks, while the control group dosed distilled water. All groups injected IP with 25 mg/kg. Thiopental sodium (THIOPENTAL)[®] 1gm obtained from Egyptian international pharmaceutical industries CO A.R.E an ultra-short barbiturate. The time elapsed between the loss and voluntary recovery of the righting reflex was recorded as sleeping time. Sleep latency was also recorded.

Clinical study:- eighteen rats divided equally into three groups (T1, T2 and control) subjected to blood biochemical analysis. The both two treatment groups were dosed in the same pattern mentioned above, while the control group dosed distilled water. Blood collected through heart puncher post treatment from anesthetized animals of all groups by ketamine HCL (Ketamin 10%)[®] obtained from KEPRO- HOLLAND and xylazine HCL (XYLAZIN 2%) obtained from CEVA-GERMANY . The serum obtained by centrifugation of all blood samples with 5000rpm for five minutes.

All the animals of groups T1 and T2 were sacrificed at the end of dosage period. Livers obtained and preserved in 10% formalin saline, then sent to laboratory of medicinal city hospital for histopathology processing according to (13).

Blood biochemical analysis:- The activities of aspartate aminotransferase (AST), alanine aminotransferase (ALT) and alkaline phosphatase (AP) assessed by using commercial available kit (RANDOX- UK). The serum cholesterol was assessed by using commercial kit (Biomaghreb), which is enzymatic colorimetric test depending on hydrolysis and oxidation (14, 15, and 16). Serum triacylglycerol were estimated by using diagnostic kit (BIOLAB SA – FRANCE), depending on the formation of colored complex (quinoneimine) (17). HDL, LDL and VLDL were assessed by using commercial kit (Biomaghreb) depending on precipitation of LDL, VLDL and chylomicron fractions (18 and 19). Total serum bilirubin, direct bilirubin and indirect serum bilirubin were assessed by using available commercial kit (BIOLAB SA – FRANCE), which is depending on formation of azobilirubin (17) . Blood glucose was assessed by Trinder reaction (14). Which is depending on the formation of red quinonimine by using available commercial kit (LINEAR chemicals – SPAIN). Total serum protein assessed by biuret reaction, chelate formed between the Cu^{++} ion and the peptide bonds of protein in alkaline solution to form violet complex. Photometrically measured at 540 nm wave length (20).

Statistical analysis was conducted according to SPSS version 13.00. The ANOVA one way used for significances assessment between groups. The P – value < 0.05 considered as statistically significant. LSD multiple range tests was carried out for comparing between means (21).

Results and Discussion

Barbiturate sleeping time:- There was significant increase $p \leq 0.05$ in the onset of barbiturate sleeping time of the animals that received therapeutic dose of oseltamivir for six weeks (T2) in comparison with the pretreatment onset of the same group and with both T1 treated group which received therapeutic dose of oseltamivir for one week T1 and the control one which was received distilled water (table 1), while the duration of barbiturate sleeping time revealed significant decrease $p < 0.05$ in the same pattern of the onset time (table 1).

ALT AST and ALP serum activity:-The liver injury enzymes activity revealed significant decrease $p < 0.05$ in ALT of the animals of T1 treated group (9.16 ± 0.70)U/L and significant increase in the animals of T2 treated group (50.00 ± 1.89)U/L in comparison with the animals of control group (18.8 ± 1.35) (table,2). The AST activity showed only significant increase $p < 0.05$ in the animals of T2 group (113.33 ± 3.80)U/L in comparison with both T1 treated group and the control one. The activity of ALP were significantly increased $p < 0.05$ in both treated group animals T1 (120.50 ± 32.18)U/L and T2 (78.16 ± 12.18)U/L in comparison with the control one (30.40 ± 2.73)U/L,(table,2).

Random blood sugar: - The random blood sugar is significantly decreased $p < 0.05$ only in the animals of T2 treated group (98.50 ± 18.06)mg/dL in comparison with the animals of T1 treated group and the control one, (table 3).

The cholesterol level is significantly increased $p < 0.05$ in the animals of T2 treated group (125.50 ± 10.42)mg/dL in comparison with both T1 treated group animals and the control one .while the animals of both T1 and T2 treated groups showed significantly increase $p < 0.05$ in the triacylglycerol level between them and in comparison with the control one (Table 4).

The result of HDL level is significantly decreased $p < 0.05$ only in the animals of T1 treated group (27.00 ± 2.86)mg/dL in comparison HDL level in the animals of both T2 treated group (45.50 ± 7.20)mg/dL and the control one (40.50 ± 2.68) mg/dL (table,5).The animals of T2 treated group showed significant decrease $p < 0.05$ in the LDL (30.66 ± 13.04)mg/dL in comparison with the LDL level of both T1 treated group (64.90 ± 6.97)mg/dL and the control one (73.64 ± 4.93)mg/dL(table,5). While the results of VLDL level revealed only significant increase $p < 0.05$ in the animals of T2 treated group (63.66 ± 0.61)mg/ dL in comparison with VLDL level in the animals of both T1 treated group (5.43 ± 0.55)mg/ dL and the control one (6.14 ± 0.75)mg/dL,(table,5).

The total serum protein level is significantly increased $p < 0.05$ only in the animals of T2 treated group (620.00 ± 18.38)mg/dL in comparison with its level in the animals of both T1 treated group (278.66 ± 9.10)mg/dL and the control one (327.40 ± 40.29) mg/dL (Table,6).

The results of total serum bilirubin (T.S.B) level revealed significant decrease $p < 0.05$ only in the animals of T2 treated group (1.15 ± 0.17) mg/dL in comparison with its level in the animals of both T1 treated group (3.08 ± 0.32)mg/dL and the control one (3.68 ± 0.66)mg/dL(table,7),while the level of direct serum bilirubin revealed significant increase $p < 0.05$ in the animals of T1 treated group (2.73 ± 0.21)mg/dL in comparison with its level in the animals of both T2 treated group (0.66 ± 0.17)mg/dL and the control one (0.74 ± 0.15)mg/dL(table,7) , but there is a significant decrease $p < 0.05$ in the level of indirect serum bilirubin of both T1 treated group animals (0.35 ± 0.10)mg/dL and T2 treated group animals (0.33 ± 0.14)mg/dl in comparison with control group (2.90 ± 0.64)mg/dL(table,7).

The histopathological lesion in liver rats received therapeutic dose 1mg/kg.BW for one week revealed large amount of suppurative exudates contains large number of neutrophils in the pre-hepatic area (figure 1).There are severe dilation and congestion of central veins and sinusoids with activation of kupffer cells were also had seen (figure 2).Furthermore there is focal infiltration of mononuclear cells in the liver parenchyma with vacuolation of hepatocytes (figure 3). The liver of rats treated with one 1mg/kg.BW oseltamivir for six weeks revealed multiple areas of focal necrosis characterized by pyknosis or disappearance of nuclei of hepatic cells (figure 4).There is fibrous thickening of Glisson capsule with vacuolar degeneration of hepatic parenchyma(figure 5).In addition there is a slight fibrous thickening in the wall of central vein.

The barbiturate induce sleeping time is the one of the tests performed to evaluate liver toxicity. The sleep latency and the elapsing between the loss and voluntary recovery changes impose as measurement of liver toxicity. The increasing of the onset and decreasing of the duration of sleeping time in the animals ,that had dosed 1mg/kg.BW oseltamivir for six weeks may indicate liver injury ,which is confirmed by histopathological lesion of liver (necrosis, fibrous thickening of Glisson capsule, vacuolar degeneration of hepatic parenchyma .The liver is richest source of drug metabolism (22).Carboxylesterases are a class of enzyme that play important roles in the hydrolytic metabolism of drugs and other xenobiotics , patient with liver condition such as cirrhosis shows decreased capacity of hydrolytic biotransformation(23). It can say that the oseltamivir dosed for six weeks interfere with liver biotransformation of thiopental sodium and led to increase the onset and decrease the duration of sleeping time, and may through enhancing the hydrolysis pathway. The liver performs different kinds of biochemical, synthetic and excretion function, so the biochemical indices that had performed are useful parameters to indicate impairment of functional capability of the liver. There is no single test for measuring liver function, because all the functions of the liver are not equally or simultaneously affected in hepatobiliary disorder (24).

Aminotransferases (ALT, AST) and alkaline phosphatase tests are helpful screening tool to detect injury of hepatocyte. The significant increase serum activity of ALT, AST and ALP in the rats dosed 1mg/kg.BW oseltamivir for six weeks ,may be due to sever hepatic injury(necrosis , vacuolar degeneration).While the significant increase of ALT serum activity in the rats that dosed 1 mg/kg.BW for one week is may be due to mild liver injury(inflammation ,vacoulation).The elevation of AST and ALT serum activity is moderate and not severe ,because the elevation range (3-20) times considered as moderate in acute and chronic hepatitis ,autoimmune hepatitis and drug induced hepatitis(25).The decline in serum activity of ALT and AST of rats that dosed 1mg/kg.BW oseltamivir for one week, may indicate recovery of poor prognosis in fulminant hepatic failure(26and27).

Alkalinephosphatase is found histochemically in the microvlli of bile canaliculi and sinusoidal surface of hepatocytes (27). So the significant increase in ALP activity of rats dosed 1mg/kg. BW of oseltamivir for one and six week is due to the suppuration which is found in the livers. Rosalk and McIntyre (27) found that elevation of ALP activity may be seen in infiltrative liver disease, abscesses, granulomatous liver disease and hepatitis .Oseltamivir has been associated with hepatitis and abnormal liver function testes(28). Wael and Mohamed (29) found that oseltamivir dosed with 2.2mg/kg.BW to rats for five days, caused acute liver toxicity, modest reduction in hepatic activity in both genders, but with elevation ALP activity.

The liver is consider the site of glycolysis and glucogenesis, so the estimation of blood sugar may be one of the helpful tool for detection liver injury .The significant decrease in random blood sugar in the rats dosed 1mg/kg.BW oseltamivir for six weeks maybe an indicator of the liver damage, which may resulted from the repeated exposure to oseltamivir, in comparison with the rats exposed to oseltamivir for one week and rats of control group, which were have no blood sugar changes. Recent studies have shown that hypoglycemia is associated with many acute illnesses (30). The liver illness induced by oseltamivir is clearly appear in histopathological finding of rats treated for six weeks which represented by necrosis and vacuolar degeneration. About 80% of body cholesterol is produced by the liver, while the rest comes from food , after meal dietary cholesterol absorbed from the intestine and stored in the liver. The liver is able to regulate cholesterol activity in blood stream and can secrete cholesterol if it is needed by the body(31).Cholesterol is excreted by the liver via bile into digestive tract (32) .So the significant increase in the cholesterol and VLDL of rats dosed 1mg/kg.BW oseltamivir

is due to hepatotoxic effect of oseltamivir and/or its metabolite ,which represented by necrosis ,fibrosis and vacuolation. The increases in LDL-cholesterol also found in male rats which were administered 2.2mg/kg.BW oseltamivir for five days (29). We are assume that the significant increase of triacylglycerol, VLDL and decrease of HDL level may be due to shortage in lipoprotein lipase (LPL) production (enzyme that hydrolyzes triglycerides and conversion of VLDL to IDL then to LDL) , While the site of the LPL synthesis in the parenchymal cell(hepatocyte) (33).The shortage of LPL production is due to pathological effect of repeated therapeutic dose of oseltamivir for six weeks on liver .The important signs of liver dysfunction are elevated LDL ,reduced HDL and elevated triacylglycerol.

The serum protein test is one of the tests of the liver biosynthesis capacity (25). Chemotherapy drugs can be damage the liver as side effect, and it is one of the liver dysfunction causes. The liver dysfunction is one of important causes of total serum protein increasing. This concept is confirmed by the significant increase in serum protein level of the rats that had dosed 1mg/kg.BW of oseltamivir for six weeks. Albumin is the major protein in serum, Albumin synthesis is affected not only in liver disease , but also by nutritional status , hormonal balance and osmotic pressure(27).We are suggest that oseltamivir dosed to the rats as phosphate salt for six weeks ,may led to change the osmotic pressure due to high phosphate supplement with the drug, and resulted increase serum protein level. Where rats could not hydrolyze the oseltamivir phosphate to its metabolite (oseltamivir carboxylase) that will lead to accumulate extensive amount of phosphate this would negatively affect the calcium /phosphate ratio (34).

The bilirubin in the body is a careful balance between production and removal of the pigment in body, serum bilirubin is a test of the liver capacity to transport organic anions and metabolize drugs (25). Serum bilirubin could be lowered by drugs like salicylates, sulphonamides and free fatty acids which displace bilirubin from its attachment to plasma albumin (35). Parenchymal liver diseases or incomplete extra hepatic obstruction due to biliary canaliculi give lower serum bilirubin value (36).The decrease in total serum bilirubin level of the rats treated orally for six weeks with 1mg/kg.BW oseltamivir is may be due to the necrosis of hepatocytes and vacuolar degeneration of hepatic parenchyma which had observed in their's livers.

Oseltamivir induced liver injury in the rat treated with therapeutic dose for seven consecutive days and six weeks through infiltration of mononuclear cells and neutrophils in parenchyma , congestion of central vein ,which are considered as indicators of drug induced liver injury by larrey(37) who found ,the drug induced liver injury can affect both parenchymal and nonparenchymal cells of liver , including acute and chronic hepatitis, fibrosis, cirrhosis, cholestasis, steatosis, as well as sinusoid and hepatic artery /vein damage.

Direct hepatotoxicity is often caused by the direct action of a drug or more often reactive metabolite of drug against hepatocytes, Acute hepatitis is defined as marked increase in aminotraserferases coinciding with hepatocellular necrosis (38), these findings is compatible with histopathological changes that found in the rats of both treated groups which represented necrosis, Pyknosis and disappearance of hepatocyte nuclei, and confirmed with increases of the aminotraseferases serum activity . Hepatocyte stress and or/damage could result in the release of signals that stimulate activation of other cells , particularly that of innate immune system including kupffer cells (KC),natural killer (NK)cells, These cells contribute to the progression of liver injury by producing proinflammatory cytokines , such as tumor necrosis factor (TNF)- α , interferon (IFN)- γ and interleukin(IL) IB produced during DILI are involved in

promoting tissue damage (39,40,41). We are also found there was activation of kupffer cells especially in the liver of rats treated with 1mg/kg.BW oseltamivir for six weeks.

We suppose that the inflammatory reaction(neutrophils and mononuclear cells infiltration, suppurative exudates) in the liver caused by oseltamivir dosed to the rats has an important role of its hepatotoxic effect, science Michael (38) found the damaged hepatocytes triggers the activation of the other cells ,which can initiate an inflammatory reaction and /or adaptive immune response .These secondary events may overwhelm the capacity of the liver for adaptive repair and regeneration , there by contributing to the pathogenesis of liver injury. The toxicities of oseltamivir phosphate to the rat liver were mild and considered of slightly increase in liver weigh,and plasma activity of glucose .chlesterol,total blood protein(34).These findings is not in agreement with present results of significant increase in cholesterol, blood glucose and total serum protein .

Table (1):-Barbiturate (Thiopental sodium) sleeping time /minute in rats dosed therapeutic dose 1mg/kg.BW of Oseltamivir for different experimental periods.

Group	Onset		Duration	
	Pretreatment	Post-treatment With oseltamivir	Pretreatment	Post-treatment With oseltamivir
	M±SE	M±SE	M±SE	M±SE
T1 N=6	5.50 ±0.92 A a	3.33±0.55 A a	47.50±3.81 A a	48.33±6.01 Aa
T2 N=6	4.83±0.98 Aa	33.33±11.15 B b	56.33±8.02 A a	23.66±5.42 B b
C N=6	6.60±2.33 Aa	6.66±2.15 Aa	55.83±8.50 A a	55.60±8.20 Aa

-T1=therapeutic dose 1mg/kg.BWof oseltamivir for one week.

-T2=therapeutic dose 1mg/kg.BW of oseltamivir for six weeks.C= dosed distilled water.

N=number of rats.

-The different capital letters mean the difference is significant between groups at activity $P \leq 0.05$.

- The differentsmall letters mean the difference is significant within group groups at activity $P \leq 0.05$.

Table (2):- The serum activity of liver enzymes (ALT , AST ,ALP) U/L in rats dosed orally therapeutic dose 1mg/kg.BW of oseltamivir for different experimental periods.

Group	ALT U/L	AST U/L	ALP U/L
	M ± SE	M ± SE	M ± SE
T1 N=6	9.16±0.70A	7.83± 0.40A	120.50± 32.18 A
T2 N=6	50.00±1.89B	113.33±3.80B	78.16±12.18B
C N=6	18.8±1.35C	10.60±1.77A	2.73 ± 34.40C

- T1=therapeutic dose 1mg/kg.BWof oseltamivir for one week.

-T2=therapeutic dose 1mg/kg.BW of oseltamivir for six weeks.

-C= control dosed distilled water.

N=number of rats

-The capital letters mean the difference is significant between groups at activity $P \leq 0.05$.

Table(3):- Random blood sugar mg/dL of rats dosed orally therapeutic dose 1mg/kg.BW of oseltamivir for different experimental periods .

Group	Blood glucose mg/dL		
	M	±	SE
T1 N=6	139.00 A	±	18.06
T2 N=6	98.50 B	±	6.94
C N=6	132.40 A	±	6.82

- T1=therapeutic dose 1mg/kg.BW of oseltamivir for one week.
- T2=therapeutic dose 1mg/kg.BW of oseltamivir for six weeks.
- C= control dosed distilled water.
- N= number of rats
- The capital letters mean the difference is significant between groups at activity $P \leq 0.05$.

Table(4):-The serum cholesterol mg/dL and triacylglycerol mg/dL of rats dosed orally therapeutic dose 1mg/kg.BW of oseltamivir for different experimental periods.

Group	Cholesterol(mg/dL)			Triacylglycerol mg/dL		
	M	±	SE	M	±	SE
T1 N=6	93.16 A	±	2.45	56.50 A	±	10.23
T2 N=6	125.50 B	±	10.42	320.66 B	±	11.36
C N=6	91.18 A	±	6.28	30.84 C	±	3.75

- T1=therapeutic dose 1mg/kg.BW of oseltamivir for one week.
- T2=therapeutic dose 1mg/kg.BW of oseltamivir for six weeks
- . -C= control dosed distilled water.
- N=number of rats.
- The capital letters mean the difference is significant between groups at activity $P \leq 0.05$.

Table(5):- The serum HDL (mg/dL) , LDL (mg/dL) and VLDL (mg/dL) of rats dosed orally therapeutic dose 1mg/kg.BW of oseltamivir for different experimental periods.

Group	HDL mg/dL	LDL mg/dL	VLDL mg/dL
	M ± SE	M ± SE	M ± SE
T1 N=6	27.00±2.86 A	64.90±6.97 A	5.43±0.55 A
T2 N=6	45.50± 7.20 B	30.66±13.04 B	63.66± 0.61 B
C N=6	40.50±2.68 B	73.64±4.93 A	6.14± 0.75 A

- T1=therapeutic dose 1mg/kg.BW of oseltamivir for one week.
- T2=therapeutic dose 1mg/kg.BW of oseltamivir for six weeks. .
- C= control dosed distilled water.
- N=number of rats.
- The capital letters mean the difference is significant between groups at activity $P \leq 0.05$.

Table (6):- The total serum protein (mg/dL) of rats dosed orally therapeutic dose 1mg/kg.BW of oseltamivir for different experimental periods.

Group	Serum protein mg/dL		
	M	±	SE
T1 N=6	278.66	±	9.10 A
T2 N=6	620.00	±	18.38 B
C N=6	327.40	±	40.29 A

- T1=therapeutic dose 1mg/kg.BW of oseltamivir for one week.

-T2=therapeutic dose 1mg/kg.BW of oseltamivir for six weeks.

-C= control dosed distilled water.

N=number of rats.

-The capital letters mean the difference is significant between groups at activity $P \leq 0.05$.

Table (7):- The total serum bilirubin (TSB mg/dL), direct serum bilirubin mg/dL and indirect serum bilirubin mg/dL of rats dosed orally therapeutic dose 1mg/kg.BW of oseltamivir for different experimental periods .

Group	T.S.B(mg/dL)			Direct serum bilirubin(mg/dL)			Indirect serum bilirubin(mg/dL)		
	M	±	SE	M	±	SE	M	±	SE
T1 N=6	3.08	±	0.32 A	2.73	±	0.21 A	0.35	±	0.10 A
T2 N=6	1.15	±	0.17 B	0.66	±	0.17 B	0.33	±	0.14 A
C N=6	3.68	±	0.66 A	0.74	±	0.15 B	2.90	±	0.64 B

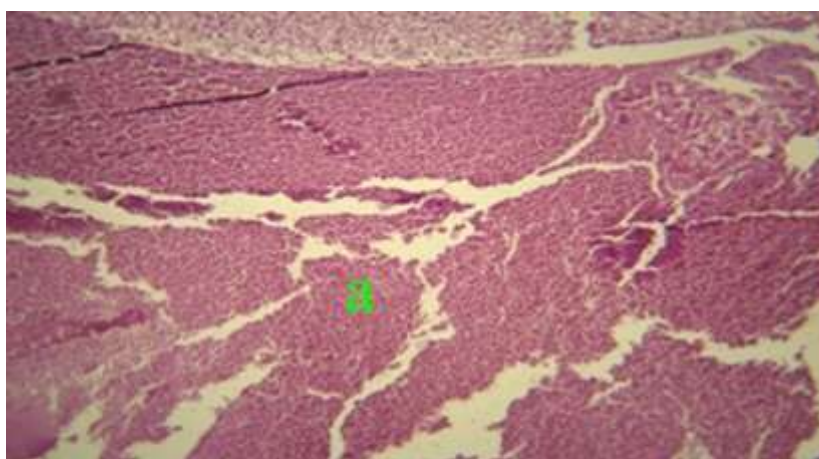
- T1=therapeutic dose 1mg/kg.BW of oseltamivir for one week.

-T2=therapeutic dose 1mg/kg.BW of oseltamivir for six weeks.

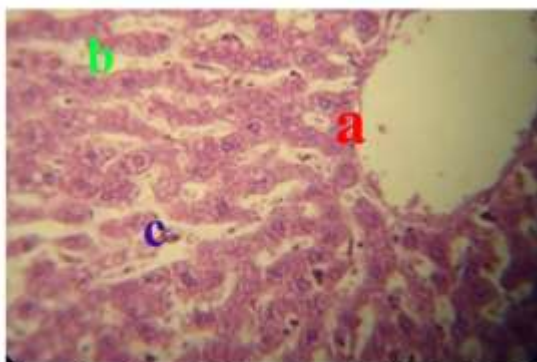
-C= control dosed distilled water.

N=number of rats.

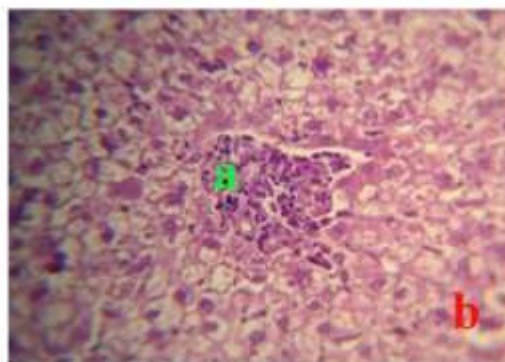
-The capital letters mean the difference is significant between groups at activity $P \leq 0.05$.



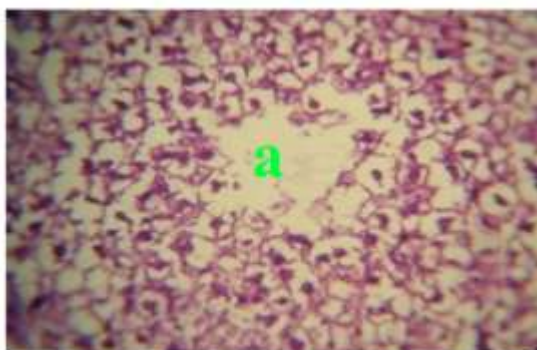
Figure(1):-Liver of the rat treated with 1mg/kg.BW of oseltamivir for one week shows deposition of suppurative exudates contain large numbers of neutrophils in the pre-hepatic area (a) (H&E 400X).



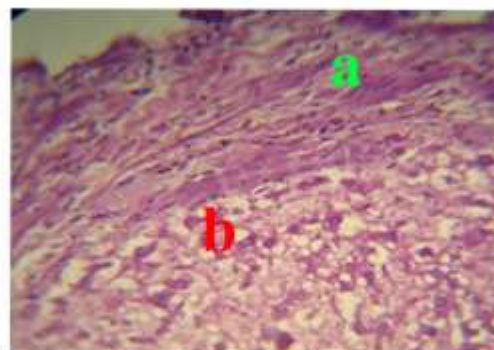
Figure(2) :- Liver of the rat treated with 1mg/kg.BW of oseltamivir for one week shows severe dilation and congestion of central vein (a), and sinusoid(b)with activation of kupffer cells (c) (H&E 400X).



Figure(3):-Liver of the rat treated with 1mg/kg.BW of oseltamivir for one week shows focal infiltration of mononuclear cells in the hepatic parenchyma (a) with vacuolation of hepatocytes (b) (H&E 400).



Figure(4):- Liver of rat treated with 1mg/kg.BW of oseltamivir for six weeks shows focal necrosis characterized by pyknosis or disappearance of nuclei of hepatic cells (a) (H&E 400X) 400X).



Figure(5):- Liver of rat treated with 1mg/kg. BW of oseltamivir for six weeks shows fibrous thickening of the Glisson capsule (a) with vacuolar degeneration of hepatic parenchyma (b) (H&E400X).

References

- 1-McNicholl, IR.andMcNicholl, JJ.(2001). Neuraminidase inhibitors: zanamivir and oseltamivir. *Ann.Pharmacother.*, 35: 57-70.
- 2-Bardsley-Elliot, A. and Noble, S.(1999).Oseltamivir.*Drugs*, 58:851–860.
- 3-Shi, D.; Yang, J.; Yang, D.;LeCluyse, EL.; Black, C.; You, L.;Akhlaghi, F. and Yan, B. (2006).Anti-influenza prodrugoseltamivir is activated by carboxylesterase human carboxylesterase 1 and the activation is inhibited by antiplatelet agent clopidogrel. *J.Pharmacol. Exp.Ther.*,319:1477–1484.
- 4-He, G.(1999).Clinical pharmacokinetics of the prodrugoseltamivirand its active metabolite Ro 64-0802.*Clin.Pharmacokinet.*,37: 471-484.
- 5-Roche Laboratories Inc. Tamiflu (oseltamivir phosphate): capsules and oral suspension prescribing information for the US.www.rocheusa.com.
- 6-Wood,ND.; Aitken, M.; Sharp, S. andEvison, H.(1997).Tolerability and pharmacokinetics of the influenza neuraminidase inhibitor Ro-64-0802 (GS4071) following oral administration of the prodrug Ro-64-0796 (GS4104) to health male volunteers. 37th ICAAC., (Toronto,1997) .
- 7- Roche Pharmaceuticals Laboratories. Tamiflu package insert (Oct27, 1999).
- 8-Jones,AL. (1999).Anatomy of the normal liver .In: *Hepatology , a text book of liver disease* .Zakin D,Boyer TD , Eds,3rded , Pheladelphia , WB Saunders,Pp: 3-32.
- 9-Ostapowicz, G.; Fontana, PJ.andSchiodt, Fr. (2002).Results of a prospective study of acute liver failure at 17 tertiary cure Centers in the United States.*Ann. Intern.Med.*, 137: 947-954.

- 10- Zimmerman, HJ. (1999). Drug –induced liver disease In: The adverse effects of drugs and other chemicals on the Liver Zimmerman HJ ed. Hepatotoxicity: 2nd ed. Philadelphia, PA Lippincott William and Wilkins, Pp:427-456.
- 11- Hafez, ES. (1970). Reproduction and breeding techniques for laboratory animals. Lea and Febiger, Philadelphia.
- 12- Ferrini, R.; Miragoli, G. and Taccardi, B. (1974). Neuropharmacological studies on SB 5833 a new psychotherapeutic agent of the benzodiazepine class. *Arzneim-Forsch*, 24: 2029.
- 13- Luna, LG. (1968). Manual of histology staining methods of Armed forces Institute of Pathology, 3rd ed McGraw Hill Book Co New York, Pp:7-9.
- 14- Trinder, P, *Ann. Clin. Biochem*, 16 24 (1969).
- 15- Richmond. *Clin. Chem*, 19 1350 (1973) .
- 16- Fasce, CF. *Clin. Chem*, 18 901 (1982).
- 17- TIETZ, NW. (1999). Text book of clinical chemistry 3rd ed. CA Burtis E R Ashwood W B Saunders, Pp:809 – 857 .
- 18- Burstein, M. (1970). Lipid Res 11 583 Study group European Atherosclerosis Society. *Eur. heart J.*, 1988 .
- 19- ARCOL ISB . (1989). 15 , 121 – 124).
- 20- Young, DS. (2000). Effect of drugs on clinical laboratory tests. 5th ed P:46. Youra A Teel R W Stoner M (2007). Ellagic acid action against bacteria infection of H pylori and antibacterial mechanism. *Med. J.*, 30:329-336.
- 21- Joda, M. (2008) . The progressive statistical analysis by using SPSS 1st edit Churhill livingstone Edinburgh, Pp:109-112.
- 22- Parkinson, A. (2001). Biotransformation of xenobiotics In: Casarett and Doull's Toxicology. The Basic Science of poisoning (Klassen .CD ed) McGraw Componies New York, Pp:139-162 .
- 23- Jian, Y.; Deshi, S.; Dong fang, Y.; Xiulong, S. and Binfang, Y. (2007). Interleukin-6 alters the cellular responsiveness to clopidogrel, irinotecan and oseltamivir by suppressing the expression of carboxylesterases HCE1 and HCE2. *Mol. Pharm.*, 72 (3):686-694.
- 24- Musa, TY.; Lawal, SB.; Mansur, L. and Musban, AA. (2003). Evaluation of selected parameters of rat liver and kidney function following repeated administration of yohimbine. *Biochm.*, 15 (2): 50-56.
- 25- Thapa, BR. and Walia, O. (2007). Liver function tests and their interpretation. *Indian J. pediatr.*, 74(7):663-671.
- 26- Friedman, SF., Martin, P. and Manoz, JS. (2003). Laboratory evaluation of the patient with liver disease. In: *Histopathology a text book of liver disease*. Philadelphia, Saunders Publication. 1, Pp: 661-709.
- 27- Rosalk, SB. and McIntyre, N. (1999). Biochemical investigations in the management of liver disease Oxford text book of clinical hepatology 2nd ed. New York, Oxford University press. Pp: 503-521.
- 28- Sherry, FQ. (2005). Systemic and CNS toxicities of antimicrobial agents In: The principals of Neurologic infectious diseases. Kuren, L. Roos. McGraw Hill, Pp: 497-508.
- 29- Wael, ME. and Mohamed, A. (2011). Potential adverse effects of oseltamivir in rats male are more vulnerable than females. *Can. J. Physiol. Pharmacol.*, 23 (218):611-687.
- 30- Shin- Hung, T.; Yen-Yuelin, C.; Wang Hsu, C.; Shang, C. and Der-Ming, C. (2011). Hypoglycemia revisited in the acute care setting. *Yonsei Med. J.*, 52 (6): 898-908.
- 31- Emma, L. (2009). Cholesterol Lipidomics Gateway. *Doi.*, 10:1038.
- 32- Jhon, S.; Sorokin, AV. and Thompson, D. (2007). Phytosterol and vascular diseases. *Curr. Opin. Lipidol.*, 18(1): 35-40.
- 33- Mead, JR.; Irvine, SA. and Ramji, DP. (2002). Lipoprotein lipase structure function, regulation and role in disease. *J. Mol. Med.*, 80 (12): 753-69.

- 34-Farrelly,J. (2001). Pharmacologists' Review In: Center for drug evaluation and research. Application Number, 21-246.Pp:1-18.
- 35-Daniel,SP.and Marshal, MK.(1999).Evaluation of the liver: Laboratory tests .Schiff's diseases of the liver 8thedUSA JB Lippincott publication :20-239.
- 36-Daniel, SP.and Marshal, MK.(2007). Laboratory tests In: Schiff's diseases of the liver 10thedVol 1 Eugene RS Michal FS Willis CM . Lippincott Wilkins 19-24.
- 37-Larry, D. (2000).Drug- induced liver diseases. J.Hepatol., 32: 77-88.
- 38-Michael, PH. and Cynthia, JA.(2006).Mechanism of drug-induced liver injury.The AAPs. J.8(1): 48- 54.
- 39-Balazka, ME.; Wilmer, JL.; Holiday,SD.; Wilson ,RE.and Luster,ML.(1995).Role of proinflammatory Cytokines in acetaminophen hepatotoxicity Toxicol App 1 Pharmacol. , 133; 43-52.
- 40-Balazka, ME., Elwell, MR., Holiday, SD., Wilson ,RE.and Luster, ML. (1996). Histology of acetaminophen induced liver changes: role of interleukin 1 alpha and tumor necrosis factor alpha.Toxicol.pathol., 24:181-189.
- 41-Ishida, Y.;Konda, T.;Oshina, T.;Fujiwara, H.;Iwakura, Y. andMukaida, N. (2002).A pivotal involvement of IFN-gamma in the pathogenesis of acetaminophen –induced acute liver injury.FASEB.J.16: 1227-1236.