

Evaluate the effect of different doses for grape seed extract in mice

Sanaa Kudair A .AL.Jeboory, Eman H.Y.Al Taae and Rajiha A. AL. Naimi

Department of pathology - College of Veterinary Medicine / Baghdad University- Iraq

Accepted:15/11/2011

Summary

The aim of this study was to evaluate the effect of different doses for grape seeds extract in internal organs of mice. Histopathological, cytogenetical and haematological studies were done to evaluate this effect. The study was done on (24) mice divided into four groups (6/group) for one month. Group one treated with PBS considered as control Negative, Group two treated with (100mg/kg B.W.) of grape seed extract, Group three treated with (200mg/kg B.W.) of grape seed extract, Group four treated with (300mg/kg B.W.) of grape seed extract. The results showed that (200, 300mg/kg B.W.) cause significant decrease in hematological, cytogenetical parameters and severe histopathological changes while at dose (100mg/kg B.W.) induce immune pathological response organ with amelioration of haematological and cytogenetical parameters. In conclusion the effect of grape seed extract was dose dependent that more severe toxicopathological changes appeared in haematological, cytogenetical and histopathological results at doses (200 and 300mg/kg B.W.) while at dose (100mg/kg B.W.) induce immunopathological response internal organs with amelioration of haematological and cytogenetical parameters.

Key words: Grape, toxicity, grape seed, Mice.

تقييم التأثير العلاجي بجرعات مختلفة لخلصة بذور العنب في الفئران
سنا خضير كعص الجبوري * ايمان هاشم يوسف الطائي * راجحة عبد الستار النعيمي *

*فرع الامراض- كلية الطب البيطري/جامعة بغداد /العراق

الخلاصة

هدفت الدراسة الى تقييم التأثير العلاجي بجرعات مختلفة لخلصة بذور العنب على التغيرات المرضية النسجية والوراثة الخلوية والدموية . استخدمت في الدراسة (24) فأر قسمت الى(4) مجاميع احتوت على اعداد متساوية من الحيوانات وعولجت لمدة شهر وكما يلي: مجموعة (1) اعطيت PBS واعتبرت مجموعة سيطرة, مجموعة (2) اعطيت (100mg/kg B.W.) من خلاصة بذور العنب, مجموعة (3) اعطيت (200mg/kg B.W.) من خلاصة بذور العنب , مجموعة (4) اعطيت (300mg/kg B.W.) من خلاصة بذور العنب. اظهرت النتائج ان الجرعة (200,300) قد سببت نقصان معنوي في المقاييس الدموية والوراثة الخلوية مع حدوث تغيرات مرضية نسجية شديدة في الانسجة اما عند اعطاء جرعة (100) فقد اظهرت الحيوانات تحسنا في نفس المعايير المذكورة اعلاه واستجابة مناعية لانسجة الاعضاء الداخلية . نستنتج مما سبق ان تأثير مستخلص بذور العنب يعتمد على الجرعة المعطاة من التغيرات الدموية والوراثة الخلوية والمرضية النسجية.

الكلمات المفتاحية : سمية بذور العنب , المركبات السامة لبذور العنب , تأثير بذور العنب.

Introduction

Grape is one of the most commonly consumed fruits in the world. It has various biological functions due to its rich polyphenol ingredients, (1). Grape seed extract is the primary commercial source of group of powerful antioxidants known as oligomeric

proanthocyanidins (OPCs). Also generically called pycnogenol, a class of flavonoids (2). Proanthocyanidin, a type of polyphenol is found abundantly in grape seed extract and has anti-inflammatory, anti-arthritic and anti-allergic properties. Grape seed extract had antioxidant and free radical scavenging activity. Flavonoids found in red wine have been reported to protect the heart by inhibiting the oxidation of LDL "bad" cholesterol (LDL oxidation which can lead to hardening of the arteries or atherosclerosis) (3). According to our knowledge there is few researches about the effect of different doses for grape seed on internal organs (lung, liver, kidney, spleen, heart and brain) so the present work accomplished this task.

Materials and Methods

Local grapes cultivated in Iraq were collected from the local market and classified as *Vitis vinifera* by the herbarium of the Biology Department, College of Science, Baghdad University. Shed and dried at room temperature. A voucher specimen of the plant was deposited to be identified and authenticated at the National Herbarium of Iraq Botany Directorate in Abu-Ghraib (Certificate number (199) in (19/01/2011). plant was (*Vitis vinifera*), a member of the family (Vitaceae) genus (*Vitis*) species (*Vinifera*), according to certificate. According to (4) the ethanolic extract of plant was prepared as follows:-1- aliquots of 50 gm of the powdered seed of plant were suspended in 250 ml of 70% ethanol alcohol in Erlenmeyer flask and stirred on cold magnetic stirrer overnight.2-After 72hr., the sediments were filtered by gauze and then by filter paper.3-Steps (1) and (2) were repeated 4-5 times.4-The pooled extract was dryness y oven 40 °C.5-The weight of yield resulted from that amount of powdered plant was measured.6-The yield was kept at -20°C until the time of use. For following experiments, 3.5 gm of powdered plant extract was dissolved into 100 ml PBS (as solvent),the suspension then filtered and sterilized by using 0.4mm sterile Millipore filter and kept in deep freeze (-20 °C) until use.

Hematology was determined as following according to the (5). Test was performed by using of hemoglobin kit (Drapkin's reagent) then uses 5 ml of Drapkin's with 20 µl of blood, left for 5 min then read on 540 nm. Packed cell volume was measured by using micro-hemocrit capillary tubes. Haymes solution was used to dilute the blood for counting RBCs by hemocytometer method. Thoma's solution was used to dilute blood to count WBCs by hemocytometer method as mentioned before in RBCs counting, but here the only difference was the type of pipette.

One drop of blood was dripped on a slide to differential Counting of WBCs (%) then this drop was spread with one stroke and after getting dried, the slide was dyed with Wright giemsa stain and left for 10 minutes then washed with tap water. The slide was examined under a microscope.

Ammonium oxalate solution was used to dilute blood to count platelet ($\times 10^6$ cell/ L) by hemocytometer method. Cytogenetical was determined as following according to the (6). After the bone was washed, both ends of bones were cutting and the bone holding vertically above test tube, 5 ml at 37°C sterile PBS injected in bone and collected in test tube. Cell suspension mixed with 1ml of colchicin for about 10 minutes and then the tube was put in incubator at 37°C. The tubes centrifuged which contain bone marrow at 2000 rpm for 10 minute. The suspension was with draws and the sediments mixed very well and then 10 ml of 37°C KCl was added gently at the beginning and incubated for about 40 minutes. After that tubes centrifuge at 2000 rpm for 10 minute and withdraw the suspension, the sediments mixed well and fixed by fresh glacial acetic acid: methanol (1:3 v/v) (5ml). Then centrifuge at 2000 rpm for 10 minutes, the washing process return for 6 hours and then the

sediment suspend in 1-2 ml. The suspension mixed by pipette and then dropped the suspension on oil free slide at distance (30-50cm) and the slides were left to dry. The slide stained by giemsa stain for about (15) minute and then after dry, the slides were examined under light microscope. LD50 of grape seed extract was determined as following according to the Dixon (7).

The study involves 24 mice which were divided in to 4 groups each group contains 6 animals treated as following: 1- Group one: gavage orally by stomach tube with PBS 4 time/ week this group considered as control negative. 2- Group two: gavage orally by stomach tube 4 time/week 100 mg /kg .B.W. grape seed extract for 4 weeks .3- Group three: gavage orally by stomach tube 4 time/week 200 mg /kg .B.W. grape seed extract for 4 weeks. 4- Group four: gavage orally by stomach tube 4 time/week 300 mg /kg .B.W. grape seed extract for 4 weeks.

Histopathology According to the (8), the animals were sacrificed and postmortem examination done. Specimens were taken from all internal organs; the tissues have been kept in 10% formalin immediately after removal. After 48 hours then tissue sections were embedded in paraffin blocks, and sectioned by microtome at 5 μ m. All tissues were stained with hematoxylin and eosin stain and the histopathological changes were examined under light microscope.

Statistical analysis of data was performed by using Statistical Package for Social Science, (9) Version 16, and for determination of significant differences using ANOVA one way and two way. Group differences were determined using least significant difference (LSD) test at $P < 0.05$ (9).

Results and Discussion

The calculated LD50 for grape seed extract was 2000mg /kg. B.W.

Haematological effect of grape seed extracts: The result of Hb (mg/dl) is shown in (Table 1). The result of group treated with grape seed at dose (100mg/kg B.W. orally) Hb was (14.10 \pm 0.27) showed increase in Hb values when compared with control group which Hb was (13.50 \pm 0.10). In addition the result showed significant decrease ($p < 0.05$) in Hb values in groups treated with ethanolic extract at dose (200, 300mg/kg B.W. orally) Hb was (11.30 \pm 0.19, 11.10 \pm 0.15) when compared with control group which Hb was (13.50 \pm 0.10).

The result of P.C.V (%) are listed in (Table 1). There were increase of P.C.V (%) in group treated with ethanolic extract of grape seed at dose (100mg/kg B.W. orally) P.C.V was (45.00 \pm 0.51) when compared with group control which P.C.V was (43.67 \pm 0.33). In addition the result in groups treated with grape seed at dose (200 and 300mg/kg B.W. orally) P.C.V was (36.67 \pm 0.88, 36.00 \pm 0.32) showed significant decrease ($p < 0.05$) in P.C.V (%) when compared with control group which P.C.V was (43.67 \pm 0.33).

The data of RBCs count are shown in (Table 1). The group treated with grape seed at dose (100mg/kg B.W. orally) RBCs was (6.3 $\times 10^6 \pm 0.08165$) showed increase in RBCs count but no significant difference when compared with control group which RBCs was (5.6 $\times 10^6 \pm 0.04082$). In another way the result of this study showed significant decrease ($p < 0.05$) of RBCs count in group treated with grape seed at dose (200 and 300mg/kg B.W. orally) RBCs was (4.4 $\times 10^6 \pm 0.09082$, 3.6 $\times 10^6 \pm 0.0505$) when compared with control group which RBCs was (5.6 $\times 10^6 \pm 0.04082$)

The data of WBCs count are shown in (Table1). The results showed increase in WBCs count but no significant difference of group treated with grape seed at dose (100mg/kg B.W. orally) was (7.1 $\times 10^3 \pm 0.07743$) when compared with control group which

WBCs was $(6.6 \pm 0.1 \times 10^3 \pm 1547)$. In another way the result of group treated with grape seed at dose (200 and 300mg/kg B.W. orally reached $(5.3 \times 10^3 \pm 0.05132, 5.00 \times 10^3 \pm 0.3333)$ showed decrease in WBCs count but no significant difference when compared with control group which WBCs was $(6.6 \times 10^3 \pm 0.11547)$.

The data of platelet count are explained in table (1). Group treated with grape seed at dose (100mg/kg B.W. orally) was $(9.8 \times 10^4 \pm 0.77451)$ showed increase in Platelet count but no significant difference when compared with control group which platelet was $(9.5 \times 10^4 \pm 0.11536)$. In another way platelet count showed significant decrease ($p < 0.05$) in groups treated with grape seed at dose (200 and 300mg/kg B.W. orally) was $(5.4 \times 10^4 \pm 0.05513$ and $5.1 \times 10^4 \pm 0.11000)$ when compared with control group which platelet was $(9.5 \times 10^4 \pm 0.11536)$.

The result of differential count are listed in (Table 1). The study showed increase in numbers of lymphocyte (%) in group treated with ethanolic extract of grape seed at dose (100mg/kg B.W. orally) was (62.00 ± 1.50) when compared with control group which lymphocytes was (61.67 ± 1.40) . In addition the result of groups treated with grape seed at dose (200,300mg/kg B.W. orally) was $(38.00 \pm 0.58, 30.45 \pm 0.29)$ showed significant decrease ($p < 0.05$) when compared with control group which lymphocytes was (61.67 ± 1.40) .

The result of group treated with grape seed at dose (100mg/kg B.W. orally) was (33.00 ± 1.53) showed increase in numbers of neutrophils (%) compared with control group which neutrophils was (32.00 ± 0.36) . In another way the result showed significant increase ($p < 0.05$) in numbers of neutrophils (%) in groups treated with grape seed at dose (200 and 300mg/kg B.W. orally) was $(58.00 \pm 0.58$ and $66.55 \pm 0.27)$ when compared with control group which neutrophils was (32.00 ± 0.36) .

The study showed no significant difference of group treated with grape seed at dose (100mg/kg B.W. orally) eosinophils count was (2.00 ± 0.30) when compared with control group which was (2.33 ± 0.33) . In addition the result of groups treated with grape seed at dose (200 and 300mg/kg B.W. orally) showed increase was $(1.67 \pm 0.19$ and $1.55 \pm 0.27)$ when compared with control group which eosinophils was (2.33 ± 0.33) .

The result showed decrease in numbers of monocytes of group treated with grape seed at dose (100mg/kg B.W. orally) was (3.00 ± 0.40) when compared with control group which monocytes was (4.00 ± 0.47) . In addition the result of group treated with grape seed at dose (200 and 300mg/kg B.W. orally) showed significant decrease ($p < 0.05$) was $(2.33 \pm 0.21$ and $2.00 \pm 0.50)$ when compared with control group which monocytes was (4.00 ± 0.47) .

Table (1) The result (mean ± SE) of some Haematological parameter (HB (g/dl), pcv%, WBC (dl), RBC (dl), Platelet (dl) and differential count (%).

Groups Parameter	Control (-)	Treated with plant at dose (100mg/kg B.W. orally)	Treated with plant at dose (200mg/kg B.W. orally)	Treated with plant at dose (300mg/kg B.W. orally)
HB	13.50±0.10 A	14.10±0.27 A	11.30±0.19 B	11.10±0.15 B
P.C.V%	43.67±0.33 A	45.00±0.51 A	36.67±0.88 C	36.00±0.32 C
RBCs	5.6±0.04082 A	6.3±0.08165 A	4.4±0.09082 B	3.6±0.32 B
WBCs	6.6±0.11547 A	7.1±0.07743 A	5.3±0.05132AB	5.00±0.33333AB
Platelet	9.5±0.11536 A	9.8±0.77451 A	5.4±0.05513 B	5.1±0.11000 B
Differential count Lymphocyte	61.67± 1.40 A	62.00± 1.50 A	38.00± 0.58 B	30.45 ± 0.29 B
Neutrophil	32.00 ± 0.36 D	33.00 ± 1.53 D	58.00 ± 0.58 B	66.00 ± 0.27 B
Eosinophil	2.33 ±0.33 A	2.00 ±0.30 A	2.67± 0.19 A	2.55 ± 0.27 A
Basophile	-	-	-	-
Monocyte	4.00±0.47 A	3.00±0.40 A	1.33±0.21 B	1.00±0.50 B

Different letters means significant ($p < 0.05$) between groups

The present study found that treatment of grape seed extract at dose (100mg/kg B.W. orally) significantly improved the hematological parameters compared with animals treated at dose (200,300mg/kg B,W orally) these beneficial effect of grape seed extract on these parameters probably add to the long list of known pharmacological actions of grape seed extract that have been recorded by author (10) due to chemical structure(s) are mainly responsible for the antioxidant activities of grape extracts.

In another way the results demonstrated grape seed extract at dose (200 and 300mg/kg B.W. orally) induced a significant decrease in erythrocyte and leukocytes count, hematocrit, platelet count and lymphocyte percentage may be due to inhibition or defective hematopoiesis, these findings are agreed with those obtained from other studies (11and12), a prolonged prothrombin time is indicative of abnormalities of factors V, VII or X, prothrombin, fibrinogen or due to the presence of an inhibitor (13).

Cytogenetics effect of grape seed extracts on bone marrow: Mitotic and Blast Index

The data of table (2) explain the effect of ethanolic extract of grape seed on MI in group treated with grape seed at dose (100mg/kg B.W. orally) was (16.1±0.4) showed significant increase ($p < 0.05$) in MI when compared with control group which MI was (14.0±0.1). While groups treated at dose (200 and 300mg/kg B.W. orally) was (13.2±0.1and 12.1±0.4) showed significant decrease ($p < 0.05$) in MI when compared with control group which MI was (14.0±0.1). The result showed significant increase ($p < 0.05$) in BI value in all groups treated with ethanolic extract of grape seed at dose (100, 200 and 300mg/kg B.W.

orally) was (38.33±0.8, 32.67±0.3 and 29.33±0.2) when compared with control group which BI was (27.33±0.1).

Table (2) showing (mean ± Se) the effect of grape seed extract on mitotic and blast index.

groups \ Test	MI*	BI**
Control (-)	0. 14.0±0.1C	27.33±0.1 D
Treatment with plant at dose (100mg/kg B.W. orally)	16.1±0.4 A	38.33±0.8 A
Treatment with plant at dose (200mg/kg B.W. orally)	13.2±0.1 AB	32.67±0.3 B
Treatment with plant at dose (300mg/kg B.W. orally)	12.1±0.4 B	29 29.33±0.2 C

*MI=Mitotic index ** BI =Blast index

Different capital letters means significant ($p<0.05$) results between weeks, L.S.D=1.03

The results with treated with grape seed extract at dose (100mg/kg B.W. orally) showed significant increase in mitotic index and blastic index and this agreement with (14).The grape seed contain flavonoids, catechin was one of active constituents of grape seed, stimulated the proliferation of mouse bone marrow cells (15). While result treated with grape seed extract at dose (200 and 300mg/kg B.W. orally) showed decrease gradually in mitotic index and blastic index and this agreement with (16) who showed that the higher doses affected the mitotic process in the normal lymphocyte but the chromosomal changes might be intacted. When mice were given grape seed extract in their diet at different doses, they had better contact hypersensitivity response and less immunosuppression (16).

Pathological Study:

Control group: There are no clear macroscopic findings.

Pathology of organs in healthy female mice treated with ethanolic extract of grape seed at dose (100mg/kg B.W. orally).

Brain: Histopathological lesion of brain showed focal aggregation of microglial cells (gliosis) forming nodular like structure (fig1). Lung: Histopathological changes showing perivascular and peribronchiolar lymphocytic cuffing (fig2). Heart: Histopathological changes characterized by marked hyperplasia of lymphoid tissue of pericardial adipose tissue. Liver: Histopathological lesion showing proliferation of kupffer cells with infiltration of lymphocytes within the dilated sinusoids. Other sections showed formation of early granuloma within hepatic parenchyma consisting of mononuclear cells aggregation (3). Kidneys: Histopathological changes showing perivascular lymphocytic cuffing in the interstitial blood vessels (fig4). Spleen: Histopathological changes characterized by marked hyperplasia of lymphoid tissue in white pulp (fig5). Pancreas: Histopathological lesion for pancreas was marked by hyperplasia of islets of langerhans (fig6). In addition to hyperplasia of lymphoid tissue of the organ. Stomach: Histopathological changes showing in non-glandular region showed no pathological changes. While the glandular region was undergoing focal infiltration of mononuclear cells in the mucosa (fig7). Intestine: Histopathological lesion showing there is extensive hyperplasia of lymphoid tissue (fig8). Bone marrow: Histopathological charactersize moderate hyperplasia of hemopoietic tissue with increase in numbers of megakaryocytes(fig9).

Pathology of organs in healthy female mice treated with ethanolic extract of grape seed at dose (200mg/kg B.W. orally).

Brain: Histopathological lesion for brain showing severe congestion of blood vessels of cerebral and cerebellar meninges (fig 10). In addition perineuronal and perivascular edema of cerebrum. Lung: Histopathological section showed hemorrhage, congestion of alveolar blood capillaries and pulmonary blood vessels with pneumonic area. Heart: Histopathological changes showing marked fibrosis of myocardium with infiltration of mononuclear cells (fig 11). Liver: Histopathological characterize there is extensive areas of necrosis and apoptosis (fig22). Infiltration of mononuclear cells in the portal areas. Kidney: Histopathological lesions showing severe necrosis of epithelial lining of proximal and distal convoluted tubules (fig 12). Spleen: Histopathological changes showing deposition of small amount of amyloid like substance with deposition of hemosiderin pigment. Stomach: Histopathological lesion showing non-glandular region showed marked hyperplasia and hyperkeratosis of mucosa (fig213). Intestine: Histopathological lesion showing infiltration of mononuclear cells in mucosa with slight fibrosis. Pancreas: Histopathological characterize tissue section showed extensive necrosis of pancreatic acini and islet of Langerhans (fig 14). Bone marrow: Histopathological changes showing depletion of hemopoietic tissue with increase in numbers of blood sinuses.

Pathology of organs in healthy female mice treated with ethanolic extract of grape seed at dose (300mg/k B.W. orally).

In addition to previous histopathological changes seen in treated group with grape seed extract. There are the following changes: Brain: Histopathological lesion showing shrinkage of neurons (dark blue), edema of the cerebrum. The cerebellum showed edema between the molecular and granular layer with degeneration of numerous purkinji cells and complete dissolution of the others (fig 16). Lung: Histopathological sections showed sever hemorrhage, congestion of alveolar blood capillaries and pulmonary blood vessels with large pneumonic area. Heart: Histopathological changes showing sever lesion that there is wide areas of fibrosis of myocardium with highly infiltration of mononuclear cells. Liver: Histopathological characterized hyperplasia intrahepatic bile ducts forming papillary projection (fig 17). Kidney: Histopathological lesion showing severe periglomerular infiltration of inflammatory cells mainly mononuclear cells (18A) with cystic dilation of renal tubules containing hyaline cast fig (18B). Spleen: Histopathological changes showing increase in amount of amyloid like substance leading to pressure atrophy of lymphoid tissue with deposition of hemosiderin pigment (fig 19). Pancreas: Histopathological characterized the main microscopic changes were the infiltration of mononuclear cells around pancreatic duct with slight fibrosis (fig20). Stomach: Histopathological lesion for stomach showing extensive fibrosis of mucosa leaving only few mucous glands. Intestine: Histopathological changes showing similar pathological changes as seen in the previous period of treatment. Bone marrow: Histopathological characterized showed depletion of hemopoietic tissue with increase in numbers of blood sinuses.

The pathological changes due to (100 mg/kg B.W.) Showed brain gliosis and that due to aggregation of microglial cell (17) explained that the flavonoids has a direct effect on glial cells by inducing activation of astrocytes and microglia and release of tumor necrosis factor alpha (TNF-a). Flavonoids are generally thought to be having antioxidant and free radical scavenging effects .Flavonoids are also known to had neuroprotective actions (18).

Active compound like antioxidant, flavonoid, catechine and alkaloids which may be act as immune stimulant and increased splenocyte proliferation (19). The perivascular and peribronchiolar lymphocytic cuffing in the lung, kidney and hyperplasia of lymphoid tissue

of white pulp of spleen were due to the immune stimulant and increased splenocytes proliferation caused by active compound of the plant (19). Pancreas showed regeneration of islet of langerhans and this agreement with (20) Referred that patients with end-stage diabetic nephropathy showed corrected thiol deficiency, increased T cell activation, and reduced tumor necrosis factor- α , thus normalizing immunoregulatory defect (20). Also agreement with (21) in the pancreas grape seed acts mainly as chemoprotectant and can stimulate recovery after intoxication.

Bone marrow undergo proliferation of stem cell with presence of large numbers of megakaryocytes .The hyperplasia of hemopoietic tissue may be due to hemolytic anemia and it is a usual physiological response in order to increase the production of blood cells by the bone marrow with immature forms which appear in the circulation suggesting that compensatory erythropoiesis had been suppressed. In other words the bone marrow of toxicated group far from being depressed is in fact producing red cells at a considerable faster rate than normal and this is of a great value in helping the animal maintaining its hematological indices to meet the continuous blood loss. Stimulation and toxic effect resulting in exhaustion and suppression of hemopoietic tissue, and that agreed with (21).

Infiltration of mononuclear cells especially in liver, stomach and formation of early granuloma in liver, this may be attributed to the active compound like antioxidant flavonoid and alkaloids which may act as immune stimulant. The patient was given a better chance at survival if the cancer tissue showed infiltration of inflammatory cells, in particular lymphocytic reactions. The results suggested some extent of anti-tumor immunity is present in colorectal cancers in humans, in (22) published apaper findind tumour infiltrating lymphocytes to be quite significant in human colorectal cancer (22).

While at dose (200mg/kg B.W.) the predominant feature of organs was the necrosis and may be due to increase in hepatic oxygen demand without an appropriate increase in hepatic blood flow. Apoptosis also was due to connected to slight alterations within the plasma membrane causing the dying cells to be attractive to phagocytic cells (23).

Cerebellum there is severe congestion of blood vessels of cerebellar meninges that agreed with (24), that may be due to penerat of the extract the blood brain barrier. In intestine was infiltration of mononuclear cells in mucosa with slight fibrosis may be due the effect of extract on immune system (23). Histopathological examination of kidney sections showed necrosis of the epithelial lining of proximal and distal convoluted tubules may be to direct toxic effect of extract this result was agreed with (25). The hyperplasia and hyperkeratosis of the mucosa of stomach with marked changes that was attributed to the irritant and toxic effects of grape seed on the mucosal and submucosal layers of the organ. The available human and animal data suggest that gastro-intestinal tract is a sensitive target of toxicity (26).

Dose (300mg/kg B.W.) showed in cerebellum edema between molecular and granlur layer with degeneration of many purkinji may be attributed to the increase in the permeability of the blood brain barrier leading to disturbances in the blood dynamics and escape of fluids to the nervous tissues and that agreed with (27). Other pathological changes seen in liver was hyperplasia of intrahepatic bile ducts which may be due to cholestasis that agreed with (28). In the kidney was severe periglomerular infiltration of inflammatory cells and cytic of renal tubules with formation of hyaline cast that can be attributed to the damage which affect the renal parenchyma these results was in agreement with (29). Deposition of amyloid fibril protein (Amyloid light chain) type is associated with some form of monoclonal B-cell proliferation (30) Other pathological changes seen in pancreas was fibrosis that agreed with studies now suggest the pathogenesis of fibrosis is tightly

regulated by distinct macrophage population that exert unique functional activities throughout the initiation, maintenance and resolution phases of fibrosis (31).

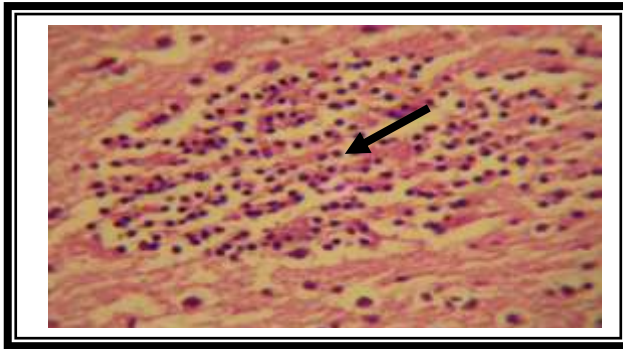
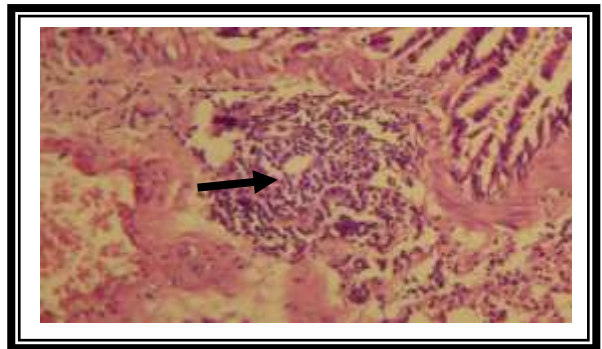
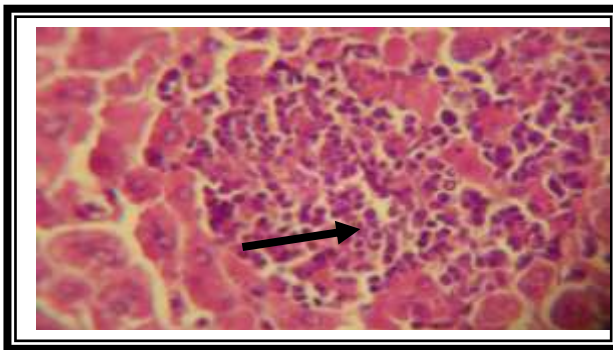


Fig (1): Histopathological section of Brain treated with grape seed at dose (100mg/kg b.w orally) showing focal gliosis (H&E X400).



Fig(2): Histopathological section of Lung treated with ethanolic extract of grape seed at dose (100mg/kg b.w orally) showing perivascular and peribronchiolar lymphocytic cuffing (H&F x400).



Fig(3) :Histopathological section of Liver treated with ethanolic extract of grape seed at dose (100mg/kg b.w orally) showing formation of early granuloma within hepatic parenchyma consisting of mononuclear cells aggregation (H & E x400).

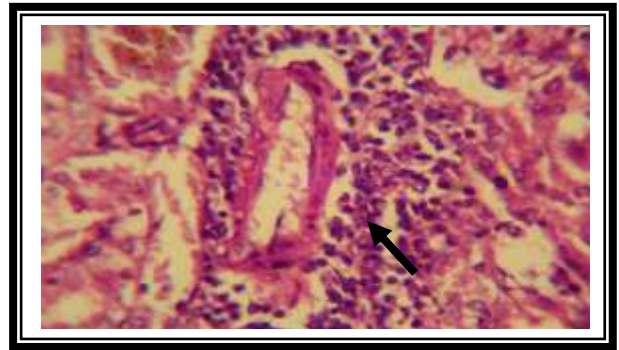


Fig (4): Histopathological section of Kidney treated with ethanolic extract of grape seed at dose (100mg/kg b.w orally) showing perivascular lymphocytic cuffing (H&E x400).

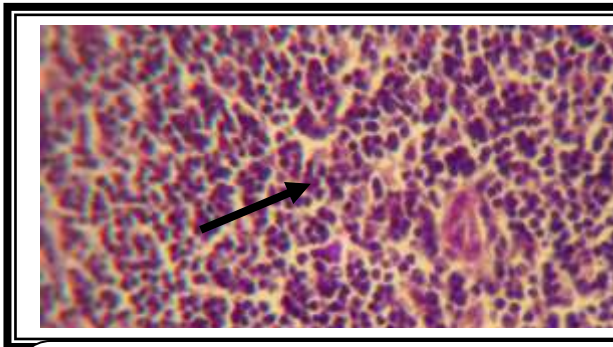


Fig (5): Histopathological section of Spleen treated with ethanolic extract of grape seed at dose (100mg/kg b.w orally) showing hyperplasia of lymphoid tissue of white pulp with deposition of hemosiderin pigment (H&E x400).

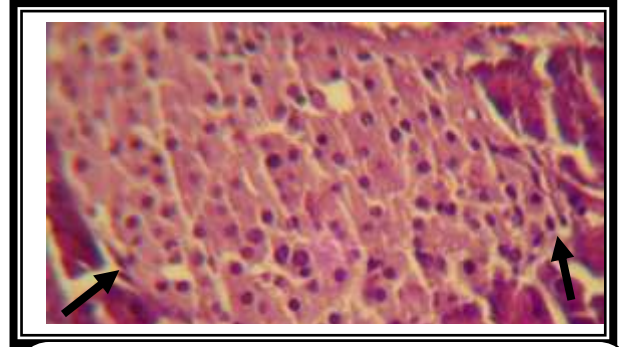


Fig (6): Histopathological section of Pancreas treated with ethanolic extract of rape seed at dose (100mg/kg b.w orally) showing regeneration of islets of Langerhan's (H&E x400).

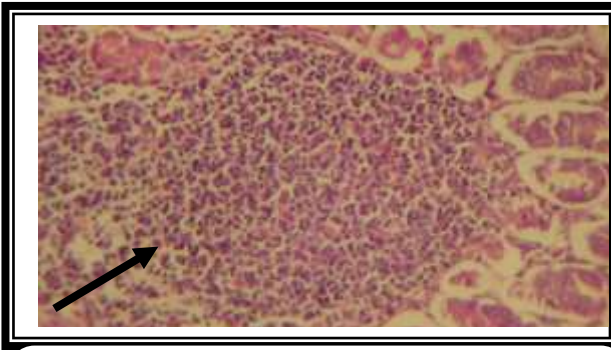
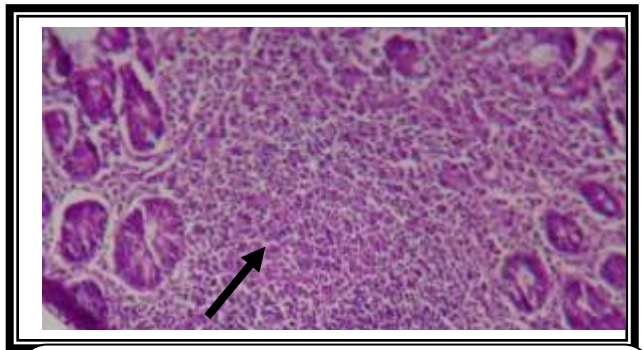
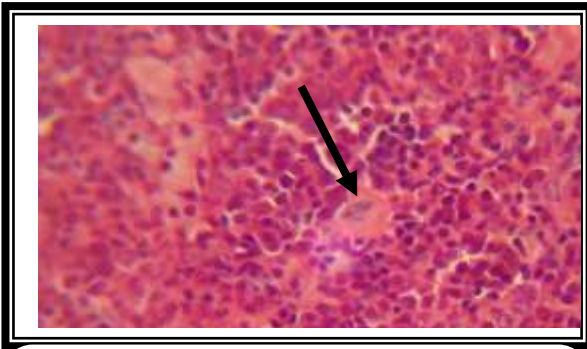


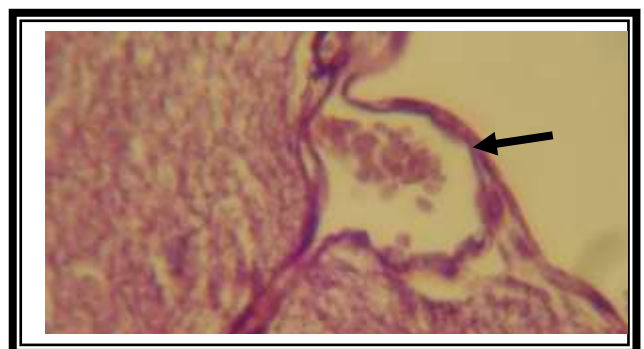
Fig (7): Histopathological section of Stomach (glandular region) treated with grape seed at dose (100mg/kg B.W orally) showing focal aggregation of mononuclear cells in mucosa (H&E x400).



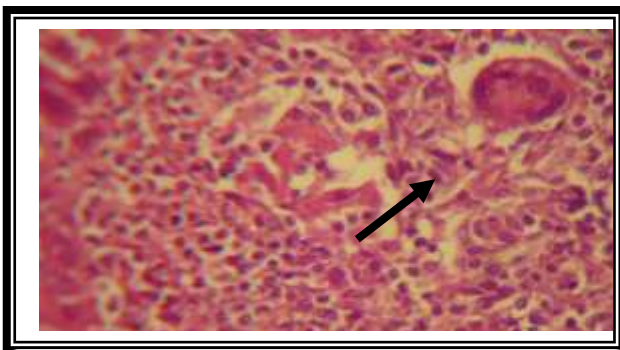
Fig(8) :Histopathological section of Intestine treated with ethanolic extract of grape seed at dose (100mg/kg b.w orally) showing hyperplasia of lymphoid tissue (H & E x400).



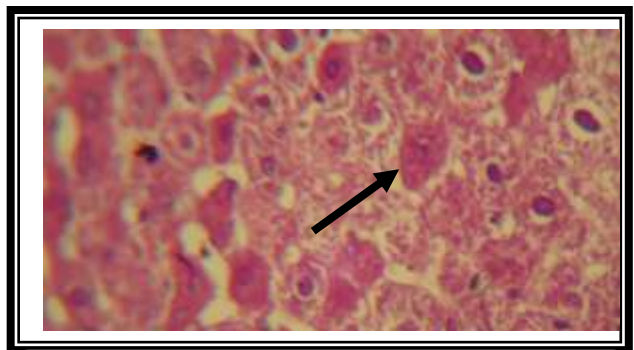
Fig(9) :Histopathological section of bone marrow of mouse treated with ethanolic extract of grape seed at dose (100mg/kg b.w orally) showing hemopoietic tissue with increase in numbers of megakarvocvtes (H & E x400).



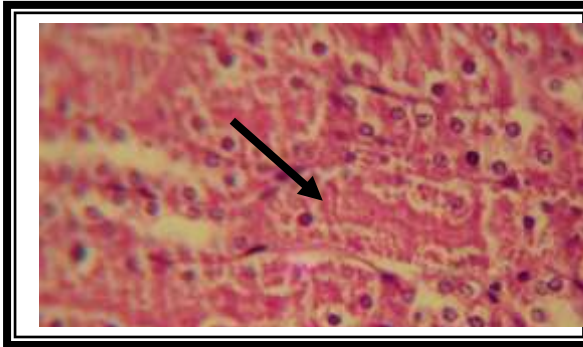
Fig(10) :Histopathological section of Brian treated with ethanolic extract of grape seed at dose (200g/kg b.w orally) showing severe congestion of blood vessels of cerebellar meninges (H & E x400).



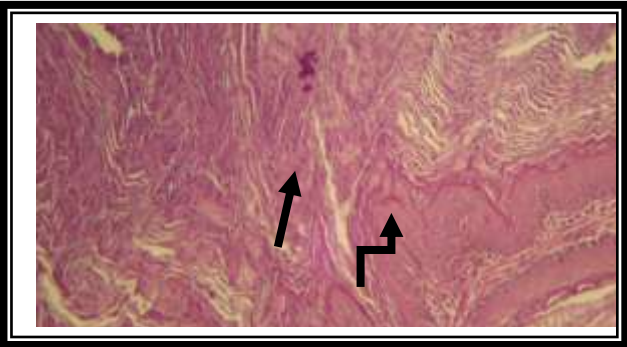
Fig(11) :Histopathological section of Intestine treated with ethanolic extract of grape seed at dose (200mg/kg b.w orally) showing infiltration of mononuclear cells in mucosa with slight fibrosis leading to atrophy of glands (H & E x400).



Fig(12) :Histopathological section of Liver treated with ethanolic extract of grape seed at dose (200g/kg b.w orally) showing extensive areas of necrosis and apoptosis (H & E x400).



Fig(13) :Histopathological section of Kidney of mouse treated with ethanolic extract of grape seed at dose (200g/kg b.w orally) showing severe necrosis of epithelial lining of proximal and distal convoluted tubules (H & E x400).



Fig(14) :Histopathological section of Stomach treated with ethanolic extract of grape seed at dose (200mg/kg b.w orally) showing hyperplasia(↗)and marked hyperkeratosis of mucosa(→) (H & E x400).

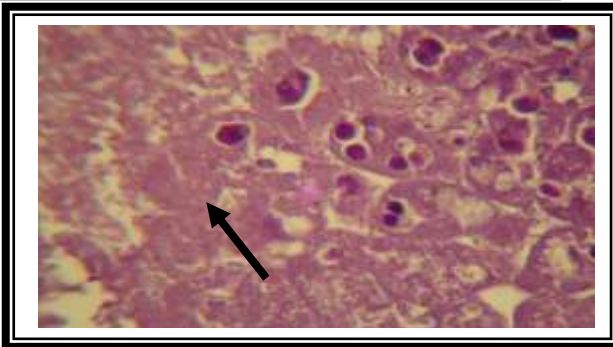


Fig (15): Histopathological section of Pancreas treated with ethanolic extract of grape seed at dose (200mg/kg b.w orally) showing extensive necrosis of pancreas (H&E x400).

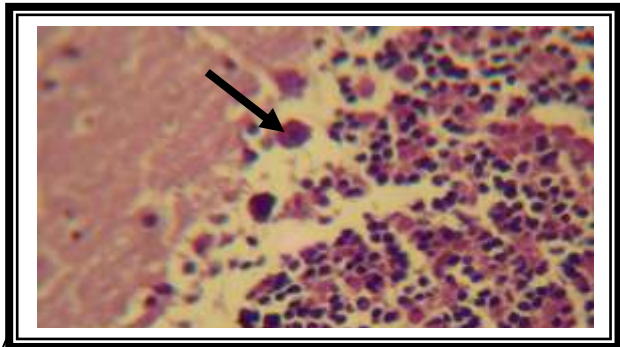
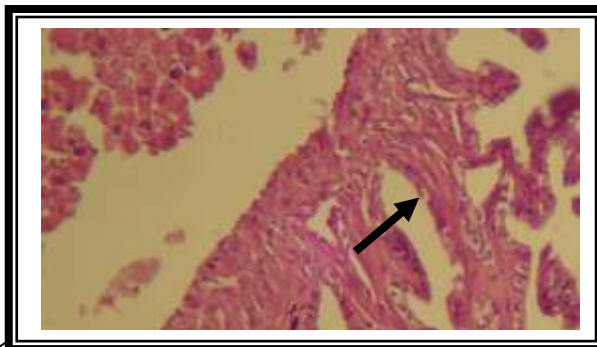
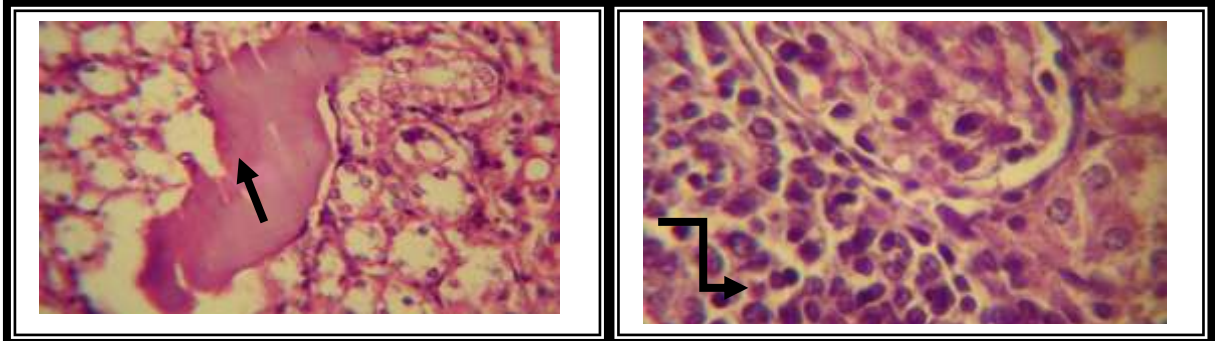


Fig (16): Histopathological section of Cerebellum treated with ethanolic extract of grape seed at dose (300mg/kg b.w orally) showing edema between molecular and granular layer with degeneration of many purkinji and complete dissolution of the others (H&E x400).



Fig(17) :Histopathological section of Liver treated with ethanolic extract of grape seed at dose (300mg/kg b.w orally) showing hyperplasia of intrahepatic bile ducts forming papillary projections (H & E x400).



Fig(18) :Histopathological section of Kidney of mouse treated with ethanolic extract of grape seed at dose (300mg/kg b.w I/P) showing severe periglomerular infiltration of inflammatory cells (↵) and cystic of renal tubules with formation of hyaline cast (→) (H & E x400).

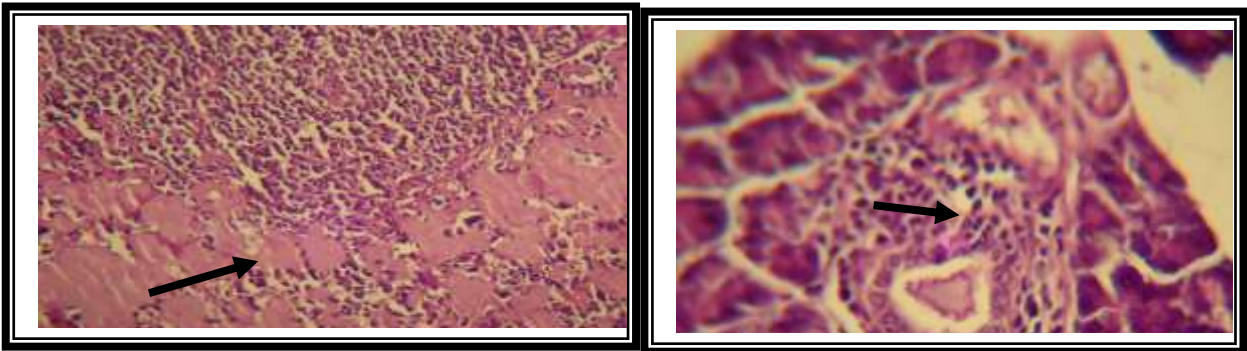


Fig (19): Histopathological section of Spleen treated with ethanolic extract of grape seed at dose (300mg/kg b.w orally) showing deposition of amyloid like substance causing pressure atrophy to lymphoid tissue (H&E x400).

Fig (20): Histopathological section of Pancreas treated with ethanolic extract of grape seed at dose (300mg/kg b.w orally) showing infiltration of mononuclear cells around pancreatic duct with slight fibrosis (H&E x400).

References

- 1-Shi, J.; Yu, J.; Pohorly, JE. and Kakuda, Y.(2003) Polyphenolics in grape seeds-biochemistry and functionality. J. Med. Food. Winter, 6(4):291-299.
- 2- Yamakoshi, J.; Saito, M.; Kataoka, S. and Kikuchi, M.(2002). Safety evaluation of proanthocyanidins-rich extract from grape seeds. Food Chemical Toxicol., 40:599–607.
- 3- Opie, LH. and Lecour, SL. (July 2007). The red wine hypothesis: from concepts to protective signalling molecules. Eur. Heart J., 28 (14): 1683–93.
- 4-Harborne, JB.; Marbay, TJ. and Mabray, H. (1975) . Physiology and function of flavonoids. Academic Press, New York,Pp: 970.
- 5-Archer, RK. (1985). Hematological techniques for use on animals. Oxford: Blackwell, Scientific publication.
- 6- Allen, JW.; Shuler, CF.; Mendes, RW. and Latt, SA. (1977). A simplified technique for in vivo analysis of sister chromatid exchanges using 5-bromo deoxyuridine tablets. Cytogenet. and Cell Genet., 18: 231-237.
- 7- Yamakoshi, J.;Saito, M.; Kataoka, S. and Kikuchi, M. (2002). Safety evaluation of proanthocyanidinrich extract from grape seeds, Food Chem. Toxicol., 40: 599-607.

- 8- Luna, GL. and Lee, AA. (1968). Manual of Histological staining methods of the armed forces. Institute of pathology 3rd ed. McGraw-Hill Book Company, New York, USA.
- 9-Steele, VE.; Kelloff, GJ.; Wilkinson, BP. and Arnold, JT.(1990). Inhibition of transformation in cultured rat tracheal epithelial cells by potential chemopreventive agents. *Cancer Res.*, 50:2068- 2074.
- 10-Al-Shamery, AM. (2003).The study of Newcastle disease virus effect of treatment of transplanted tumor in mice. MSc. Thesis, College of Veterinary Medicine, University of Baghdad, Iraq.
- 11-Maddocks, JL.; Lennard, L.; Amess, J.; Amos, R. and Meyrick-Thomas, R. (1986). Azathioprine and severe bone marrow depression. *Lancet.*, 1: 156.
- 12-Amin, A. and Hamza, AA. (2005). Hepatoprotective effects of Hibiscus, Rosmarinus and Salvia on azathiopromine-induced toxicity in rats. *Life Sci.*, 77: 266–278.
- 13-Lanning, LL. (2006). Toxicologic pathology assessment. In *Toxicological Testing Handbook, Principles, Applications, and Data Interpretation*, Jacobson-Kram D, Keller KA., 2nd ed. Informa Healthcare: New York, London, Chapter 5.
- 14- Lang, I.; Nekam, K.; Gonzalez-Cabello, R.; Muzes, G.; Gergely, P. and Feher, J. (1990). Hepatoprotective and immunological effects of antioxidant drugs. *Tokai. J. Exp. Clin. Med.* , 15:123-7.
- 15- Takano, F.; Tanaka, T.;Tsukamoto, E.; Yahagi, N. and Fushiya, S. (2003). Isolation of (+)catechin and epicatechin from *Actinidia arguta* as bone marrow cell proliferation promoting compounds. *Planta. Med.*, 61:321-326.
- 16-Ashmawy, IM.; Amal S. and Salama, OM. (2007). Effects of marjoram volatile oil and grape seed extract on ethanol toxicity in male rats. *Basic Clin. Pharmacol. Toxicol.*, 101:320-326.
- 17-Bahia, PK.; Rattray, M. and Williams, RJ. (2008). Dietary flavonoid (-)epicatechin stimulates phosphatidylinositol 3-kinase-dependent anti-oxidant response element activity and up-regulates glutathione in cortical astrocytes. *J. Neurochem.*, 106:2194–2204.
- 18- Spencer, JP. ; Rice-Evans, C. and Williams, RJ. (2003). Modulation of pro-survival Akt/PKB & ERK1/2 signalling cascades by quercetin and its in vivo metabolites underlie their action on neuronal viability. *J. Biol. Chem.*, 278:34783–34793.
- 19-Kamath, A.B. ; Wang, L. and Das, H., (2003). Antigens in tea – beverage prime human V gamma 2delta zt cells in vitro and in vivo for memory and nonmemory antibacterial cytokine responses. *Proc. Natl. Acad. Sci.*, 100:6009 – 6014.
- 20-Dietzmann, J.; Thiel, U.; Ansorge, S.; Neumann, K.H. and Tager, M. (2002). Thiol-inducing and immunoregulatory effects of flavonoids in peripheral blood mononuclear cells from patients with end-stage diabetic nephropathy. *Free Radic. Biol. Med.*, 33: 1347-1354.
- 21-Soto, CP. ; Perez, BL.; Favari, LP.and Reyes, JL. (1998). Prevention of alloxan-induced diabetes mellitus in the rat by catching. *Comparative Phar. and Tox.*, 119:125- 129.
- 22- Ohtani, H. (2007). Focus on TILs: Prognostic significance of tumor infiltrating lymphocytes in human colorectal cancer. *Cancer Immunity*, 7: 4.
- 23- Shibayama, K.; Doi, Y.; shibata, N.; Yagi, T.; Nada, T.; linuma, Y. and Arakawa, Y. (2001). Apoptotic Signaling Pathway Activated by *Helicobacter pylori* Infection and Increase of Apoptosis-Inducing Activity under Serum-Starved Conditions. *Infection and Immunity*. 69(5): 3181-3189.
- 24- AL-Rubaiee, AH. (1992). Industrial lead poisoning in Iraq. PhD Thesis, University of Baghdad.
- 25- Dashy, SC. (1989). Copper sulfate poisoning and acute renal failure. *Int. J. Artif. Organs*, 12.P:610.
- 26- Araya, M.; Olivares, M.; Pizarro, F.; Llanos, A.; Figueroa, G. and Uauy R. (2004). Community based randomized double- Blind study of gastrointestinal effects and copper Exposure in drinking water. *J. Environ Health Perspect*, 112(10):1068-1073.

The Iraqi J. Vet. Med. 36 (1): 85– 98; 2012

- 27- Goldstein, G. (1990). Lead poisoning and brain cell function. *J. Environ Health perspect*, 89:91-94.
- 28- Kasai, N; Osanai, T.; Miyoshi, L.; Kamimura, E.; Yoshida, MC. And Dempo, K.(1990). Clinico-pathological studies of LEC rats with hereditary hepatitis and hepatoma in the acute phase of hepatitis. *Lab. Anim. Aci*, 40:502-505.
- 29- Chugh, KS.; Sharma, BK. and Singhal, PC.(1977). Acute renal failure copper sulfate intoxication post grad. *Med. J.*, 53:18-23.
- 30-Kumor, V.; Abbas, AK.; Cotran, RS. and Robbins, SL. (2007). *Robbins Basic Pathology* (8thed).Saunders, Pennsylvania, USA. Pp: 165-210.
- 31-Wynn, TA. and Barron, L. (2011). Macrophage Master Regulators of inflammation and fibrosis. *Semin Liver Dis.*, 30(3):245-257.