

Evaluation of two biological matrices for repairing of ventral hernia in bucks

A.K. Mahdi and Ahmed H. F. AL-Bayati

Department of Surgery and Obstetrics, College of Veterinary Medicine, University of Baghdad, Iraq.

E-mail: kamelareeg@yahoo.com.

Received: 1/3/2018

Accepted: 9/4/2018

Publishing: 31/1/2019

Summary

The aim of this study was to estimate the changes in ventral hernia repairing in Iraqi bucks by using two biological matrixes derived from bovine (pericardium and urinary bladder matrix) through histopathological examination. All bucks right lower flank awas prepared surgically, sedation were done by using (2% Xylazine hydrochloride) at a dose of 0.2mg/kg intramuscular, and surgical site anesthetized through an inverted (L) shape local infiltration technique using lidocaine hydrochloride (2%) at a dose of 8mg/kg. Ventral abdominal hernias were induced in (24) bucks through elliptical resection of abdominal muscles to made hernia ring (6-8cm) with avoiding peritoneum perforation. After 30 days of operation bucks were divided into two equal groups. cellular Bovine pericardium group and cellular urinary bladder matrix group. In two groups hernias were treated with only replacement of acellular bovine pericardium and cellular urinary bladder matrix respectively which fixed with interrupted horizontal mattress 2cm far from hernia ring by Polypropylene (No.1) suture material. Histopathological biopsies were taken at 2nd, 8th and 16th week post treatment (4 bucks\ period). Both groups' successes in reconstruction of large hernia in bucks through prevent recurrent or others post-operative complications. In addition the histopathological examination showed that the acellular urinary bladder matrix superior than acellular bovine pericardium matrix in enhance healing based on acellular urinary bladder matrix role in augment early initiation of inflammatory cells infiltration, fibroblast proliferation and marked collagen deposition, in addition to its early degradation, incorporation and remodeling.

Keywords: Hernia, Bucks, Bioimplants, Histopathological..

Introduction

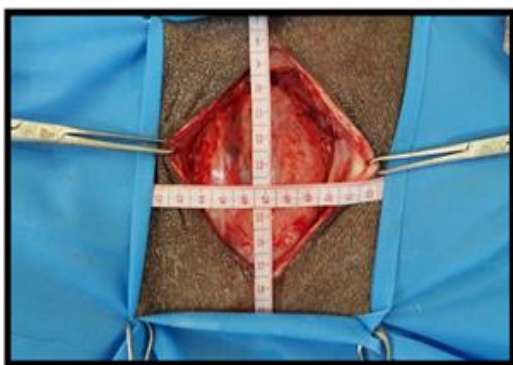
Abdominal wall defects (hernia) correspond a difficult trouble, considered a common acquired condition in ruminant's which has some harmless effects, such as lowering the productivity and reproductively (1 and 2). Furthermore, large full-thickness, abdominal wall defects secondary to wide resection of malignant tumors, traumatic injuries or congenital abnormalities cannot be closed primarily (3). Surgical intervention (herniorrhaphy) is useful in these cases but large ventral abdominal hernia may require hernioplasty such as (Mesh repairs) to minimize the amount of tension that must be put on the abdominal wall in order to cover the hernia (4). However, these materials may in addition to cause infection and chronic pain in

the surgical area (5), it may perhaps contribute to the dysfunction of other organs, and cause complications such as internal adherence, obstructions, and fistula development (6). To avoid the potential squeal of synthetic non absorbable materials, biological materials are being developed by the surgeons and used for abdominal wall defect repairs and other applications, such as porcine small intestinal sub mucosa, a cellular dermal matrix and human dura mater (5). The composition and structure of these biomaterials contrast according to the source of the tissue that can provide a reservoir of active molecules like growth factors that can be rapidly mobilized following injury to stimulate cell proliferation and migration (7).

The current study aimed to compare the efficacies of using of two natural bio-scaffolds including; acellular bovine pericardium matrix (BP) and acellular urinary bladder matrix (UBM) in the reconstruction of experimentally induced large ventral hernias in Iraqi bucks.

Materials and Methods

After obtaining an official approval from the ethical committee of the college. Twenty four apparently healthy adult local bucks aged 1-2 years and weighing (25-30) kg were used. Bucks were acclimatized for 2 weeks in pens at the College of Veterinary Medicine, University of Baghdad, Iraq before operation. The animals were divided and numbered according to the experimental design and each animal was injected s.c with Ivermectin as antihelminthic in a dose 0.2mg/kg., B.W and s.c vaccinated with 5ml of enterotoxaemia vaccine. Ventral abdominal hernias were induced in the right lower flanks of 24 bucks before herniation, food was withheld for 24 hours and water for 12 hours. Buck was sedated with (Xylazine hydrochloride 2%) at a dose of 0.2mg/kg B.W IM. In addition surgical site were anesthetized locally by using lidocaine hydrochloride (2%) at a dose of 8mg/kg B.W through an inverted (L) shape local infiltration technique. A vertical incision 10-12cm was done through skin and subcutaneous tissue, then abdominal muscles were separated bluntly, to create hernia 6-8cm of full-thickness abdominal muscles were resected with avoiding opening the peritoneum (Fig.1). Finally, skin and subcutaneous layers were sutured using simple interrupted pattern with non-absorbable suture materials (Silk No.1) and wounds were covered with sterile gauze.



Figure, 1: Shows hernia ring after excision of abdominal wall muscles.

Whole fresh urinary bladders of cows were excised immediately after slaughtered at local abattoir. The matrix was prepared as described by (7 and 8) to make it acellular to prevent rejection. The urinary bladder was filled with tap water to facilitate trimming of external connective tissues and adipose tissue with scissors and washed in tap water. The tunica serosa, tunica muscularis and most of the muscularis mucosa were mechanically delaminated from bladder tissue by scraping with blunt knife. The remaining basement membrane of the tunica mucosa and the subjacent tunica propria became a urinary bladder matrix (UBM), decellularized and disinfected by immersion in peracetic acid (0.1%) and ethanol (4%) for two hours. Traces of peracetic acid were removed and pH adjusted to ~7.4 by rinsing in phosphate buffered saline (PBS) with 100 IU/ml penicillin, 100 µg/ml streptomycin and 100 µg/ml amphotericin. At room temperature the scaffold was rinsed and shaken in deionized water twice, and once in PBS for 15min. The scaffold was then sterilized by immersion in peracetic acid solution (0.1%) titrated to pH 7.0 at room temperature for five hours.

Bovine pericardium was excised from slaughtered cows at local abattoir and submerged in PBS (pH 7.4) and rinsed in saline until clean of blood. Fat and connective tissues was removed with dry gauze. The tissue was decellularized as mentioned by (9) with the same steps were done for UBM decellularization. After 30 days post inducing of hernia, all animals were allocated into two main equal groups. In Bovine pericardium group (BP), the hernias ring was closed with a sheets of acellular BP sheets. Under the effect of sedation and local anesthesia, as mention before, the area of the operation was ready for aseptic operation and vertical skin incision was made parallel to the original skin incision. Gentle blunt dissections of the underlying tissues to free the adhesions until defined the borders of the hernial ring and then the hernial sac was inverted into the abdominal cavity. Implants were soaked in sterile PBS (containing antibiotics and antifungal) for

three hours before operation, onlay repair technique was done and BP implant firmly fixed with the muscular layers of the hernia ring by interrupted stitches of horizontal mattress with Polypropylene (No.1) no less than 2cm far from hernia edges. The access skin and s.c tissue was sharply excised then skin closed. The same procedures as mentioned for first group were performed in urinary bladder group (UBM); with exception that the hernias were closed with acellular UBM implant (Fig.2). Post-treatment of hernia, sterile bandage truss were used for each buck to care the surgical site and to lessen postoperative edema. To reduce the activity of animals and avoid the trauma all animals were housed in separated pen. During first five days, the animals received soft food which increased gradually with the time associated with daily administration IM of a combination of penicillin and streptomycin in a dose of 10.000 IU/ kg and 10 mg/kg body weight respectively for 5days.

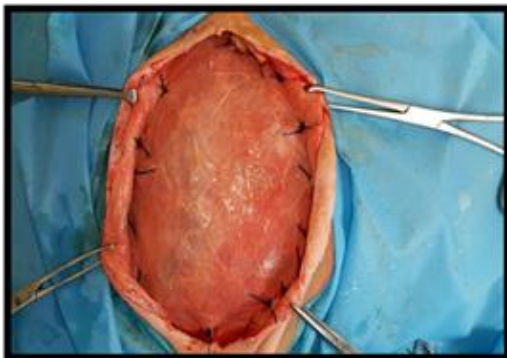


Figure 2: Shows the onlay fixation of the UBM sheet with interrupted horizontal mattress using Polypropylene (No.1).

The histopathological evaluation was performed at 2, 8, and 16 weeks post-implantation (four animals/period). Segments of (1x1) cm³ were collected from three areas; edge of the implant, center and between them. The samples were fixed in neutral buffered formalin solution (10%) and set in paraffin and then sectioned longitudinally and transversally at (5-7) μm and staining with Hematoxylin-Eosin (H&E) and Mallory trichrome stain which stain collagen blue color and granulation tissue yellowish color (10).

The results of the histopathological score of progression of healing process in the site of hernias of both treatment groups were evaluated through using a scoring system, as mentioned in (Table,1), illustrated by (11). Higher scores within the scoring system represent more approving outcomes with rating to remodeling, as evidenced by cellular infiltration, host ECM deposition, neovascularization, scaffold degradation, fibrous encapsulation and cell types that represent low levels of inflammation.

Data were analyzed using SAS (Statistical Analysis System-Version 9.1). Two ways ANOVA and least significant differences (LSD) post hoc test were performed to assess significant difference among means $P \leq 0.05$ was considered statically significant.

Table,1: Histopathological scores of progression of healing process at the site of hernias (11).

scores	0	1	2	3
Cellular infiltration	Zero cells in contact with Scaffold.	Cells contact periphery, no penetration into scaffold.	Cells infiltrate scaffold, not reach center	Cells penetrate into center of scaffold
Cell types (neutrophiles, macrophages ,and foreign body giant cells	Inflammatory cells present, no fibroblasts	Primarily inflammatory cells, few fibroblasts	Primarily fibroblasts few inflammatory cells	Fibroblasts only, no inflammatory cells
Host extracellular matrix (ECM) deposition.	No host ECM deposition	Host ECM deposited atperiphery of scaffold	Host ECM deposited Inside scaffold, but not at the center	Host ECM deposited inside scaffold, including the center
Scaffold degradation	Original scaffold intact, Borders clearly demarcated	Scaffold partially degraded, layers separated by cells, blood vessels, host tissue, etc.	Scaffold extremely degraded, difficult to distinguish scaffold from host tissue	Scaffold completely degraded, no evidence of original scaffold.
Fibrous encapsulation	Extensive encapsulation (50–100%) of periphery)	Moderate encapsulation (25–50% of periphery)	Mild encapsulation (≤25% of periphery)	No fibrous encapsulation
Neovascularization	Zero blood vessels presence	Vessels present at scaffold periphery, no penetration into scaffold	Vessels infiltrate scaffold but not reach center of scaffold	Vessels penetrate into center of scaffold

Results and Discussion

Clinically, all experimental bucks were kept under inspection along the period of the study to record general health, behavior and alertness, with no death of any animal. Ventral hernia was noticed directly post-operations of inducing hernias, there were appeared as clear tense swelling in the right low flank of the abdominal wall. Post-treatment of hernias, the hernia sac was disappeared, and local inflammatory reaction was gradually disappeared within 5 to 7 days, as well as, clinical followed-up of both treatment groups not recorded any complications, except different sizes of seromas were formed in three bucks of each treatment groups which were detected during 3 days post-implantation by gradual formation of sac like swelling at the site of implantation and treated by exploratory aspiration of the serous fluids under aseptic technique. Along the period of the study, one case of reherniation was noticed in UBM group at 5 days may be due to severe and continues coughing which associated to aspiration pneumonia.

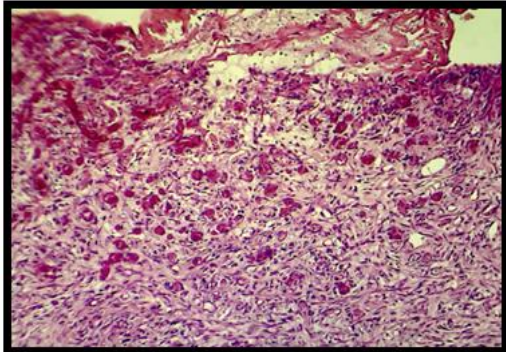
In the present study, hernias were treated after 4th weeks post-inducing to create complicated hernia and fibrosis of hernia ring. All implants fixation were success without tearing through suturing with ring site. This result closed to (12), whom referred that the hernia repairing should be performed at least four weeks post-inducing may be due to it suitable time for resolution of active inflammation.

Alternatively, only replacement was used in this study is a successful technique with this biological implant and hernia size, it gave improvement of tissue healing as showed in histopathological results, without complications or recurrent. The same observations were noticed by (13), whom explained that onlay implantation allows of tissue in growth by two directions and (14), demonstrated that the contact of biomaterial with the fascia over or under the rectus muscles stimulates re-growth of the host tissue, and promotes the production and deposition of collagen on the suture line in addition to acceleration of wound healing.

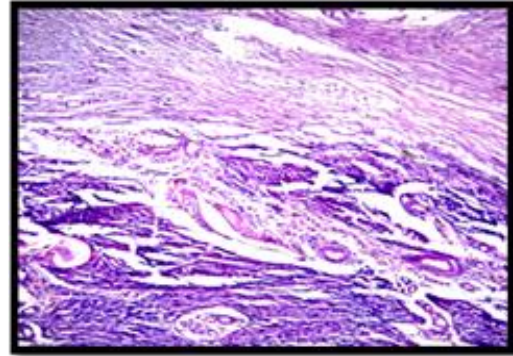
In the current study, seroma was occurred in three animals for each treated group during 72

hours post-hernia treatment. Many previous studies like (15 and 16) recorded the formation of seromas in more than one case at the same period of the present study post-hernioplasty. The causes of seroma formation in the current study may be due to dissections that form separation between skin and subcutaneous tissue, as well as, the manipulation at surgical site for implantation that cause aseptic inflammation. These reasons are the same as recorded by (17), who referred to seroma formation due to local inflammatory response to a mechanical injury during surgical dissection and the presence of foreign bodies. While, (18) noticed that the abdominal wall approaching (ventral incision) lead to accumulation of blood and serum among the various level of wound resulting in hematoma or seroma or dead space. other authors (19) referred to the seroma formation are, the blood and lymphatic vessel injury during dissection, dead-space formation, shear forces among layers and the release of inflammatory mediators .

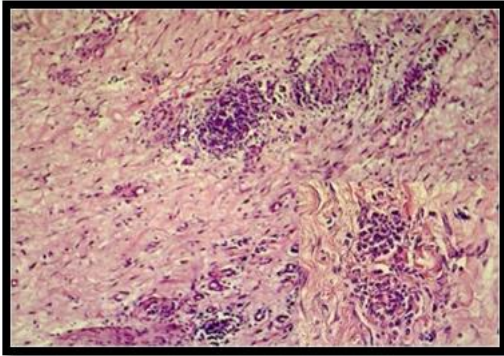
Wound infections weren't noticed along the followed up period, it may be related to the biological implants components. Many studies were confirmed the antimicrobial effects of natural bio-scaffolds therefore increased frequency of their using to repair contaminated abdominal wall defects (20 and 21). Other result chers (22) suggested the presence of several different low molecular weight peptides with antibacterial activity exist within ECM and such peptides can resist the bacterial infection, and there were differences between antimicrobial peptides in each bioscaffolds type. Histopathological section at 2weeks post implantation in BP group revealed presence of highly cellular and vascular immature granulation tissue with severe hemorrhage and numerous congested capillary and moderate mononuclear cells (MNCs) (Fig.3), in another section there were a multifocal MNCs aggregation consist mainly of macrophages and lymphocytes with proliferation of fibroblasts producing collagen fibers (Fig.4), and identification of a fragment of muscles fibers observed within the necrotic area with calcium precipitation (Fig.5).



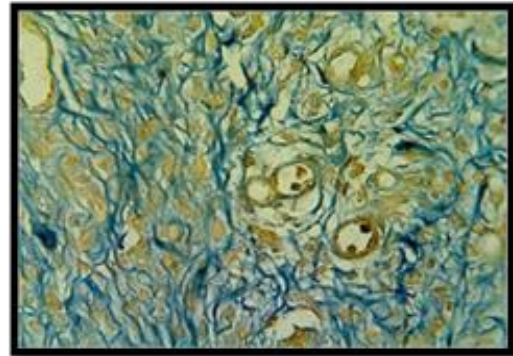
Figure, 3.: Histopathological section in BP-treatment group at 2nd week post implantation, shows the presence of highly cellular vascular immature granulation tissue with severe hemorrhage(long arrow) numerous congested capillary(short arrow) and moderate mononuclear cells (MNCs) (H&E stain, 100X)



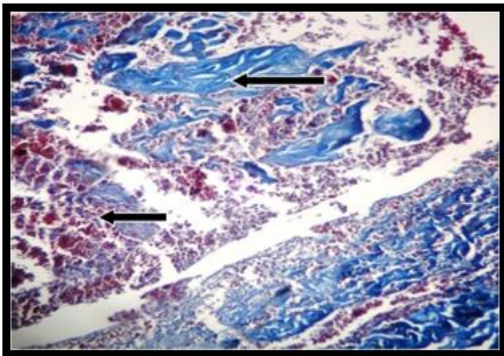
Figure, 6: BP-treatment group at 8th week post implantation shows fragments of pericardial implant (long arrow) and high vascularization, presence of immature collagen fibers and blood vessels in the host tissue(short arrow) (Mallory stain, 200X).



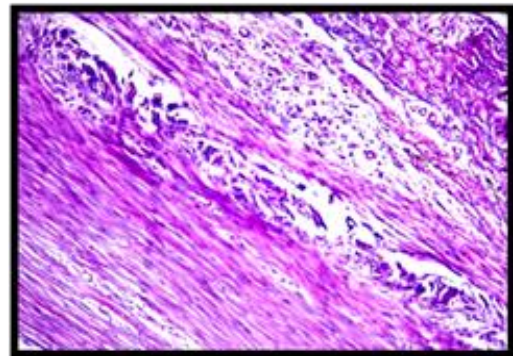
Figure, 4: BP-treatment group at 2nd week post implantation, shows a multifocal MNCs aggregation (long arrow) consist mainly of macrophages and lymphocyte with proliferation of fibroblast producing collagen fibers (H&E stain, 100X) .



Figure, 7: BP-treatment group at 8th week post implantation shows vascular (immature) granulation tissue (H&E stain,).



Figure, 5: BP-treatment group at 2nd week post implantation, shows fragment of muscles fibers observed within the necrotic area (long arrow) with calcium precipitation (short arrow) (Mallory stain, 100X).

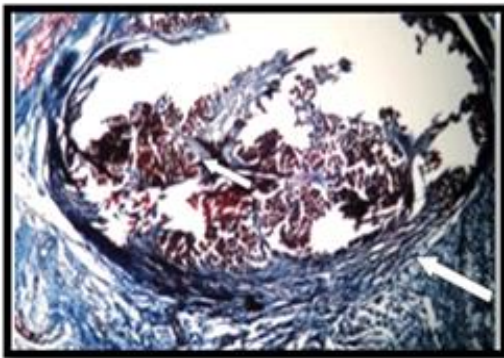


Figure, 8: BP-treatment group at 8th week post implantation, shows presence of thick collagen fibers (long arrow) with moderate vascular granulation tissue (short arrow) (Mallory stain, 200X).

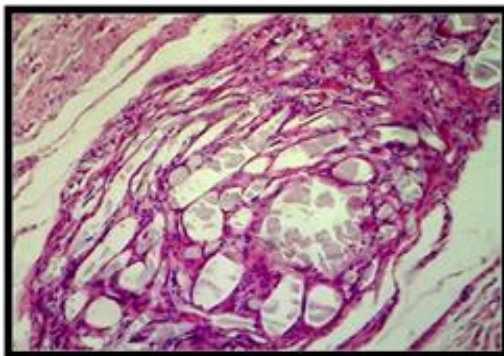
The histopathological section at 8 weeks post implantation in BP group showed a fragments of BP and high vascularization, presence of immature collagen fibers and blood vessels (BVs) in the host

tissue (Fig.6), in another section, vascular (immature) granulation tissue was seen (Fig.7), with presence of thick collagen fibers with moderate vascular granulation tissue (Fig.8).

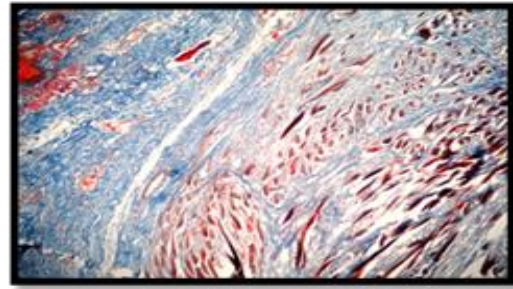
Histopathological study at sixteen weeks post implantation in BP group showed BP implant surrounded (encapsulate) by thin zone of mature fibrous connective tissue with calcium percipitation and accompined with moderate vascular response (Fig.9). The center of implant was invaded by moderate (MNCs) and collagen fibers (Fig.10), while, moderate vascular granulation tissue with moderate cellular infiltration was identified (Fig.11).



Figure, 9: BP-treatment group at 16th week post implantation, shows BP implant and surrounded (encapsulate) by thin zone of mature fibrous connective tissue(long arrow) with calcium percipitation (short arrow) and accompined with moderate vascular response (Mallory stain, 200X).

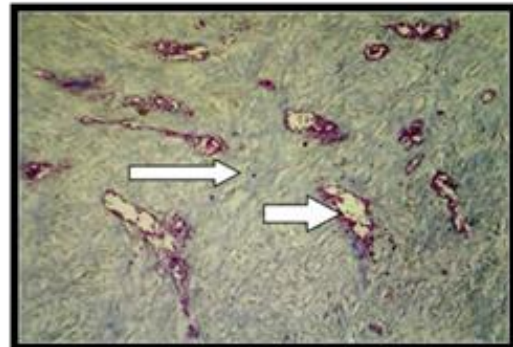


Figure, 10: BP-treatment group at 16th week post implantation, shows centrally implanted material (long arrow) was invaded by moderate inflammatory cells (MNCs) and collagen fibers (H&E stain, 400X).

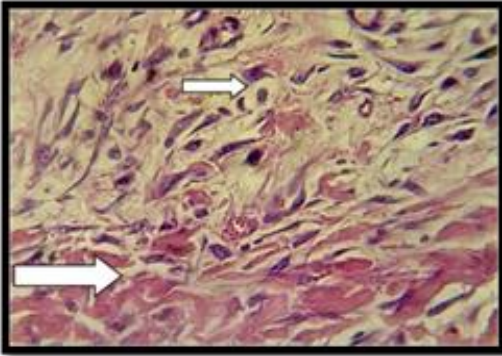


Figure, 11: BP-treatment group at 16th week post implantation shows moderate vascular granulation tissue with moderate cellular infiltration was identified (Mallory stain, 100X).

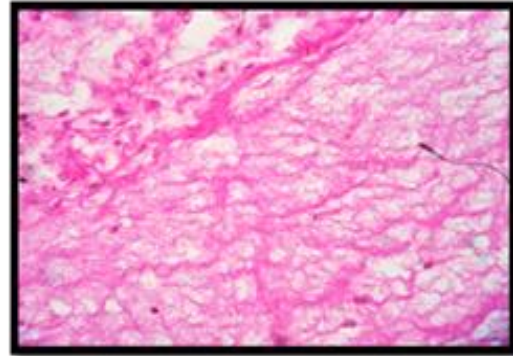
The histological sections at 2weeks of UBM revealed the formation of granulatn tissue consinsisting from dense collagen fibers with numerous dilated and congested BVs with mild MNCs response (Fig.12), as well as, vascular granulation tissue infiltrated with MNCs and myofibroblasts extended from muscular borders of implantation site (Fig.13). While in (Fig. 14) there were depositions of newly form collagen fibers mainly around tissue debris.



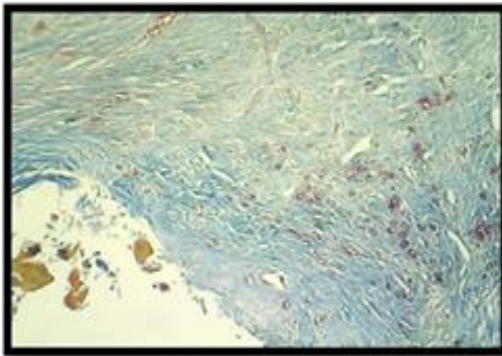
Figure, 12: UBM-treatment group at 2nd week post implantation, shows formation of granulatn tissue consinsisting from dense collagen fibers (long arrow) with numerous dilated and congested blood vessels (short arrow) with mild MNCs response (Mallory stain, 200X).



Figure, 13: UBM-treatment group at 2nd week post implantation, shows vascular granulation tissue was infiltrated with MNCs and myofibroblasts extended from muscular borders of implantation site (H & E stain, 400).

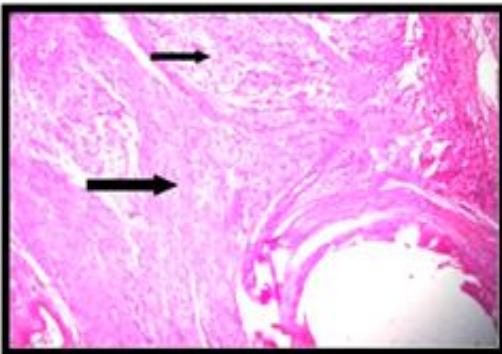


Figure, 16: UBM-treatment group at 8th week post implantation shows the construction of implant with delicate irregular collagen fibers (long arrow) (H&E stain, 400X).



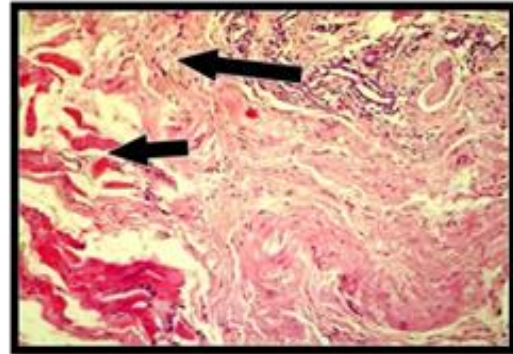
Figure, 14: UBM-treatment group at 2nd week post implantation shows deposition of newly formed collagen fibers mainly around tissue debris (long arrow) (Mallory stain, 100X).

The host tissue at 8 weeks post implantation exhibited peripheral aggregation of MNCs forming granulomatous like reaction as shown in (Fig.15). In addition shows the construction of implant with delicate irregular collagen fibers (Fig. 16).

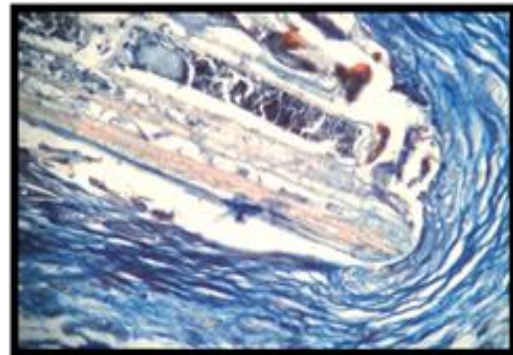


Figure, 15: UBM-treatment group at 8th week post implantation, shows that host tissue (long arrow) exhibited peripheral aggregation of MNCs (short arrow) forming granulomatous like reaction (H&E stain, 200X)

At sixteen weeks post implantation, the histopathological finding characterized by formation of thick regular collagen fibers infiltrated with MNCs which attached to host muscular layer and incorporation of new collagen bundle within muscular coat (Fig.17). In addition, remnant of implant near the suture material surrounded by new fibrous tissue (Fig.18).



Figure,17: UBM-treatment group at 16th week post implantation, shows regular collagen fibers infiltrated with MNCs which attached to host muscular layer and incorporation of new collagen (H&E stain,200X)



Figure, 18: UBM-treatment group at 16th week post implantation, shows the remnant of implant (long arrow) near the suture material surrounded by new fibrous tissue (Mallory stain, 400X).

The analysis results of the histopathological score (Table, 2) gives well information about the role of both implants in enhanced healing, and reflected that despite the significant

difference ($P \leq 0.05$) between both group at the 2nd and 8th week, while no significant differences was confirmed at 16th week.

Table ,2 : Shows the Means± SE of histopathological score results for both treatment groups.

Reaction score	Group	2 weeks	8 weeks	16 weeks	LSD
Cellular Infiltration	BP	C 1.00±0.28b	B 2.00±0.14b	A 3.00±0.57a	0.9945
	UBM	B 2.00±0.14a	A 3.00±0.28a	A 3.00±0.14a	
Cell type (inflammatory cells)	BP	B 1.00±0.14b	A 2.00±0.28b	A2.00±0.28b	0.6022
	UBM	B 2.00±0.14a	A 3.00±0.00a	A 3.00±0.14a	
Host (ECM) deposition	BP	B 1.00±0.28b	A 2.00±0.28b	A2.00±0.28b	0.9945
	UBM	B 2.00±0.28a	A 3.00±0.28a	A 3.00±0.14a	
Scaffold Degradation	BP	C 1.00±0.14b	B 2.00±0.28a	A2.00±0.28b	0.7032
	UBM	B 2.00±0.14a	B 2.00±0.14a	A3.00±0.28a	
Fibrous Encapsulation	BP	A 3.00±0.28a	C 1.00±0.00a	B 2.00±0.00b	0.629
	UBM	B 2.00±0.28b	C 1.00±0.00a	A 3.00±0.28a	
Neovascularization.	BP	B 2.00±0.00a	A 3.00±0.00a	A 3.00±0.28a	0.7263
	UBM	B 2.00±0.28a	A 3.00±0.28a	C 1.00±0.28b	

The results of the histopathological score of cellular infiltration along the experimental study confirmed significant differences ($P \leq 0.05$) in both treatment groups especially fibroblasts, at 2nd week PO in UBM treated animals compared with BP treated animals and progress with time. A well progression of the healing process in UBM treatment group compared to BP treatment group which was manifested by vascular granulation tissue formation, peripheral fibroblasts activity which produced dense collagen fibers formation and myofibroblasts infiltration. These results enclosed with (7) who confirmed that the using of UBM-implants enhanced the cellular integrity and induces early inflammatory cells infiltration in early phase of implantation for hernia repair in rabbits compared to the untreated tissues., as well as, (23) confirmed the ability of UBM type of bioscaffolds to facilitate the restoration of normal site appropriate tissue when used for hernia repair. While (24), observed that BP-implant were replaced with immature fibrous tissue and later newly developed of layer of connective tissue consisting of delicate collagen fibers after

The analysis results of ECM deposition and host degradation illustrated significant differences ($P \leq 0.05$) in both groups along the period of the study the mean values were lower at 2nd week and increased with time in both treatment groups. In addition in UBM-implants were faster than BP-implants, histopathological sections appeared the deposition or invited of new tissue to replace the scaffold in UBM group at 2nd week. While, in BP treated group the deposition showed periphery and not reach the center till 16th week post-implantation. Alternatively, histopathological score of presence study showed different between both treatment groups in inflammatory cells infiltration, host ECM deposition and matrix degradation in which UBM-implants were faster than BP-implants in degradation and host deposition, as well as, early cellular infiltration. These results enclosed with (25 and 26) referred that the degradation of BP implants occurs in uniform and gradual. While (27), confirmed that the UBM-implants rapidly degraded and turnover (remodeling). In addition (28), referred that the physical and chemical properties of biomaterials could influence on the intensity and duration of the inflammatory response. The

result of degradation of the implants showed significant differences ($P \leq 0.05$) in both group for each period of study. The mean values in both groups were lower at 2nd week and progress with time. The means in BP animals group were lower than UBM treated group for all periods. The result of fibrous encapsulation also recorded significant differences ($P \leq 0.05$) for both groups along the studied periods, that mean early encapsulation in UBM treated group compared to BP treated group that mean well incorporation were occur in early time in UBM group .

The analysis neovascularization score reflect the site of blood vessels were distributed, there were a significant differences ($P \leq 0.05$) along the studied period in both groups, while no significant differences between both groups at each period except that at 16th week which shows higher means in BP group than that in UBM group. In the current study showed early and faster degradation of UBM implants compared to BP implants, this fact may related to early infiltrations of inflammatory cells in UBM treatment group that may be enhanced more attraction to fibroblasts cells and collagen deposition. Realy bioscaffolds degradation can stimulates the releasing of the inherent bioactive constituents and promote host cells deposition. This fact was noticed by (29), referred the degradation process has a significant biological activity which stimulates the releasing of the inherent bioactive constituents subsequently promote tissue neovascularization and host-cell deposition (30 and 31) through encouraging cells attachment, proliferation, differentiation, maturation and angiogenesis .

Histopathological results also reflect the role of UBM implant in augmented remodeling process, it may be related to UBM and BP matrix composition and contains like growth factors or cytokines which retained in implant that causes change in the cells quantity and quality that's precipitated in the healing process and augment remodeling when compared to BP implants group. This fact explained by (22 and 32), indicated about the different in the products of each ECM that related to its source, these products have multiple biological properties including angiogenic, chemotactic and antibacterial

activity when liberating growth factors and cytokines during their degradation process by the host proteolytic enzymes .

The results of histopathological score of the present study appeared that UBM implant encapsulated started at 2nd week post-implantation prior to BP and progress with time to thick regular collagen fibers while in BP treated group showed it encapsulated by thin zone of mature fibrous connective tissues with calcium precipitation, irregular collagen fibers. This result support the idea of UBM implant cause or induced early initiation of inflammatory response and fibroblast attraction compared to BP implants. The same outcomes were recognized by (33 and 34), who proved that the biological scaffold encapsulation indicates an accelerated progression of the inflammatory response. In addition (24), confirmed that the dense fibrous capsule which forms around implant during remodeling was responsible for the firm incorporation between the implant and the host tissue, as well as, the zone of capsule did not interfere with the progression of implant degradation. All that change in the results of histological score included rate of inflammatory cells infiltration and implant degradation or deposition may be related to the change in the implant ultra-structure. This result agree with results of a study by (35 and 36), were mentioned that UBM implants allowed or augmented fibroblasts proliferation and collagen production due to it contains collagen more than 90 % of whole matrix, specially collagen type-III that consider a homo-trimeric fibrillar collagen which providing initial support for cell migration and adherence and facilitates ECM turnover and remodeling. While, BP implants augments neovascularization due to collagen type-I is the predominant component of pericardial tissue which arranged hierarchically in different levels, as well as, it has been shown to induce activation of mitogen activate protein kinase pathways that promote angiogenesis (37).

In addition, differences in collagen orientation between BP and UBM-implants may have a role in change of host response and healing process, BP matrix has a wavy shape of collagen fibers in all species, more intense curly appearance in bovine than other

species of mammals but, the collagen in UBM implants have unidirectional as showed by (38). While (39 and 40), explained, that the orientation of ECM components, such as collagen fibers, can profoundly influence the directed migration of cells, possibly by potentiating growth factor receptor signaling or by mechanically reinforcing cells migration. It is concluded that, the present study demonstrated that the only implantation technique of acellular BP and UBM were a simple, less cost-effective and safe methods with minor non-serious complications to support large abdominal wall hernias. In addition UBM implant superior than BP implant in enhance healing based on early initiation of inflammatory cells infiltration, fibroblast proliferation and marked collagen deposition, in addition to its early degradation, incorporation and remodeling.

References

1. Jettennavar, P.S., Kalmath, G.P. and Anilkumar, M.C. (2010). Ventral Abdominal Hernia in a Goat. *Veterinary World*, 3(2):93.
2. Das, B.C., Nath, B.K.; Pallab, M.S.; Mannan, A. and Biswas, D. (2012). Successful management of ventral abdominal hernia in goat: a case report. *International J. of Natural Sci.* 2(2):60-62
3. Cavallaro, A.; Lo Menzo, E.; Di Vita, M.; Zanghì, A.; Cavallaro, V. and Veroux, P.F. (2010). Use of biological meshes for abdominal wall reconstruction in highly contaminated fields. *World J. Gastroenterol.*, 16:1928-1933.
4. Abdin-Bey, M.R. and Ramadan, R.O. (2001). Retrospective Study of Hernias in Goats. *Scientific J. of King Faisal University (Basic and Applied Sciences)*. 2(1):77-88.
5. Song, Z.; Peng, Z.; Liu, Z. and Yang, J. (2013). Reconstruction of abdominal wall musculofascial defects with small intestinal submucosa scaffolds seeded with tenocytes in rats. *Tissue Engineering, Part A*, 19(13-14):1543–1553.
6. Jacob, B.P.; Hogle, N.J.; Durak, E.; Kim, T. and Fowler, D.L. (2007). Tissue ingrowth and bowel adhesion formation in animals comparative study polypropylene versus proceed versus parote composite. *Surgical Endoscopy*, 3(1):23-29.
7. Eberli, D.; Atala, A.; Yoo, J.J. (2011). One and four layer acellular bladder matrix for fascial tissue reconstruction. *J. of Materials Science.*, 22(3):741-751.
8. Rosen, M.J. (2010). Biological mesh for abdominal wall reconstruction; a critical appraisal. *Am. Surg.*, 76(1):1-6.
9. Freytes, D.O; Tullius, R.S. and Badylak, S.F. (2006). Effect of storage upon material properties of lyophilized porcine extracellular matrix derived from the urinary bladder. *J. of Biomedical Materials Res. Part B: Applied Biomaterials*, 78(2):327-333.
10. Bancroft, J.D. (2008). *Theory and Practice of histological technique*. 6th ed, Churchill Livingstone Elsevier, pp:8.
11. Valentin, JE. Badylak, JS.; McCabe, GP. and Badylak, SF. (2006). Extracellular matrix bioscaffolds for orthopaedic applications. A comparative histological study. *J. Bone Joint Surg. Am.*, 88(12):2673–2686.
12. Monteiro, J.A.; Delossantos, A.I.; Rodriguez, N.L.; Michael, P.P., Franz, G. and Wagner, C.H.T. (2013). Porcine incisional hernia model: Evaluation of biologically derived intact extracellular matrix repairs. *J of Tissue Eng.*, 4:1-7.
13. Holihan, J.L.; Nguyen, D.H.; Nguyen, M.T.; Mo, J.; Kao, L.S. and Liang, M.K. (2015). Mesh Location in open ventral hernia repair: A systematic review and network meta-analysis. *World J. Surg.*, 40(1):89-99.
14. Gurrado, A.; Franco, I.F.; Lissidini, G.; Greco, G.; De Fazio, M.; Pasculli, A. (2014). Impact of pericardium bovine patch (Tutomech®) on incisional hernia treatment in contaminated or potentially contaminated fields: retrospective comparative study. *Hernia*, 19(2):259-266.
15. Al-Asadi, R.N. (2005). A comparative study of three surgical techniques for reconstruction of experimentally

- induced large ventral hernia in goats. Ph.D. Thesis in Veterinary Medicine. Univ. of Baghdad, Baghdad-Iraq.
16. Hummadi, S.K. (2011). Hernioplasty of experimentally induced ventro-lateral hernia in bucks using silk suture versus polypropelen suture. MSc. Thesis in Veterinary Medicine. Univ. of Baghdad, Baghdad-Iraq.
 17. Bendavid, R. and Kux, M. (2001). Seromas In abdominal wall hernias: Principles and management. Edited by Bendavid, R.; Abrahamson, J.; Arregui, M.E.; Flament, J.B.; Phillips, E.H. New York: Springer, Pp:753-756.
 18. Schessel, S.; Ralph, G. and Ran, K. (2002). The management of postoperative disrupted abdominal wall. *Am. J. Surg.*, 184(3): 263-268.
 19. Westphalen, A.P.; Araújo, A.C.F.; Zacharias, P.; Rodrigues, E.S.; Fracaro, G.B. and Filho, G.D. (2015). Repair of large incisional hernias. To drain or not to drain. Randomized clinical trial. *Acta. Cir. Bras.*, 30(12): 31-38.
 20. Cole, W.C.; Balent, E.M.; Masella, P.C.; Kajiura, L.N.; Matsumoto, K.W. and Pierce, L.M. (2015). An experimental comparison of the effects of bacterial colonization on biologic and synthetic meshes. *Hernia*, 19(2):197–205.
 21. Köckerling, F.; Alam, N.N.; Narang, S.K.; Daniels, L.R. and Smart, N.J. (2015). Biological Meshes for Inguinal Hernia Repair–Review of the Literature. *Front.Surg.*,(2):48-54.
 22. Brennan, E.P.; Reing, J.; Chew, D.; Myers-Irvin, J. M.; Young, E.J. and Badylak, S.F. (2006). Antibacterial activity within degradation products of biological scaffolds composed of extracellular matrix. *Tissue Engineering*, 12:2949-2955.
 23. Sasse, K.C.; Warner, D.L.; Ackerman, E. and Brandt, J. (2016). Hiatal hernia repair with novel biological graft reinforcement. *JSLs.*, 20(2): e2016.00016.
 24. Abouelnasr, K.S.; Zaghoul, A.E. and Karrouf, G.I. (2014). Comparative evaluation of glycerolized bovine pericardium implant with prolene mesh for closure of large abdominal wall defects in dogs. *Iranian J. of Veterinary Research.*, 15(3) 211-217.
 25. Hafeez, Y.M.; Zuki, A.B.Z.; Yusof, N.; Asnah, H.; Loqman, M.Y. and Noordin, M.M. (2005). Effect of freeze-drying and gamma irradiation on biomechanical properties of bovine pericardium. *Cell and tissue banking.* 6(2): 85-89.
 26. Eva, G.; Babuci, S.; Tica, C.; Petrovici, V.; Nacu, V.; Ionescu, C. and Negru, I. (2017). Comparative cellular local response in abdominal defect plastic surgery with bovine pericardium and bovine fascia preserved in formaldehyde in experimental rabbits. *ARS Medica Tomitana*, 2(23):83-93.
 27. Remlinger, N.T.; Gilbert, T.W.; Yoshida, M.; Guest, B.N.; Hashizume, R. and Weaver, M.L. (2013). Urinary bladder matrix promotes site appropriate tissue formation following right ventricle outflow tract repair. *J of Organogenesis*, 9(3):149–160.
 28. Di Vita, G.; Milano, S.; Frazzetta, M.; Patti, R.; Palazzolo, V. and Barbera, C. (2000). Tension-free hernia repair is associated an increase in inflammatory response markers against the mesh. *Am J Surg.*, 180: 203-207..
 29. Badylak, S.F.; Freytes, D.O. and Gilbert, T.W. (2009). Extracellular matrix as a biological scaffold material: structure and function. *Acta. Biomater.*, 5:1-13. 321-342.
 30. Record, R.D.; Hillemonds, D.; Simmons, C.; Tullius, R.; Rickey, F.; Elmore, D. and Badylak, S.F. (2001). In vivo degradation of 14C-labeled small intestinal submucosa (SIS) when used for urinary bladder repair. *Biomaterials.* :2653–2659.
 31. Gilbert, T.W.; Stewart-Akers, A.M.; Simmons-Byrd, A. and Badylak, S.F. (2007). Degradation and remodeling of small intestinal sub mucosa in canine achilles tendon repair. *J. Bone Joint Surg. Am.*, 89:621-630.

32. Li, F.; Li, W.; Johnson, S.; Ingram, D.; Yoder, M. and Badylak, S. (2004). Low-molecular-weight peptides derived from extracellular matrix as chemo attractants for primary endothelial cells. *Endothelium*, 11: 199-206.
33. Anderson, JM.; Cook, G.; Costerton, B.; Hanson, SR.; Pettersen, AH. And Jacobsen, N. (2004). Host Reactions to Biomaterials and Their Evaluation. 2nd ed, Chapter four .Biomaterials Sci., Elsevier Inc, Pp: 26-87. 35. Anderson, J.M.; Rodriguez, A. and Change, D.T. (2008). Fogin Body Reaction to Biomaterials. *Semin Immunol.*, 20(2): 86–100.
34. Anderson, J.M.; Rodriguez, A. and Change, D.T. (2008). Fogin Body Reaction to Biomaterials. *Semin Immunol.*, 20(2): 86–100.
35. Brown, B.; Lindberg, K.; Reing, J.; Beer Stolz, B. and Badylak, S.F. (2006). The basement membrane component of biologic scaffolds derived from extracellular matrix .*Tissue Engineering*. 12(3): 519-526.
36. Gould, L.J. (2016). Topical Collagen-based biomaterials for chronic wounds: Rationale and clinical application. *Advances in Wound Care*. 5(1):19-31.
37. Mendoza-Novelo, B.; Alvarado-Castro, D.I.; Mata-Mata, J. L.; Cauch-Rodríguez, J. V.; Vega-González, A. and Jorge-Herrero, E. (2016) Stability and mechanical evaluation of bovine pericardium cross-linked with polyurethane prepolymer in aqueous medium. *Materials Science and Engineering: C.*, 33(4):2392-2398.
38. Ambra, L.; Berti, S.; Feleppa C.; Magistrelli, P.; Bonfante, P. and Falco, E. (2012). Use of bovine pericardium graft for abdominal wall reconstruction in contaminated fields. *World J. Gastrointest. Surg.*, 171:174-176.
39. Hynes R. O. (2009). The extracellular matrix: not just pretty fibrils. *Science*, 326:1216-1219.
40. Egeblad, M.; Rasch, MG. and Weaver, VM. (2010). Dynamic interplay between the collagen scaffold and tumor evolution. *Cell Biol.*, 22(5):697-706.

تقييم لأثنين من الأغشية الإحيائية لترميم الفتوق البطنية في ذكور الماعز

أريج كامل مهدي و أحمد حميد فتح الله البياتي
 فرع الجراحة والتوليد ، كلية الطب البيطري، جامعة بغداد، العراق.
 E-mail: kamelareg@yahoo.com.

الخلاصة

الهدف من هذه الدراسة هو تقدير التغيرات في ترميم الفتوق البطنية في ذكور الماعز العراقية باستخدام اثنين من الأغشية الإحيائية المأخوذة من الأبقار شغاف القلب والنسيج الغشائي للمثانة البولية من خلال الفحص النسيجي المرضي. حُضِرَ أسفل الخاصرة اليمنى لجميع ذكور الماعز ، التهذئة تمت باستخدام (2% الزايلازين هايدروكلورايد) بجرعة 0.2 ملغم \كغم حقنا بالعضلة و خدر مكان العملية بطريقة التخدير الترشيحي بشكل حرف اللام بالمقلوب باستخدام الليدوكاين هايدروكلورايد 2% بجرعة 8 ملغم \كغم. أحدث فتق بطني في 24 ذكر من الماعز من خلال قطع بياضوي لعضلات البطن لعمل حلقة الفتق (6×8سم) مع عدم اختراق غشاء البريتون. بعد 30 يوم من الإحداث قسمت ذكور الماعز الى مجموعتين متساويه. مجموعته المعالجه بغشاء شغاف القلب اللاخولي البقري ومجموعة الغشاء اللاخولي للمثانة البولية البقرية على التوالي وثبت الغشاء بطريقة الخياطة الأفقية المتقطعة المرتبة 2سم بعيدا عن حافة الحلقة بخيط (البولي بروبلين عدد 1). اخذت الخزع لأجل الفحص النسيجي المرضي عند الاسبوع 8 و 16 و 2 بعد المعالجة (4 حيوانات\فترة). كلا الغشائين نجحت في اعادة بناء الفتوق الكبيرة في ذكور الماعز بعدم استرجاع الفتق بعد العملية. فضلاً عن ان الفحص النسيجي المرضي بين ان غشاء المثانة البقري اللاخولي كان أفضل من غشاء شغاف القلب البقري في تسريع الالتئام مستندا على دور غشاء المثانة في تشجيع البدء المبكر لارتشاح الخلايا الالتهابية ، تكاثر خلايا الارومات الليفية وترسب الكولاجين المتميز اضافة الى التاكل ، الاندغام و اعادة البناء المبكر. مقارنة مع مجموعة غرسه نسيج شغاف القلب اللاخولي.

الكلمات المفتاحية: الفتق ، ذكور الماعز، الغرس الاحيائي، النسيجي المرضي