

Ecto and Endo Parasites Prevalence in Domestic Chickens in Sulaimani Region**Shadan Hassan Abdullah[®] and Aram Ahmad Mohammed**

Department of Microbiology, College Veterinary Medicine, Sulaimani University, Iraq

E-Mail: shadhanhq2004@yahoo.com

Accepted in: 10/12/2012

Summary

The study was conducted on 65 local adult chickens (*Gallus domesticus*) to investigate macro- and microscopically presence of external and internal parasites and their prevalence in Sulaimani region-Kurdistan/Iraq from May to July 2012. Results showed that 90.77 % out of total examined chickens were infested with ecto-parasites, out of that 81.36 % (48/59) were infested with lice such as (*Menacanthus stramineus*, *Goniocotes gallinae*, *Menopon gallinae*, *Goniodes gigas*, *Cuclotogaster heterographus*) and 62.72 (37/59) of it with larval stage of soft tick such as (*Argas persicus*). Mixed infestations with more than two ecto-parasite species were detected. On the other hand 89.23% out of 65 examined chickens were infected by internal parasites including nematodes and cestodes (*Heterakis gallinarum* which formed 81% and the remains were *Ascaridia galli*, *Cheilospirura hamulosa*, *Capillaria spp.*, *Raillietina spp.*, *Choanotaenia infundibulum*, *Amoebotaenia sphenoides*, *Hymenolepis carioca* and *Davianea proglottina*).

Keywords: Ectoparasite, Endoparasite, helmenthe, chicken.**Introduction**

In surveying the parasitological literature, it is found that every species of bird studied was infected with at least one, and often several species of parasites (1). Village chicken production is constrained by many extrinsic factors among which malnutrition, poor management and the absence of bio-security are outstanding. Losses have also been attributed to limited housing and veterinary care services. Furthermore, poor genetic potential due to lack of selection and predation are also potential threats to productivity (2). The domestic chicken feeds on a wide range of food substances this ranged from grains, fruits to insects which may harbor infective stage of parasites thereby predisposing them to parasite infection particularly gastro-intestinal parasites (3). Native fowls parasitic infections constitute a health and economic problem as well as a source of infection for industrial poultry, wild birds and man (4). Several species of lice mites and ticks make up the complex of potential external parasites of poultry, and different species of parasitic worms present in chicken. The physical damage caused by these pests and worms may result in lowered egg production, reduced weight gain, and carcass downgrading (5). Parasitic diseases caused by helminthes, arthropods and protozoa are reported in all most all species of domestic fowls (6).The

birds provide man with high nutritional value and other socio- economic benefits which cannot be emphasized (7). Small flocks are left scavenging around to obtain their food. Low productivity is mainly caused by diseases including parasitic diseases, suboptimal management, and lack of supplement feed (8).The study conducted to investigate the prevalence of different species of external and internal parasites in local chicken in Sulaimani region. Because there is no previous report exists about the prevalence of internal and external parasites in local chicken from the study area, therefore further studies are needed to determine the economic losses of multiple parasitic infections on chicken reared in backyard system and integrated parasite control approaches should be initiated to increase chicken productivity in the area.

Materials and Methods

The target population includes 65 domestic chickens of both sexes, to be examined for the presence of ecto-and endo parasites. Only adult chickens were selected for determination of parasites. The domestic chickens were purchased from the local market in Sulaimani evince. External parasites collected from different parts of the body around the wing, head, vent, feet, leg, wattle, comb and eyes. The legs, combs and featherless areas with

crest scrapped, and the scraping collected in 10% KOH (9). For collection of internal parasites trachea, bronchi and all parts of GIT including crop, esophagus, proventriculus, gizzard small and large intestine of each chicken was opened longitudinally, and all worms visible to the naked eye were collected using a pair of forceps, washed properly, grouped into different categories and preserved in 10% formalin. Scrapings from the intestinal mucosa were sieved for finding microscopic parasites (9). All adult worms and the discovered ecto-parasites were identified directly under the microscope by their morphological characteristics as described by identification keys of Soulsby (9).

Results and Discussion

In the present study, 90.77 % (59/65) of domestic chickens from the free-range production system harbored ecto-parasites at varied level and mixed infestations with more than two ecto-parasite species were also detected, and the postmortem examination showed, 89.23 % (58/65) of the chickens harbored gastro-intestinal parasites, including various species of helminthes parasites as shown in (Table,1).

Table, 1: Prevalence of ecto and end-parasites in domestic chickens in Sulaimani region.

No. of chickens examined	No. of infested chickens with ecto-parasites	Infestation rate (%)	No. of chickens infested with endo-parasites	Infection rate (%)
65	59	90.77	58	89.23

Similar to our finding (10) reported that 100% of the chickens, comprising both local and exotic breeds, from free-range production system harbored ecto-parasites in Nigeria, of the total 90.77 % , 81.36 % (48/59) were infested with different species of lice and 62.72 % (37/59) were infested with larval stage of soft tick *Argas persicus* (Table 2). Also (11) reported that lice were among the most prevalent ecto-parasite with 88% of examined chickens in Ethiopia, while (12) reported 19.3% ecto-parasite infestation in chicken in

Mosul/ Iraq, of these 12.5% with lice and 6.8% with soft tick *Argas persicus*.

Chickens are mainly infested with biting lice, these can irritate chickens and as a result they do not grow well and produce fewer eggs. They spend their entire lives on chickens and can be found on the skin around the vent and on the breast and thighs, they feed on skin and feathers(5), but sometimes may consume blood (8). Such birds could be seen pecking themselves and rolling on loose soil or ashes for relief were lice continuously on the birds (13).

Among *Mallophaga spp.* reported from birds, six species were reported in this survey, with different rates: *Menacanthus stramineus* was the most prevalent lice species with 72.92 % (35 /48), other identified lice species and their prevalence were *Goniocotes gallinae* 54.17% (26/48), *Goniodes gigas* 39.58% (19/48) *Menopon gallinae* 37.5% (18 /48), and *Cuclotogaster heterographus* 10.42% (5/48) as they shown in (Table, 3) and (Fig. 1).

Similar to the current study (14) was reported that *Menacanthus stramineus*, *Menopon gallinae*, *Goniodes gigas*, *Goniocotes gallinae*, and *Cuclotogaster heterographus* were the most commonly infesting lice of poultry, also in other studies elsewhere, like our result (15 and 16) reported that *Menacanthus stramineus* was the most prevalent lice species, which has detrimental effect on chicken, causing weight loss, decrease in egg production, irritation and loss of plumage (17).

Incidence rates remained distinctly higher on older birds and the intensity of infection remained distinctly higher during the summer months (18). Effects of ecto-parasites on poultry production including chewing lice are important causes of decrease in production (17), on the other hand subsistence poultry production serves as the only form of access to poultry meat and eggs for most people in rural areas (19).

Our result showed that 62.72% of examined chickens were infested with the larval stage of soft tick *Argas persicus*, (Fig. 2), also (13) reported in Zimbabwe that tick infestation were 30%. *Argas persicus* caused birds to abandon their sleeping areas especially during the wet warm months. The adults did not reside on the birds but ambushed them at night and getting to crevices during the day (13). When large

numbers of ticks occur on chickens they can cause weight loss and a decrease in egg production. They can cause paralysis and can also transmit a disease called spirochaetosis, which is a gut condition that leads to diarrhea (5).


No mite species were found in the scraping of different location of the body or on the feathers of the examined chickens. The high prevalence of ecto- parasites observed in this study, may be attributed to free ranging system which exposed the chickens to various ecto-parasites. Mungube, *et al.*, (20) had been shown that the occurrence of ecto-parasites were associated with poor hygiene in the farm/chicken house and the absence of parasite control practices.

Table, 2: Prevalence of ecto-parasites in domestic chickens in Sulaimani region.


Ecto-parasites	No. of infested	Infestation rate %
Lice	48	81.36
Soft tick	37	62.72

Table, 3: Prevalence of ecto-parasites species in domestic chickens in Sulaimani region.

Ectoparasites Species	No. of infested	Infestation rate %
<i>Argas persicus</i>	37	62.72
<i>Menacanthus stramineus</i>	35	72.92
<i>Goniocotes gallinae</i>	26	54.17
<i>Goniodes gigas</i>	19	39.58
<i>Menopon gallinae</i>	18	37.5
<i>Cuclotogaster heterographus</i>	5	10.42



Figure, 1:- Lice species :- a *Menacanthus stramineus* , b. *Cuclotogaster heterographus*, C. *Menopon gallinae* , d. *Goniocotes gallinae*, e. *Goniodes gigas*



Figure, 2: Larval stage of *Argas persicus*

Helminthes parasites of chickens are prevalent in many parts of the world (21), and prevalence studies have shown that almost 100% of rural chickens are infected with helminthic parasites (22). Results of current study showed that out of 65 local chicken examined by postmortem examination, 89.23 % (58/65) of the chickens harbored gastro-intestinal parasites, including various species of helminth parasites, as shown in Table (4). On the basis of morphological characteristics of parasites, nine types of helminthes were identified, which compromising 4 nematodes and 5 cestodes genera, all of the chickens examined had mixed infection. Similar to our finding in Zambia, (23) reported that helminthes prevalence were 95.2%, and (24) reported that helminthes prevalence in Mosul/ Iraq were 10.4%. According to (3) domestic chickens feed widely therefore, they become more predisposed to infection.

Heterakis gallinarum was the most prevalent nematode species in current study with 81% (47/58) (Fig. 3), also (25) reported the similar result with 93.3% of *H. gallinarum* among nematode spp. in Malaysia. The presence of *Heterakis gallinarum* poses the danger of enhanced transmission of *Histomonas meleagridis* to both susceptible turkeys and other poultry through shedding of the eggs in the environment.

Other recorded helminthes species was, *Ascaridia galli* with 31% (18/58) Figure, (5), this species had been reported in several studies as the commonest and most important helminth infection of poultry (6). Also *Cheilospirura hamulosa* 8.62% (5/58) (Fig. 4), and *Capillaria spp.* 1.72% (1/58) were other recorded nematode species in current study.

About the cestodes *Raillietina spp.* were the most prevalent one which found in 55.17 % (32/58), (Fig. 5). Similar to our finding in Eritrea (6) and in Iran (8) were reported that *Raillietina spp.* were the most prevalent cestode with the prevalence rate of (82.35%) and (60 %) respectively.

Prevalence of *Raillietina spp.* in all the groups of birds indicated that intermediate hosts are widely distributed and accessible even to the broilers from well managed farms, the habit of free range chickens of scratching any material including cow dung to look for among other things maggots accounted for the high prevalence of *Raillietina* whose intermediate hosts are maggots of *Musca domestica*. (13).

Choanotaenia infundibulum was the second prevalent cestode in the current study which was found in (18/58) chicken 31% (Fig. 6 and 7), whereas low frequency distribution were recorded for other cestods including: *Amoebotaenia sphenoides* 10.34% (6 /58), *Hymenolepis carioca* 6.9% (4/58), and *Daviania proglottina* 3.45% (2/58).

Syngamus trachea was absent in examined chicken of the study, this is in agreement with (6 and 26) who reported in their study that this parasite has low prevalence rate of infection compared to the other helminth parasites.

Helminth infestations are known to cause interference with host metabolism resulting in poor feed utilization and reduced growth rate as well as size and age at maturity (27) these are known common characteristics of village chickens. Although the chickens used in this survey appeared healthy, but they were with poor body condition, as mixed cestode/nematode infections created a significant weight loss in the range of 16% also suggests that helminth infections have a direct effect on weight (28). The results showed the body weight and body weight gain of birds from free-range system were significantly lower than of those kept in indoor-floor system while for feed conversion ratio (feed/gain) the reverse relation was observed (13).

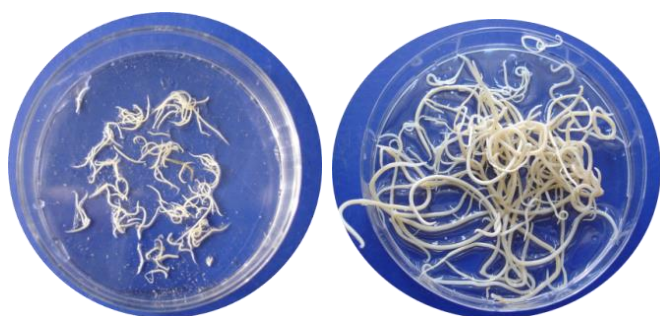
The presences of a few parasites do not usually cause a problem. However, large numbers can have a devastating effect on

growth, egg production, and over-all health. The concentration of parasite eggs in the chicken's environment is one factor which plays a major role in determining the severity of the infection. The chickens pick up the parasite eggs directly by ingesting contaminated feed, water, or litter or by eating snails, earthworms, or other insects (intermediate hosts) which can carry the eggs (29).

The high prevalence of helminthiasis observed shows the poor level of helminthic infection control practiced by the indigenous poultry keepers, which might affect the health status of the birds and their growth rates. Poultry keepers should be encouraged to prevent control and treat such cases (30).

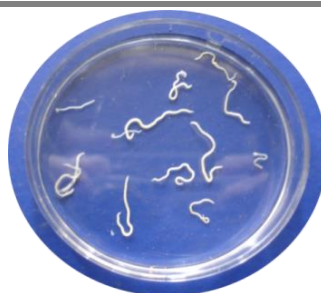Table 4: Prevalence of endo-parasites in domestic chickens in Sulaimani province

Helminthes species	No. of positive	% of positive
<i>Heterakis gallinarum</i>	47	81
<i>Ascaridia galli</i>	18	31
<i>Cheilospirura hamulosa</i>	5	8.62
<i>Capillaria spp.</i>	1	1.72
<i>Raillietina spp</i>	32	55.17
<i>Choanotaenia infundibulum</i>	18	31
<i>Amoebotaenia sphenoides</i>	6	10.34
<i>Hymenolepis carioca</i>	4	6.9
<i>Daviania proglottina</i>	2	3.45

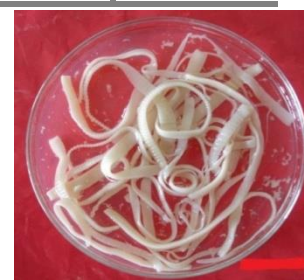

Figure, 3: *Heterakis gallinarum*.

Figure, 4: *Ascaridia galli*.



Figure, 5: *Raillietina spp.*



Figure, 6: Scolex of *Choanotaenia infundibulum*.



Figure, 7: Scolex of *Choanotaenia infundibulum*.

References

1. Manee, A. (2005). First Report of *Haemoproteus sp.* in Hill Mynah Blood in Thailand. *Inter. J. Poul. Sci.*, 4(8):523-525.
2. Calnek, B.N.; Barnes, H.J.; Beard, C.W.; Mc Dougald, L.R. and Saif, Y.M. (1997). *Diseases of Poultry*. Iowa State University Press, Ames, IOWA, PP:1080.
3. Oniye, S.J.; Audu P.A.; Adebote, D.A.; Kwaghe, B.B.; Ajanusi, O.J. and Nfor, M.B. (2001). Survey of Helminth Parasites of Laughing Dove (*Streptopeliasene galensis*) in Zaria, Nigeria. *African J. Natural Sci.*, 4:65-66
4. Anshnafi, H.E. and Shetu, Y. (2004). Study on gastrointestinal helminthes of local chicken in central Ethiopia. *Med. Vet.*, 155(10):504-507.
5. Mashishi, M.S. (2002). External parasites on chicken. Compiled by Directorate Agricultural Information Services. This publication is available on the web: www.nda.agric.za/publications
6. Ghebremariam, M.K.; Devarajan, S. and Ahmed, B. (2011). Prevalence of Helminth Parasites in Indigenous Fowls of Zoba

- Anseba of Eritrea, North-East Africa. *Vet. World*, 4(11):492-494.
7. Matur, B. M. (2002). Prevalence of some gastrointestinal parasites in pullets of chickens (*Gallus gallusdomestica*) in the Federal Capital Territory Abuja. *Nigeria J. Tropical Biosci.*, 2(1):78-82.
 8. Eslami, A.; Ghaemi, P. and Rahbari, S. (2009). Parasitic Infections of Free –Range Chickens from Go lest an Province. *Iranian J. Parasitol.*, 4(3):10-14.
 9. Soulsby, E.J. (1982). *Helminth, Arthropods and Protozoa of Domesticated Animals*. 7th Ed. Bailliere Tindall and Casse l. Ltd. London, PP: 763-765.
 10. Bala, A.Y.; Anka, S.A.; Waziri, A. and Shehu, H. (2011). Preliminary Survey of Ectoparasites Infesting Chickens (*Gallus domesticus*) in Four Areas of Sokoto Metropolis. *Nigerian J. and Applied Sci.*, 19(2):173-180.
 11. Mekuria, M. and Gezahegn, E. (2010). Prevalence of External parasite of poultry in intensive and backyard chicken farm at Wolayta Soddo town, Southern Ethiopia. *Vet. World*, 3(12):533-538.
 12. Al-Saffar, T.M. and Al-Mawla, E.D. (2008). Some hematological changes in chickens infected with ectoparasites in Mosul. *Iraqi J. Vet. Sci.*, 22(2):95-100.
 13. Dube, S. ;Zindi , P. ; Mbanga, J. and Dube, C. (2010). A Study of Scavenging Poultry Gastrointestinal and Ecto-parasites in Rural Areas of Matebele land Province, Zimbabwe. *Inter. J. Poul. Sci.*, 9(9):911-915.
 14. Nisarkhan, M.; Nadeem, M.; Iqbal, Z.; Sajid, M. S. and Abbas, R. Z.(2003). Review Lice Infestation in Poultry. *Inter. J. Agricul. Bio.*, 1560 -8530.05–2–213–216.
 15. Permin, A. ;Esmann, J. B. ;Hoj, C. H. ; Hove , T. and Mukaratirwa, S. (2002). Ecto- , Endo- and haemoparasites in free-range chicken in the Goromonzi district in Zimbabwe. *Prev. Vet. Med.*, 54:213-224.
 16. Mukaratirwa, S. and Hove, T. (2009). A survey of ecto parasites, cestodes and management of free range indigenous chicken in rural Zimbabwe. *J. S. Afr. Vet. Assoc.*, 80:188-191.
 17. Mukaratirwa, S. and Khumalo, M. P. (2012). Prevalence of chewing lice in free-range chicken from selected rural localities of KwaZulu-Natal, South Africa. *Intern. J. Appl. Res. Vet. Med.*, 10(1):85-89.
 18. Saxena, A.K.; Kumar, A. and Singh, S.K. (1995). Prevalence of *Menopon gallinae* Linne (Phthiraptera: Amblycera) on poultry birds of Garhwal. *J. Parasit. Dis.*, 19:69–72.
 19. Arkle, S.; Guy, J. and Sparagano, O. (2005). Antibody detection by ELISA in chicken infested with *Dermanyassus gallinae*. *Epidémiol et Santé Anim.*, 48:15-19.
 20. Mungube, O.E.; Bauni, S.M.; Tenhagen, B. A.; Wamae, L.W.; Nzioka, S. M.; Muhammed, L. and Nginyi, J. M. (2008). Prevalence of parasites of the local scavenging chickens in a selected semi-arid zone of eastern Kenya. *Tropical animal health Production*. 40:101-109.
 21. Matur, B. M.; Dawam, N.N. and Malann, Y. D. (2010). Gastrointestinal Helminth Parasites of Local and Exotic Chickens Slaughtered in Gwagwalada, Abuja (FCT), Nigeria. *New York Sci. J.*, 3(5):96–99.
 22. Polusen, J.; Permin, A.; Hindsbo, O.; Yelifari, L.; Nansen, P. and Bloch, P. (2000). Prevalence and distribution of Gastro-intestinal helmenths and Haemoparasites in young scavenging chicken in upper eastern region of Ghanna, West Africa. *Prev. Vet. Med.* 45(3-4):237-245.
 23. Phiri, I. K.; Phiri, A. M.; Chota, M.; Masuku, M. and Monrad, J. (2007). Prevalence and distribution of gastrointestinal helminthes and their effects on weight gain in free range chickens in Central Zambia. *Trop. Anim. Health Prod.*, 39(4):309-315.
 24. Shamaun, A. A. (2009). Surveillance of diseases in house reared chickens in Al-Hamdania, Mosul. *Iraqi J. Vet. Sci.*, 23(1): 113-115.
 25. Rahman, A. W.; Salim, H. and Ghause, M. S.(2009). Helminthic Parasites of Scavenging Chickens (*Gallus domesticus*) from Villages in Penang Island, Malaysia. *Trop. Life Sci. Res.*, 20(1):1-6.

26. Pam, V.A.; Daniel, L.N.; Brengshak, S.; Wai, M.S.; Omalu, C.J. and Ashi, R.D. (2006). The survey of intestinal parasites of local and exotic chickens slaughtered at Yankari market, Jos, Plateau State. J. Med. Pharmace. Sci., 2(3):27-33.
27. Nnadi, P.A; Kamalu, T. N. and Onah, D. N. (2007). The effect of dietary protein supplementation on the pathophysiology of *Haemonchus contortus* infection in West African Dwarf goat. Vet. Parasito., 148:256-261.
28. Ojok, L. (1993). Disease as important factor affecting increased poultry production in Uganda. Trop. Landwrit., 94:37-44.
29. Permin, A.; Bisgaard, M.; Frandsen, F.; Peartman, M.; Kold, J. and Nansen, P. (1999). The prevalence of gastrointestinal helminths in different poultry production systems. Br. Poult. Sci., 40(4):439-443.
30. Irungu, L.W.; Kimani, R.N., and Kisia, S.M. (2004). Helminth parasites in the intestinal tract of indigenous poultry in parts of Kenya. J. S. Afr. Vet. Assoc. 75(1):58-59.

انتشار الطفيليات الخارجية والداخلية في الدجاج المحلية في منطقة السليمانية

شادان حسن عبدالله و آرام أحمد محمد

فرع الاحياء المجهرية - كلية الطب البيطري - جامعة السليمانية - العراق

الخلاصة

أجريت الدراسة على 65 دجاجة محلية (*Gallus domesticus*) وتم الفحص العياني والمجهري لتحديد الاصابات الطفيلية الخارجية والداخلية و مدى انتشارها في محافظة السليمانية كردستان / العراق للفترة من أيار - تموز 2012. اظهرت النتائج بأنه 90% من العدد الكلي للدجاج المفحوص كان مصابا بالطفيليات الخارجية، منها 36. 81% (59/48) اصابة بالقمل (*Goniocotes gallinae*, *Menopon*, *Menacanthus stramineus*, *Cuclotogaster heterographus*), *Goniodes gigas* و 2. 72% (59/37) اصابة ببيرقات بالقراد اللين مثل (*Argas persicus*). كما تم اكتشاف وجود اصابة مختلطة باكثر من نوعين من الطفيليات الخارجية. وكذلك اظهرت النتائج بأنه 23. 89% من عدد الدجاج المفحوص 65 مصابا بالطفيليات الداخلية متضمننا الديدان الاسطوانية و الشريطية مثل (*Heterakis gallinarum*) و التي شكلت نسبة 81% منها و كانت البقية (*Ascaridia galli*, *Cheilospirura hamulosa*, *Capillaria spp.*, *Raillietina spp.*, *Choanotaenia infundibulum*, *Amoebotaenia sphenoides*, *Hymenolepis carioca* and *Davianea proglottina*)

الكلمات المفتاحية: طفيليات داخلية , طفيليات خارجية, ديدان, دجاج.