



# Investigation of the Relationship between Red Blood Cell Profiles and Electrocardiographic Changes in Dogs with Parvoviral Enteritis

Gizem S Boluk<sup>1</sup> , Aliye S Ozturk<sup>\*2</sup> 

<sup>1</sup>Hatay Mustafa Kemal University, Veterinary Faculty, Department of Internal Medicine, Hatay, Turkiye, <sup>2</sup>Hatay Mustafa Kemal University, Institute of Health Sciences, Department of Molecular Biochemistry and Genetic (Medicine), Hatay, Turkiye

## A B S T R A C T

Canine parvoviral enteritis (CPE) is a common viral disease in puppies that frequently results in severe gastrointestinal, hematological, and cardiac effects. This study aimed to look into the relationship between red blood cells parameters and ECG abnormalities, pointing out a potential connection between hematological changes and cardiac involvement in CPE. A total of 32 dogs of different breeds were incorporated in the data collected from animal hospital and classified into two main groups: 25 puppies with parvoviral enteritis and 7 healthy controls. The diseased group was divided into three subgroups based on ages and status of vaccination. Group 1: Eight puppies without vaccinations under 3 months of age; Group 2: Nine puppies without vaccinations over 3 months of age; Group 3: Eight puppies that had received vaccine but tested positive for parvovirus. Group 1 had microcytic hypochromic anemia and a significantly reduced hematocrit (%). Group 1 higher heart rate and shorter QT interval on the ECG were connected to red blood cell indices such as MCV, RDW, and MCH. Significant correlations were also established between the PR interval and RDW and between the QT/QTc interval and RDW, MCV, and MCH. In conclusion, this study revealed that hematological changes associated with canine parvoviral enteritis—especially changes in red blood cell indices such as RDW, MCV, and MCH—are strongly connected with electrocardiographic alterations. These results put forward that the change of these blood parameters could be created to variations in cardiac electrical activity during CPE. Accurate treatment strategies and monitoring of severity may be aided by an understanding of these links. Further studies are required to clarify the clinical usefulness of these hematological parameters as potential biomarkers in systemic viral infections.

**Keywords:** dog, ECG, Parvoviral enteritis, red blood cell indices

### \*Correspondence:

[adurusua@gmail.com](mailto:adurusua@gmail.com)

Received: xx July 2025

Revised: xx October 2025

Accepted: xx October 2025

Published online first: xx November 2025

### DOI:

<https://doi.org/10.30539/rbx7fm43>



This article is an open access distributed under the terms and conditions of the Creative Commons Attribution License (CC BY 4.0)

### Cite:

Boluk GS, Ozturk AS. Investigation of the relationship between red blood cell profiles and electrocardiographic changes in dogs with parvoviral enteritis. *Iraqi J. Vet. Med.* 2025;49(2):xx-xx.

## INTRODUCTION

Canine parvovirus (CPV) is a common and highly contagious pathogen that causes significant morbidity and mortality in dogs not having enough immunity (1). In susceptible dogs, the virus targets and eliminates promptly cells dividing, firstly impacting the intestinal epithelium and cell lines from bone marrow, thereby compromising both the gastrointestinal (GI) and

immune systems. In the absence of supportive care, infected dogs frequently experience septic shock and ultimately die. Puppies under five months of age are particularly vulnerable to CPV. This is related to either the lack of passive transmission of maternal antibodies or the suppression of a sufficient vaccination response (2).

In dogs infected with CPV-2, fever gradually occurs in the early stages, and as the infection progresses, it results in vomiting and diarrhea. Feces can alter consistency, turn

yellow, or include blood. Following infection, clinical symptoms usually appear 3–5 days later and continue for 5–7 days (3). Clinical signs associated with infected dogs include anorexia, depression, lethargy, severe or hemorrhagic diarrhea, stomach pain, fever, dehydration, and, in the worst cases, death (4). Abnormalities in red blood cell indices may affect myocardial oxygen delivery and electrophysiological stability, which may contribute to detectable ECG abnormalities since CPV infection frequently causes severe dehydration, electrolyte imbalances, and anemia from hemorrhagic enteritis (5,6).

The symptomatic treatment is comprised of antibiotics, hydration therapy, and antiemetics. The effect of antiviral therapy remains controversial (7). Adhering to hygiene guidelines and getting vaccinated are the most important ways to prevent this infection (8).

A method of diagnosis for evaluating cardiac abnormalities in a variety of illnesses and viral infections, is electrocardiography (ECG). Electrocardiography is accepted as a key diagnostic technique for identifying cardiac problems in dogs since it is noninvasive and economic (9).

The most of studies have assessed the connection between ECG findings and red blood cells indices. In particular, iron deficiency anemia (10, 11) and diarrhea (12) affect ECG changes. Anemia has been also correctly identified with AI-assisted programs that use the raw data of ECG (13).

This study is predicated on the new concept that, in dogs with parvoviral enteritis, ECG alterations might be associated with red blood cells (RBC) indices—an area that has not been studied before. ECG evaluation may be used as a noninvasive method to track the course and severity of CPV in dogs if a relationship is found between ECG variations and RBC indicators. Therefore, the purpose of this study was to assess the electrocardiographic parameters and red blood cells profile of puppies infected with CPV.

## MATERIALS AND METHODS

### Ethical Approval

The study was conducted with the approval of the Hatay Mustafa Kemal University Animal Experiments Local Ethics Committee under permit number 2020/04-28.

### Animals and Experimental Design

This study was conducted at Hatay Mustafa Kemal University, Veterinary Health Application and Research Center. The study included dogs that presented with CPV enteritis-like symptoms at the center, with a positive CPV-specific antigen result on a rapid test, and healthy dogs that had completed their vaccination program.

The study eliminated dogs that had parasitic diseases detected by fecal examination or those that tested positive for *Giardia* or coronavirus using a rapid fecal test (Uranotest® Parvo-Corona-*Giardia*, UranoVet, Spain).

Twenty-five dogs with parvoviral enteritis and seven healthy dogs, aged one month to one year, composed the

study materials. The following groups of dogs with parvoviral enteritis were created: Group I included 8 unvaccinated dogs under 3 months of age, Group II included 9 unvaccinated dogs over 3 months of age, Group III included 8 dogs that had received the first or second vaccine and tested positive for CPV in fecal samples, and Control group: Seven healthy dogs.

### Clinical Examinations

Both dogs with parvoviral enteritis and healthy dogs underwent thorough clinical and fecal investigations, and the results were documented. Following this, ECG recordings were made, and blood samples were taken from each dog cephalic vein in K<sub>3</sub>-EDTA tubes for examination via an automated blood count instrument (MS4e, Melet Schloesing Laboratoires, France) for assessment hematocrit % (HCT%), Red blood cells (RBC) count, hemoglobin (HGB), mean corpuscular volume (MCV), mean corpuscular hemoglobin (MCH), mean corpuscular hemoglobin concentration (MCHC), and red cell distribution width (RDW).

### ECG Recording

ECG examinations of all dogs were performed using a Nihon Kohden Corporation 110.2.140 device. ECGs were recorded at 50 mm/s and 5 mm/mV for the limb leads (Eindhoven method).

### Determination of Antigen Presence in Fecal Samples

Fecal samples from all dogs were tested for the parvovirus antigen via a rapid parvovirus antigen detection test (CPV Ag Test, Elabscience®). The test is a lateral flow immunoassay performed according to the manufacturer's instructions.

### Statistical Analysis

Statistical analysis was performed via IBM SPSS Statistics (version 22) software. The Shapiro–Wilk test was used to determine whether the data followed a normal distribution. Analysis of variance (ANOVA) was performed to evaluate group differences for parameters with a normal distribution; a difference was deemed statistically significant at  $P < 0.05$ . Correlations were visualized and tested via Spearman's correlation test. Group differences were considered statistically significant when  $P < 0.05$ . Spearman's rho correlation was used to assess correlations between the ECG results and RBC parameters; asterisks denote significance (\*  $P < 0.05$ , \*\*  $P < 0.01$ ).

## RESULTS

### Clinical Findings

Various levels of anorexia, dehydration above 7%, pale or hyperemic mucous membranes, extended capillary refill time, depression, lethargy, vomiting, and hemorrhagic diarrhea were among the clinical examination findings. For one to three days, the dogs were ill and received no care (Table 1).


Hypokalemia, hypochloremia, and hyponatremia common electrolyte abnormalities included in CPV (3), and in the current study, severe vomiting and diarrhea - responsible for these electrolyte abnormalities- were often observed clinical findings. These imbalances are associated with weakness and, in some dogs, mild cardiac signs

including tachycardia, weak peripheral pulses, and a prolonged capillary refill time.

The fecal samples tested positive for the CPV antigen. Healthy dogs underwent normal routine clinical examinations, and the CPV antigen test results were negative (**Figure 1**).

**Table 1. Descriptive of dogs specifically, parvoviral enteritis groups**

| Group | Breed              | Age (months) | Sex    | Vaccination                                       | Clinical signs  |
|-------|--------------------|--------------|--------|---|---|
| 1     | Mixed-breed dog    | 3            | Male   | None  | Watery diarrhea, hyperemic mucous membranes, dehydration, vomiting  |
| 1     | Anatolian Shepherd | 3            | Male   | None  | Watery diarrhea, hyperemic mucous membranes dehydration, lethargy, vomiting   |
| 1     | Mixed              | 2            | Male   | None  | Hemorrhagic Diarrhea, pale mucous membranes, dehydration, depression, lethargy, vomiting                                  |
| 1     | Anatolian Shepherd | 2            | Male   | None  | Watery diarrhea, dehydration, vomiting  |
| 1     | Mixed              | 1            | Male   | None  | Hemorrhagic Diarrhea, prolonged capillary refill time, pale mucous membranes, dehydration, depression, lethargy, vomiting |
| 1     | Mixed              | 2            | Male   | None  | Hemorrhagic Diarrhea, prolonged capillary refill time, pale mucous membranes, dehydration, depression, lethargy, vomiting |
| 1     | Bull Terrier       | 3            | Male   | None  | Hemorrhagic Diarrhea, pale mucous membranes   |
| 1     | Mixed              | 1            | Male   | None  | Hemorrhagic Diarrhea, prolonged capillary refill time, pale mucous membranes, dehydration, depression, lethargy, vomiting |
| 2     | Mixed              | 4            | Male   | None  | Hemorrhagic Diarrhea, pale mucous membranes, lethargy, vomiting   |
| 2     | Terrier            | 5            | Female | None  | Hemorrhagic Diarrhea, dehydration, vomiting   |
| 2     | Mixed breed        | 5            | Female | None  | Hemorrhagic Diarrhea, vomiting  |
| 2     | Mixed              | 4            | Male   | None  | Hemorrhagic Diarrhea, depression, lethargy, vomiting  |
| 2     | Mixed              | 4            | Male   | None  | Hemorrhagic Diarrhea, dehydration, depression   |
| 2     | Mixed              | 4            | Female | None  | Hemorrhagic Diarrhea, pale mucous membranes, vomiting   |
| 2     | Mixed              | 4            | Male   | None  | Watery diarrhea, hyperemic mucous membranes   |
| 2     | Siberian Husky     | 6            | Male   | None  | Watery diarrhea, hyperemic mucous membranes, vomiting   |
| 2     | Anatolian Shepherd | 6            | Female | None  | Watery diarrhea, hyperemic mucous membranes, dehydration,   |
| 3     | Rotweiler          | 4            | Male   | Received the first and second multivalent vaccine | Watery diarrhea, hyperemic mucous membranes, vomiting   |
| 3     | Rotweiler          | 8            | Male   | Received the first and second multivalent vaccine | Hemorrhagic Diarrhea, dehydration, vomiting   |
| 3     | Anatolian Shepherd | 4            | Male   | Received the first multivalent vaccine            | Hemorrhagic Diarrhea, depression  |
| 3     | Anatolian Shepherd | 4            | Female | Received the first multivalent vaccine            | Watery diarrhea, hyperemic mucous membranes, prolonged capillary refill time, dehydration, vomiting                       |
| 3     | Rotweiler          | 3            | Male   | Received the first and second multivalent vaccine | Watery diarrhea, hyperemic mucous membranes, vomiting   |
| 3     | Belgian Malinois   | 6            | Female | Received the first multivalent vaccine            | Watery diarrhea, hyperemic mucous membranes, dehydration,   |
| 3     | Siberian Husky     | 6            | Male   | Received the first and second multivalent vaccine | Watery diarrhea, hyperemic mucous membranes, prolonged capillary refill time, dehydration,                                |
| 3     | Anatolian Shepherd | 6            | Female | Received the first multivalent vaccine            | Hemorrhagic Diarrhea, dehydration, vomiting   |



**Figure 1. Positive result shown in panel A; negative result shown in panel B**

## RBC Indices

Compared with those of groups II and III, the HCT% value of group I was considerably lower ( $P < 0.05$ ). RBC

values were similar across all groups and within the reference limits. In contrast, although no significant difference was observed, HGB, MCV, MCH, and MCHC were lower in Group I than in the other three groups. In Group I,

RDW increased significantly and was significantly different from that of all the other groups ( $P < 0.001$ ) (Table 2).

### ECG Findings

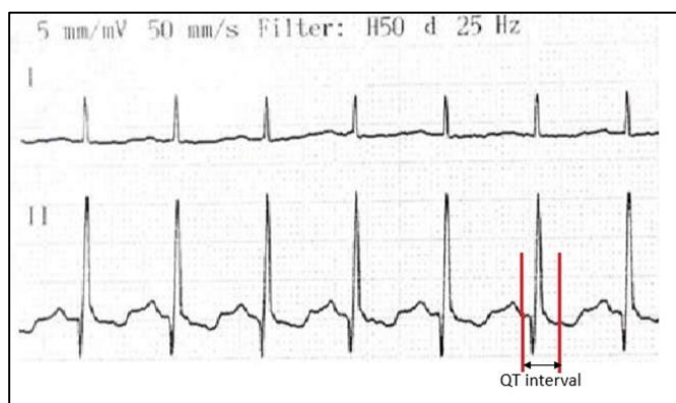
Compared with those in the other three groups, the heart rate in Group I increased ( $P < 0.01$ ), whereas the QT interval and QT/QTc interval decreased ( $P < 0.01$ ) (Figure

2). Additionally, in Group I, the duration of the PR interval decreased significantly ( $P < 0.01$ ) compared with those in the other three groups (Figure 3). Apart from these values, no significant differences were observed between the groups in terms of the amplitude and duration of the P-wave, QRS width, or QRS duration, as shown in Table 3.

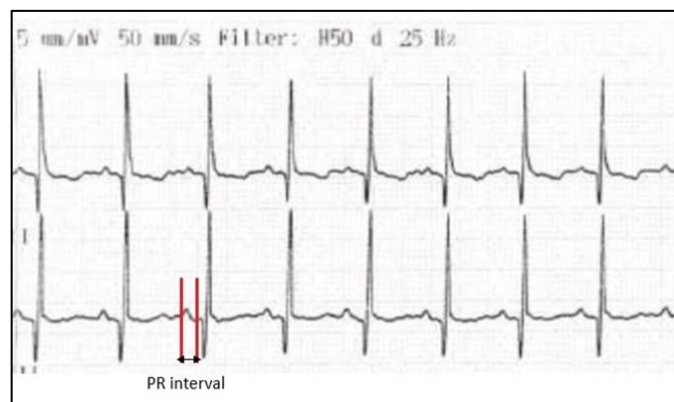
**Table 2.** Red blood cell indices in the healthy control and parvoviral enteritis groups

| Indices             | Group I (n=8)     | Group II (n=9)    | Group III (n=8)      | Control (n=7)        | P-value | Reference Range (14) |
|---------------------|-------------------|-------------------|----------------------|----------------------|---------|----------------------|
| RBC ( $10^{12}/L$ ) | $6.02 \pm 1.19$   | $7.05 \pm 1.27$   | $7.25 \pm 2.49$      | $5.66 \pm 0.64$      | 0.179   | 5.1-8.5              |
| HGB (g/dL)          | $10.6 \pm 3.55$   | $14.8 \pm 2.30$   | $16.3 \pm 10.2$      | $11.5 \pm 1.57$      | 0.181   | 11-19                |
| HCT (%)             | $36.8 \pm 8.83^c$ | $48.3 \pm 7.63^a$ | $47.1 \pm 12.6^{ab}$ | $37.8 \pm 4.43^{bc}$ | 0.027   | 39-56                |
| MCV (fL)            | $61.3 \pm 7.65$   | $68.8 \pm 3.51$   | $62.4 \pm 17.66$     | $67.1 \pm 7.27$      | 0.406   | 62-72                |
| MCH (pg)            | $17.4 \pm 4.00$   | $21.1 \pm 2.49$   | $20.5 \pm 3.34$      | $20.3 \pm 1.25$      | 0.082   | 20-27                |
| MCHC (g/L)          | $28.3 \pm 3.13$   | $30.6 \pm 2.28$   | $27.4 \pm 4.89$      | $30.6 \pm 3.02$      | 0.171   | 30-38                |
| RDW (%)             | $18.1 \pm 1.20^a$ | $14.2 \pm 1.09^b$ | $14.5 \pm 2.76^b$    | $14.0 \pm 1.34^b$    | 0.000   | 11-14                |

Values are mean $\pm$ SD; means with different superscripts within the same row are significantly different ( $P < 0.05$ )



**Figure 2.** The short QT interval. PR interval:  $6.8 \times 20 = 136$  ms (Since the ECG was recorded at 50 mm/s, the calculations were performed assuming that each small square has 20 ms in duration)



**Figure 3.** The short PR interval. PR interval:  $3.25 \times 20 = 65$  ms (Since the ECG was recorded at 50 mm/s, the calculations were performed assuming that each small square has 20 ms in duration)

**Table 3.** ECG findings in the healthy control and parvoviral enteritis groups

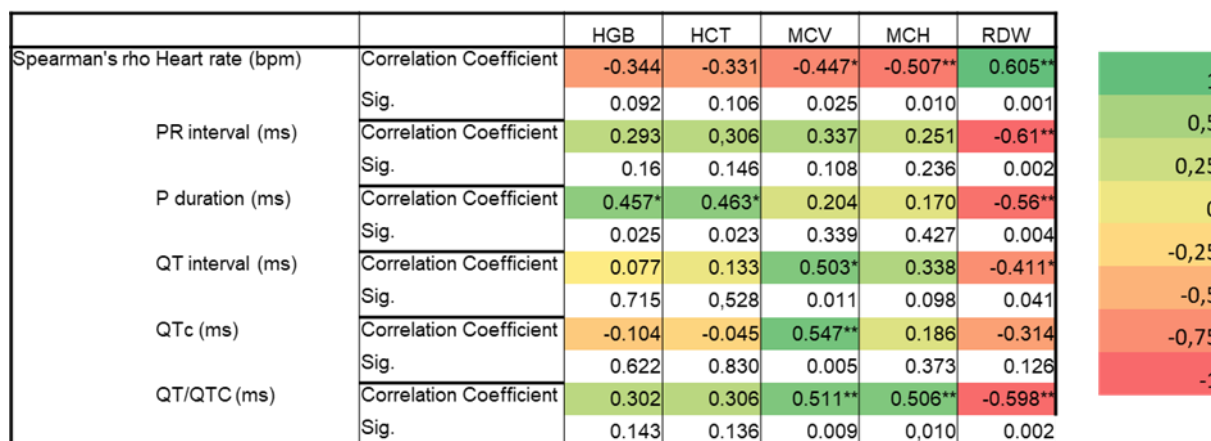
| Parameter        | Group I (n=8)     | Group II (n=9)    | Group III (n=8)   | Control (n=7)     | P-value | Reference Range (15) |
|------------------|-------------------|-------------------|-------------------|-------------------|---------|----------------------|
| Heart rate (bpm) | $206 \pm 15.5^a$  | $160 \pm 16.3^b$  | $174 \pm 24.3^b$  | $154 \pm 18.1^b$  | 0.000   | 70-200               |
| PR interval (ms) | $67.9 \pm 4.55^b$ | $92.9 \pm 10.9^a$ | $95.9 \pm 30.4^a$ | $105 \pm 16.6^a$  | 0.002   | 60-130               |
| P duration (ms)  | $45.9 \pm 3.27$   | $59.7 \pm 11.1$   | $65.1 \pm 35.7$   | $73.1 \pm 28.4$   | 0.140   | 48-65                |
| P wave amp. (mV) | $0.16 \pm 0.08$   | $0.19 \pm 0.05$   | $0.18 \pm 0.07$   | $0.11 \pm 0.09$   | 0.164   | <0.4                 |
| QRS dur (ms)     | $43.5 \pm 8.72$   | $46.4 \pm 9.44$   | $49.6 \pm 12.4$   | $49.3 \pm 9.96$   | 0.612   | <60                  |
| QT interval (ms) | $161 \pm 12.8^b$  | $191 \pm 10.7^a$  | $178 \pm 10.2^a$  | $197 \pm 27.3^a$  | 0.001   | 150-250              |
| QTc (ms)         | $191 \pm 14.4$    | $210 \pm 9.85$    | $200 \pm 14.2$    | $212 \pm 29.1$    | 0.086   | 150-240              |
| QRS width (ms)   | $56.2 \pm 21.8$   | $60.4 \pm 26.6$   | $37.8 \pm 28.8$   | $48.0 \pm 37.6$   | 0.399   | <70                  |
| QT/QTc (ms)      | $0.85 \pm 0.01^b$ | $0.92 \pm 0.03^a$ | $0.89 \pm 0.04^a$ | $0.93 \pm 0.03^a$ | 0.000   | 1-1.04               |

Values are mean $\pm$ SD; means with different superscripts within the same row are significantly different ( $P < 0.05$ )

### Correlations between RBC parameters and ECG

There was a negative correlation ( $P < 0.05$ ) between the MCV and HR. QT ( $P < 0.05$ ), QTc ( $P < 0.01$ ), and the QT/QTc ratio ( $P < 0.01$ ) were positively correlated with MCV. There was a negative correlation ( $P < 0.01$ ) between MCH and HR but a positive correlation ( $P < 0.01$ ) between MCH and QT/QTc. RDW was positively correlated with HR ( $P < 0.01$ )

and negatively correlated with the PR interval and P length ( $P < 0.01$ ). Additionally, there were negative correlations between RDW and the QT interval ( $P < 0.05$ ) and between RDW and the QT/QTc ratio ( $P < 0.01$ ). The results revealed a positive correlation ( $P < 0.05$ ) between HGB, HCT %, and P duration. The correlation heatmap is shown in Figure 4.



**Figure 4.** Correlation heatmap . Heatmap showing the Spearman correlation coefficients between the red blood cell parameters for the CPV groups. The correlation is represented by distinct colors, with green showing more positive correlations and red showing more negative correlations. \* $P < 0.05$ , \*\* $P < 0.01$

## DISCUSSION

This study investigated the electrocardiographic and hematological findings in dogs with parvoviral enteritis, with a focus on surveying possible correlations between these parameters. The results supported better understanding of the disease and generation of more successful treatment strategies.

In addition to the gastrointestinal symptoms in the CPE, hematological abnormalities, including changes in the composition of RBC, can also be detected (16). Systemic infection can lead to ECG abnormalities, particularly in young dogs with severe disease. These changes imply that cardiac function in CPV-infected puppies may also be influenced (17).

Compared with other hematological parameters, anemia has been observed to be a less widespread finding in CPE (18). Nevertheless, its prevalence may rise as the disease progresses (19). A reduction in HCT% has been associated with a 10.69% decrease in the rate of survival (20). In the present study, a decrease in HCT% was observed in puppies younger than 3 months, and this change was statistically significant.

MCH, MCHC, and RDW are classified RBC indices. Microcytic indices arise from changes in either hemoglobin or globin synthesis, and one of the most common causes is iron deficiency. Additionally, chronic diseases also can lead to microcytic or borderline microcytic anemia (21,22). In our study, the MCH, MCV, and MCHC were below the reference limits. The decline of these parameters exhibited a more mark in puppies younger than 3 months. However, there was no statistically significant difference between the groups.

Despite the absence of marked anemia in dogs with parvoviral enteritis, anemia is categorized as the microcytic hypochromic regenerative type, which is characterized by lower MCV and MCHC, particularly in those younger than 3 months in this study. An increase in the RDW also highlighted the presence of significant anisocytosis. These findings were consistent with those of previous studies (16,

23). The blood loss through gastrointestinal bleeding can be attributed to decrease in MCV and MCHC in dogs with parvoviral enteritis (24). Additionally, cytotoxic effects of the virus on bone marrow hematopoietic cells, particularly the acute phase of infection, lead to myeloid and erythroid hypoplasia (25,26). Because of ethical and clinical restrictions, bone marrow examination was outside the purview of this study. The observed hematological changes (variations in RBC indices) were indirect reflections of the virus's effect and consistent with the known bone marrow suppression it causes.

RBCs contain the iron-rich protein hemoglobin, which transports oxygen to tissues and gives blood its red hue. Anemia is characterized by a lack of RBCs or hemoglobin. It can be diagnosed with the aid of the MCHC test, which measurement of hemoglobin levels. Both low and high MCHC results can be signs of anemia. A low MCHC is often associated with iron deficiency anemia in puppies and may result from diseases that affect hemoglobin production (27). In the current study, despite normal RBC counts, the concurrent presence of low HGB and MCHC levels was considered a possible indicator of iron deficiency. A low MCHC in the absence of anemia may indicate iron deficiency prior to the development of anemia (28).

The diagnostic methods such as radiography, ultrasonography, echocardiography, computed tomography (CT), magnetic resonance imaging (MRI), and electrocardiography (ECG) are nonspecific tools for parvoviral enteritis (17, 29-31). For an ECG, vertical timing markers are recorded every 1.5 seconds above the guidelines at a paper speed of 50 mm/s. The number of small squares between two R waves (the R-R interval, which represents one heartbeat) is divided by 1500, or the number of large squares is divided by 300 to determine the heart rate (beats per minute) at a paper speed of 25 mm/s. In young dogs, the normal heart rate ranges from 70 to 200 beats per minute (17). ECG and other diagnostic tools can be helpful for assessing cardiac function in dogs with parvoviral enteritis; however, they cannot be used specifically to diagnose the disease. These methods are best



used in combination with clinical and laboratory tests to detect secondary effects and guide diagnosis.

Clinicians can identify disorders in heart function by comprehending waveforms, which are necessary for measuring the electrical activity of the heart. In ECG recording, three bipolar electrodes placed on the right and left forelimbs form leads I, II, and III to determine cardiac electrical activity (9,32). The cardiac muscle is depolarized, and after that, it is repolarized to create the ECG waveforms including P, QRS, and T (33). This may contribute to the accuracy of their evaluation conditions such as CPV, which can give rise to secondary cardiac problems. By carefully examining these waveforms, veterinarians can gain perception of the overall health of the heart and its rhythm (34). In the present study, ECG recordings were collected from limb derivations (Einthoven method), as reported by Martin (34), in dogs with parvoviral enteritis.

The electrical depolarization and repolarization of the left and right ventricles are represented by the QT interval. An extended QT interval is regarded as a risk factor for sudden death and a biomarker for ventricular tachycardias, including torsades de pointes. Numerous conditions, such as hypocalcemia, hypothermia, and several medicines, can result in prolonged QT (35). However, a shortened QT interval may result from genetic factors. Additionally, in nonpregnant women, a shortened QTc has been observed in cases of severe iron deficiency. A shortened QTc typically arises from increased sympathetic activity secondary to hyperdynamic circulation. Sympathetic activity shortens the repolarization phase, thereby shortening the QTc interval (36). In this study, shortened QT and QT/QTc (ms) intervals were identified for the first time in puppies aged <3 months with parvoviral enteritis. These situations could result in hyperdynamic cardiovascular response and elevated the activity of sympathetic nervous system, both of which play a role in a shortened QT interval. Furthermore, iron deficiency anemia—common in parvoviral enteritis—has been related with QTc shortening caused by alteration myocardial repolarization. These physiological changes, in both systemic inflammation and electrolyte imbalances, may enhance influence ventricular repolarization, thereby effecting the QT interval. Additionally, a positive correlation was detected between the MCV and the QT interval, as well as between the MCV and the QTc (ms). A positive correlation between the QT/QTc ratio and both the MCV and MCH was revealed in this study. There was a negative correlation between RDW and the QT interval and between RDW and the QT/QTc. The implications in their findings suggest that the cause of the short QT interval is related to physiological dysfunctions associated with decreased levels of RBC indices.

Sinus tachycardia is the term used to describe an increase in heart rate that is linked to an elevated sympathetic tone. Sinus tachycardia is caused by dehydration, hypotension, anemia, hypoxemia, pain, stress, anxiety, and excitement (37). The sympathetic stimulation and enhanced atrioventricular nodal conduction may contributed to the shortening of the PR interval (38). The PR interval is measured from the beginning of the P wave

to the beginning of the QRS complex. The normal PR intervals range from 0.06 and 0.13 seconds in dogs (39). In the current study, the high heart rate and shortened PR interval were demonstrated to be caused by dehydration from diarrhea or the presence of anemia. Although the PR interval was within the reference ranges, it was lower compared to the other groups, and the difference was statistically significant. The inverse relationships among MCV, MCH, and HR lend credence to this. On the other hand, increase in RDW that occurred in response to a decrease in RBCs were linked to the positive correlation between HR and RDW. Similarly, the observed positive correlation between P duration and HGB and HCT % suggested that this correlation may be related to underlying physiological disturbances. Additionally, a negative correlation was observed between the PR interval and RDW as well as between the P duration and RDW.

In conclusion, this study demonstrated a distinct correlation between RBC indices and electrocardiographic measures, including heart rate, P-wave duration, and the QT/QTc and PR intervals, in puppies with CPV. To support the disease monitoring and treatment for affected dogs, ECGs may be a helpful, noninvasive tool.

This study has several limitations. The small sample size may limit the generalization of the results. In addition, the absence of advanced diagnostic methods, such as echocardiography or bone marrow analysis, reduces the ability to assess underlying pathophysiological mechanisms fully. Further studies with large population and more comprehensive diagnostic approaches are needed to better clarify the clinical correlation of these biomarkers.

## ACKNOWLEDGEMENTS

This study was supported by the Hatay Mustafa University Scientific Research Projects Centre, Hatay, Turkey. We would like to thank Hatay Mustafa University Scientific Research Projects Centre for supporting this study. This article was derived from Boluk GS master's thesis.

## CONFLICT OF INTEREST

The authors declare no conflict of interest.

## AUTHOR CONTRIBUTIONS

Conceptualization, Methodology, Investigation, Resources, Writing – Original Draft, Writing – Review & Editing: A.S.O.; Writing – Review & Editing, Investigation, Resources: G.S.B. All authors have read and approved the final version of the manuscript.

## ARTIFICIAL INTELLIGENT DECLARATION

The authors declare that they are responsible for the accuracy and integrity of all content of the manuscript, including part generated by AI, and it is not used as a co-author.

## REFERENCES

- Hadden H, & Herron M. Effects of Deferred Puppy Intake on Incidence of Canine Parvovirus Infection and Survival: A Community Case Study. JSMCAH. 2025;4(1):1-6. [10.56771/jsmcah.v4.109](#)
- Zhou H, Cui K, Su X, Zhang H, Xiao B, Li S, et al. Overview of Recent Advances in Canine Parvovirus Research: Current Status and Future Perspectives. Microorganisms. 2024;13(1):47. [10.3390/microorganisms13010047](#)
- Tuteja D, Banu K, Mondal B. Canine parvovirology - A brief updated review on structural biology, occurrence, pathogenesis, clinical diagnosis, treatment and prevention. Comp Immunol Microbiol Infect Dis. 2022;82. [10.1016/j.cimid.2022.101765](#)
- Ahmed AF, Odeisho SM, Karim ZA. Detection of Canine Parvovirus in Baghdad city by PCR technique. Proceeding of the Eleventh Veterinary Scientific Conference. 2012;36(0E):95-98. [10.30539/iraqijvm.v36i0E.387](#)
- Gulersoy E, Ok M, Yildiz R, Koral E, Ider M, Sevinc M, et al. Assessment of intestinal and cardiac-related biomarkers in dogs with parvoviral enteritis. Pol J Vet Sci. 2020;23(2):211-219. [10.24425/pjvs.2020.133635](#)
- Apoorva R, Premalatha N, Balakrishnan S, Kumaresan A, Yogeshpriya S. Prognostic Value of Cardiac Biomarker and Electrocardiography of Canine Parvovirus-2 Affected Kanni Pups: A Study of Eight Cases. Appl Biol Res. 2022;24(2):251-254. [10.5958/0974-4517.2022.00029.5](#)
- Mia MM, Hasan M. Update on canine parvovirus infection: a review from the literature. Veterinary Sciences: Research and Reviews. 2021;7:92-100. [10.17582/journal.vsr/2021.7.2.92.100](#)
- Decaro N, Buonavoglia C, Barrs VR. Canine parvovirus vaccination and immunization failures: are we far from disease eradication? Vet. Microbiol. 2020; 247:108760
- Tilley LP, Smith FWK, Oyama MA, and Sleeper MM. Manual of Canine and Feline Cardiology (4th Edn.). 2008; Elsevier, St. Louis, Missouri, USA.
- Kumiega E, A Kobak K, Noszczyk-Nowak A, Kasztura M. Iron parameters analysis in dogs with myxomatous mitral valve disease. BMC Vet Res. 2024;20(1):210. [10.1186/s12917-024-04071-2](#)
- Kumar N, Gupta SK, Singh RK. Electrocardiographic changes in anemic patients: diagnostic value and correlation with hematological severity. Eur J Cardiovasc Med. 2025;15:664-9. [10.5083/ejcm/25-02-75](#)
- Alkhafaji JJ, Mahmood AK. Electrocardiographic changes in Awassi diarrheic suckling lambs in Iraq. Iraqi J Vet Med 2019;43(1): 26-33. [10.30539/iraqijvm.v43i1.467](#)
- Kwon JM, Cho Y, Jeon KH, Cho S, Kim KH, Baek SD, et al. A deep learning algorithm to detect anemia with ECGs: a retrospective, multicenter study. Lancet Digit Health. 2020;2:e358-e367. [10.1016/S2589-7500\(20\)30108-4](#)
- Kabakci R. and Kara E. The Alterations of erythrocyte osmotic fragility and hematological parameters in puppies with parvoviral enteritis in Kirikkale, Türkiye. Int J Vet Anim Res. 2023;6:66-71. [10.5281/zenodo.8319020](#)
- Rana A, Sharma P. Electrocardiographic evaluation of Canine Parvovirus infection. Himachal J Agric Res. 2023;49(2):238-243. [https://hjar.org/index.php/hjar/article/view/172493](#)
- Hassan MSM, Abdel-Saeed H, Abd El Aziz Ahmed K, Abdou OM. Clinical and hemato-biochemical studies on canine anemia. Adv Anim Vet Sci. 2022;10:838-844. [10.17582/journal.aavs/2022/10.4.838.844](#)
- Er C, Ok M. Levels of cardiac biomarkers and coagulation profiles in dogs with parvoviral enteritis. Kafkas Univ Vet Fak Derg. 2015; 21:383-388. [10.9775/kvfd.2014.12575](#)
- Olaifa O, Rachel KA, Akanbi OB, Ibironke OC, Victor T. Hematological and serum chemistry of canine parvoviral enteritis in diverse breeds of dogs. Media Kedokteran Hewan. 2025;36(1):21-29. [10.20473/mkh.v36i1.2025.21-29](#)
- Alves FS, Alonso FH, Horta RS, Barbosa BC, Beier S, Paes PRO. Prognostic values of physical and hematological parameters of dogs naturally infected with parvovirus PVC-2: retrospective study of 103 cases. ARQ BRAS MED VET ZOO. 2020;2127-2134. DOI: 10.1590/1678-4162-11517
- Chalifoux NV, Parker SE, Cosford KL. Prognostic indicators at presentation for canine parvoviral enteritis: 322 cases (2001-2018). J Vet Emerg Crit Care. 2021; 31: 402-413. 10.1111/vec.13052
- Chaudhry HS, Kasarla MR. Microcytic Hypochromic Anemia. [Updated 2023 Aug 14]. In: StatPearls [Internet]. Treasure Island (FL): StatPearls Publishing; 2025 Jan-. Available from: <https://www.ncbi.nlm.nih.gov/books/NBK470252/>
- Merck Manual Professional Version. Evaluation of anemia [Internet]. Merck & Co., Inc.; Reviewed/Revised May 2024 [cited 2025 Mar 15]. Available from: [https://www.merckmanuals.com/professional/hematology-and-oncology/approach-to-the-patient-with-anemia/evaluation-of-anemia#Testing\\_v968595](https://www.merckmanuals.com/professional/hematology-and-oncology/approach-to-the-patient-with-anemia/evaluation-of-anemia#Testing_v968595)
- Turanoglu, B., Alan, E. M., Or, E., Koenhems, L. Evaluation of red cell distribution with in dogs with parvoviral enteritis: a retrospective study. JIVS (Vetexpo-2022 Special Issue). 2023; 154-154.
- Khare DS, Gupta DK, Shukla PC, Das G, Meena NS, Khare RK. Clinical and hemato-biochemical changes in canine parvovirus infection. J Pharmacogn Phytochem. 2020;9(4):1601-1604. DOI:10.13140/RG.2.2.35705.29285
- Hosein H, El-Sherif A, Fadl S, Ewies S, Roubay S. Clinico-pathological and Molecular Investigations with Evidence of Circulation of a Highly Virulent Canine Parvovirus (CPV) Serotype in Egypt. EJVS. 2024; 1-13. doi: 10.21608/ejvs.2024.332240.2459
- Ekinci G, Tüfekçi E, Abozaid A, Kökkaya S, Sayar E, Onmaz AC, et al. Efficacy of Filgrastim in Canine Parvoviral Enteritis Accompanied by Severe Leukopenia. Kafkas Univ Vet Fak Derg. 2024; 30 (4): 433-443. 10.9775/kvfd.2023.31456
- Saxon B. The Anemic Patient: Update on Diagnosis and Treatment. Conferencia Veterinaria Latinoamericana 2022, Perú, Lima 05 al 08 JUNIO 2022 16.
- Rivera AKB, Latorre AAE, Nakamura K, Seino K. Using complete blood count parameters in the diagnosis of iron deficiency and iron deficiency anemia in Filipino women. J Rural Med. 2023; 18(2):79-86. 10.2185/jrm.2022-047.
- Mazzafarro EM. Update on Canine Parvoviral Enteritis. Vet Clin Small Anim Pract. 2020; 50:1307-1325. 10.1016/j.cvsm.2020.07.008.
- Parrish CR, Sykes JE. Canine Parvovirus Infections and Other Viral Enteritides, Editor(s): Jane E. Sykes, Greene's Infectious Diseases of the Dog and Cat (Fifth Edition), W.B. Saunders, 2021; 341-351, ISBN 9780323509343
- De Abreu CB, Muzzi RA, de Oliveira LE, Schulien T, Coelho MDR et al. Systolic dysfunction by two-dimensional speckle tracking echocardiography in dogs with parvoviral enteritis. J Vet Cardiol. 2021; 34: 93-104, 2021. 10.1016/j.jvc.2021.01.006
- Sleeper MM. An introduction to reading ECGs in veterinary patients. dvm360. 2020;51(2):42-6. Available from: [https://cdn.sanity.io/files/0vv8moc6/dvm360/4d1d96a51dec1523350e157001bfadda30b7654e.pdf/0220\\_dvm360\\_Full\\_Issue\\_Feb\\_2020\\_web.pdf](https://cdn.sanity.io/files/0vv8moc6/dvm360/4d1d96a51dec1523350e157001bfadda30b7654e.pdf/0220_dvm360_Full_Issue_Feb_2020_web.pdf)
- Romito G, Castagna P, Sabetti MC, Cipone M. Electrocardiographic findings in healthy Cavalier King Charles Spaniels, Pugs, and English Bulldogs. J Am Vet Med Assoc. 2023;261(5):688-695. 10.2460/javma.22.12.0542.
- Saritha G, Swetha K, Reddy BS. Studies on Electrocardiographic Changes in Dogs with Canine Parvovirus Infection. Int J Curr Microbiol App Sci. 2022;11(11):2319-7706. <https://doi.org/10.20546/ijcmas.2022.1111.030>
- Jankelson L, Karam G, Becker ML, Chinitz LA, Tsai MC. QT prolongation, torsades de pointes, and sudden death with short courses of chloroquine or hydroxychloroquine as used in COVID-19: A systematic review. Heart Rhythm. 2020; 17(9):1472-1479. 10.1016/j.hrthm.2020.05.008.
- Khode VH, Kammar KF. QTc changes in nonpregnant females with severe iron deficiency anemia. JCDR. 2012;6(5). JCDR/2012/3622:2216

37. Blackwell DJ, Schmeckpeper J, Knollmann BC. Animal Models to Study Cardiac Arrhythmias. *Circ Res.* 2022; 130(12):1926-1964. doi: 10.1161/CIRCRESAHA.122.320258
38. Prystowsky EN, Gilge JL. Atrioventricular Conduction: Physiology and Autonomic Influences. *Cardiol Clin.* 2023; 41(3):293-306. doi: 10.1016/j.ccl.2023.03.015.
39. Romito G, Pelle NG, Cipone M. ECG of the Month. *J Am Vet Med Assoc.* 2022; 260(15):1-3. doi: 10.2460/javma.21.06.0305