

GLOBULE LEUKOCYTES AND MAST CELLS IN BILE DUCTS OF SHEEP WITH CHRONIC FASCIOLIASIS

G.S. Mahmoud and M.M. Shakir, Department of Veterinary Pathology, College of Veterinary Medicine, University of Baghdad, Baghdad, Iraq.

SUMMARY

Globule leukocytes were detected in the epithelial mucosa of the biliary system of sheep infected with liver flukes. Histochemical investigations revealed cytochemical similarities between the globule leukocytes and mast cells of the biliary system. Both the intracytoplasmic granules of the mast cells and the globules of the globule leukocytes contained a sulphated acidmucopolysacchride associated with a highly basic protein.

INTRODUCTION

Both the mast cell and the globule leukocyte possess and intracytoplasmic acidophilic granules (Mahmoud and Pirie, 1982). The mast cells are normal elements of connective tissue, while the globule leukocyte is absent in the tissues of parasite-free animals (Wells, 1962). In parasitic infections, the globule leukocytes are frequent within the epithelium of different organs (Fernex, 1968).

The appearance of globule leukocytes in the wall of bile ducts has been studied in fascioliasis of cattle (Murray, 1968), sheep (Rahko, 1970), goat (Rahko, 1972) and mice (Rahko, 1972). So far no studies have been carried out on these cells in sheep. Therefore, this paper deals with the detection of the globule leukocytes and mast cells in the biliary system of sheep affected with the chronic fascioliasis. The histochemistry of these cells and the relationship between them were also discussed.

MATERIALS AND METHODS

The materials consist of livers of sheep naturally-infected with fascioliasis. Specimens of tissue from various sections of the bile ducts were prepared according to histopathological and histochemical investigations as described by Mahmoud and Pirie (1982).

RESULTS

The globule leukocytes were demonstrated in large number within the mucosa of the bile ducts of sheep (Fig. 1). The histochemical reactions of the mast cells and globule leukocytes in sheep biliary system appeared to be identical to those of the corresponding cells in respiratory tract of sheep.

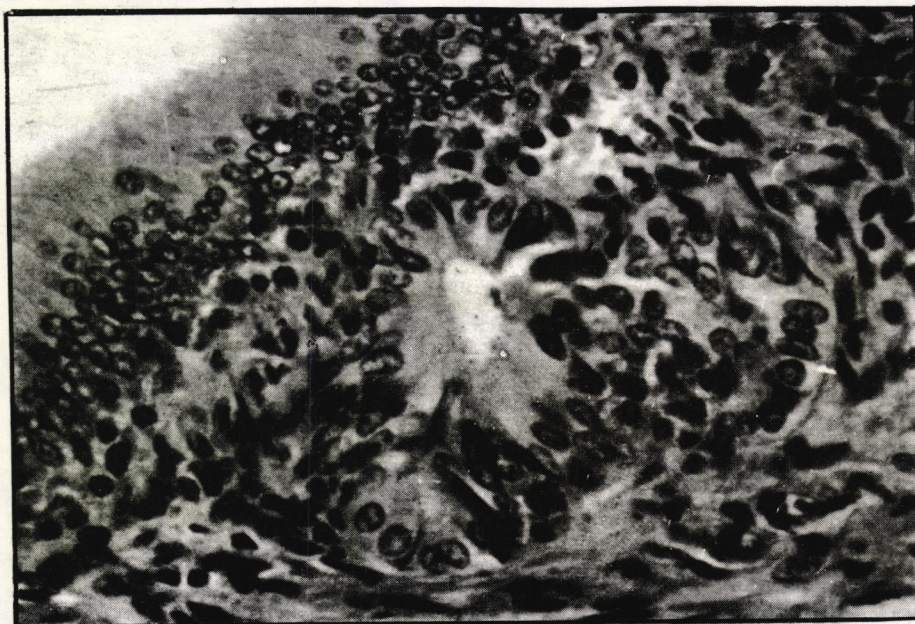


Figure 1. Mucosa of a bile duct of sheep liver with chronic fascioliasis, showing large number of globule leukocytes among epithelium and in the lamina propria. Note the regular intracytoplasmic globules. H&E. X250.

The small granules of the mast cells and the larger granules of the globule leukocytes appeared to contain a sulphated acid mucopolysaccharide. However, the histochemical methods when used at different pH levels revealed somewhat varying features in the mucopolysaccharides in both types of granules. With toluidine blue, both types of granules were metachromatic at pH 4.0, while at higher acidity (pH 0.5) the globules of globule leukocytes remained colourless. Furthermore, at still higher acidity (pH 0.3), the globules of globule leukocytes bound Alcian blue to a varying extent when counterstained with safranin.

On the other hand, the granules of mast cells mostly stained with safranin.

Employing the Biebrich scarlet reaction, the granules of both types of cells appeared to contain a highly basic protein. However, different staining methods revealed that the granules of mast cells mostly stained basophilic, but the globules of globule leukocytes were acidophilic. Furthermore, both types of granules were weakly PAS-positive. They showed a slight reaction with Best's carmine but no reaction with Mayer's mucicarmine.

DISCUSSION

According to the present histochemical study, the cytochemical properties of the mast cell and the globule leukocytes in biliary tract system of sheep with chronic fascioliasis, they appear to be identical to those of the corresponding cells in respiratory tract of sheep (Mahmoud and Pirie, 1982). Furthermore, this investigation revealed a significant cytochemical relationship between the mast cell and the globule leukocyte. Thus the granules of both types of cells appeared to contain a sulphated acid mucopolysacchride associated with a highly basic protein.

However, the observed variations in the demonstrated reactions indicate the existence of certain structural differences in the mucopolysacchride encountered in the mast cell and that of the globule leukocytes.

REFERENCES

- Fernex, M. (1968). The mast cell system. Its relationship to Atherosclerosis, Fibrosis and Eosinophils. S. Karger. Basel
- Mahmoud, G.S. and H.M. Pirie (1982): Ovine bronchopulmonary globule leukocyte. I. Morphological and cytochemical studies. Zbl. Vet. Med. C. Anat. Histol. Embryol. II:205-212
- Murray, M. (1968). The globule leukocytes and its derivation from the subepithelial mast cells. Lab. Invest., 19:222-229.
- Rahko, T. (1970): Mast cells and globule leukocytes in bile ducts of cattle and sheep with Fascioliasis and Dicrocoeliasis. Nytt. Mag. Zool. 18:111-112
- Rahko, T. (1971). Globule leukocyte and mast cells in mice. Ph.D. Thesis. Annals Academia Scientiarum Fennicae, A5, 148, I.
- Rahko, T. (1972). Studies on the pathology of Dicrocoeliasis and fascioliasis in the goat. III. The histochemistry of mast cells and globule leukocytes. Acta. Scand. 13: 575-584.

كريات الدم البيض الكروية والخلايا البدينة في قناة الصفراء

للاغنام المصابة بديدان الكبد المزمن

غيات صالح محمود، مثنى محمود شاكر، فرع الامراض والطب العدلي، كلية الطب
البيطري، جامعة بغداد.

الخلاصة

لقد تم العثور على كريات الدم البيض الكروية في ظهارة مخاطية القنوات
الصفراوية لكبد الاغنام المصابة بديدان الكبد المزمن. ان الكشوفات
الكيمائية النسيجية اثبتت التشابه بين هذه الخلايا والخلايا البدينة وان
صبغات هاتين الخليتين تحتوي على مركبات مخاطية المتعدد السكريد الحامضي
مع البروتين القاعدي.