

## THORACIC SURGERY IN EQUINES

N.M. Jawad, Department of Surgery, College of Veterinary Medicine, University of Baghdad, Al-Ameria, Baghdad, Iraq.

### SUMMARY

Unilateral thoracotomy was performed in twenty nine donkeys and twenty five horses aged 4-10 years without an aid of positive respirator. Surgical pneumothorax did not endanger the life of patient. Eighteen horses and twenty four donkeys became clinically normal and the wounds were completely healed within 30 days, however, two horses dies due to pleurisy. Five horses and five donkeys were killed and subjected to anatomical studies to find out if there is a communication between the plural sacs or if the mediastinum is not strong enough to resist pressure. Observations indicate that there is no communication between the two plural sacs and that the mediastinum is strong enough to resist the difference in the pressure of the plural sacs and thus permit open thoracic surgery in equine without employing inflating pump.

### INTRODUCTION

There is communication between the two plural sacs of a very thin mediastinum (ciliga *et. al.*, 1966; Nickel *et. al.*, 1973; Getty, 1975). O'connor (1958) mentioned that when air enters the chest of a horse, it invades both plural sacs through the communication in the

posterior mediastinum, leading to sudden death due to the collapse of both lungs. King (1976) reported that it is impossible to perform thoracic surgery unless the lungs are inflated by a pump, because of the difference in pressure on each side of the mediastinum during inspiration is sufficiently great to rupture it sooner rather than later.

A successful treatment of penetrating wound in the thoracic area of donkey in our clinic gave a clue that: 1- it might be possible to perform thoracotomy in equine without inflating pump, 2- there is no communication between the plural sacs in equine, 3- the mediastinum is strong enough not to be ruptured due to difference in the pressure of the plural sacs (Jawad, 1981).

#### MATERIALS AND METHODS

Twenty nine donkeys and twenty five horses (both sexes) aged 4-10 years were used in this study. All animals were clinically healthy except one which had an infected wound in the left forelimb. Thoracotomy was performed on the right side of the chest under general anaesthesia using 10% choral hydrate. After surgical opening of the plural sac, the lung was collapsed then the sac left open for 15-30 minutes (Figs, 1 and 2). Postoperative care was done up to 30 days. Eighteen horses and 24 donkeys became clinically normal and the wounds completely healed. Two horses died due to pleurisy.

Of the 54 animals, 5 donkeys and 5 horses were killed and used in a simple test to find out if there is a communication between the plural sacs or if the mediastinum is not strong enough to resist the pressure. Both sides of the thorax were opened and when the right plural sac was filled with colored water, none of it was noticed to escape into the left sac.



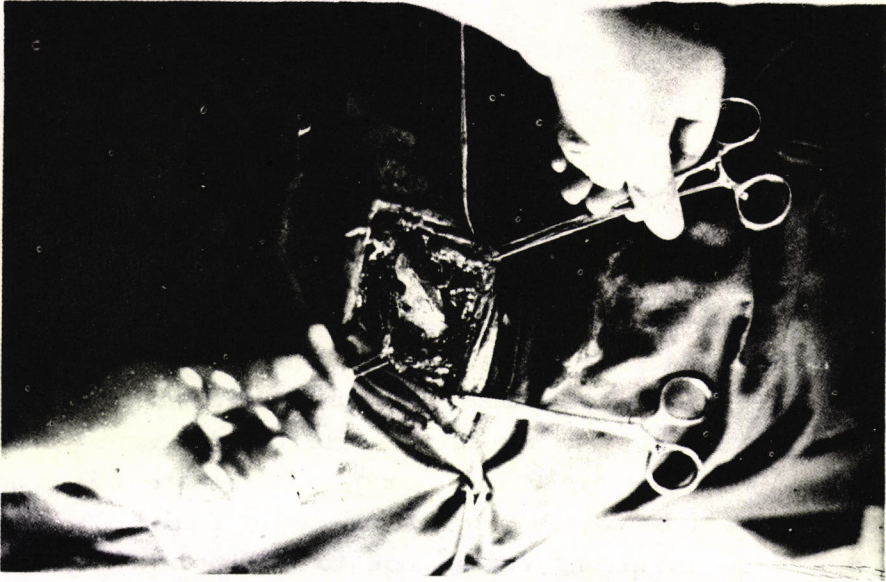


Figure 1: Exposure of the pleura after removing the 7th. rib.

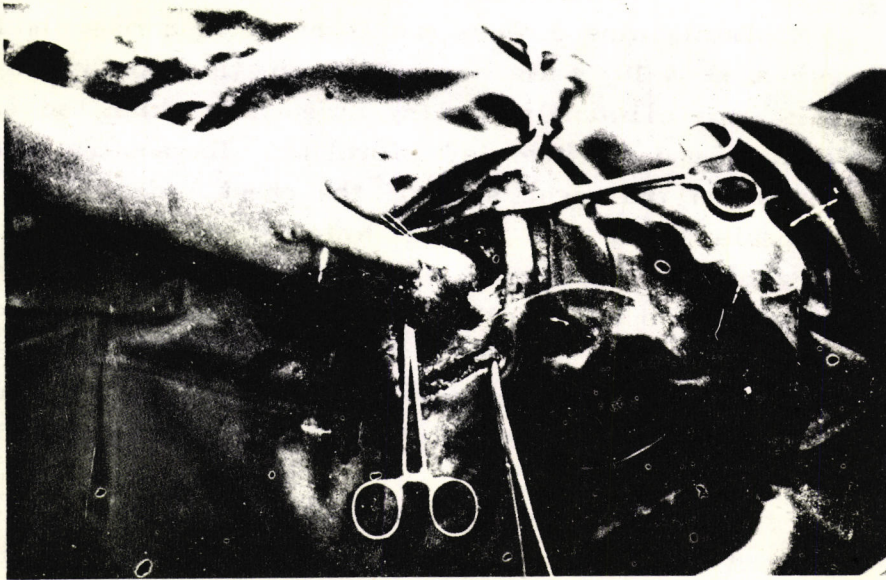


Figure 2: Showing the collapse of the lung.

## RESULTS

Healing of the wounds and recovery of the animals within 12 weeks indicated a successful surgical operation without the aid of the inflating pump. It was further found that there was no communication between the two plural sacs and that the mediastinum was strong enough to resist the difference in the pressure of the plural sacs.

## DISCUSSION

The results of this study indicated that the collapse of lung happen when the plural sac is open in equine as mentioned by O'connor (1958). However, communication between the plural sacs was not observed which did not support the results of many workers who reported that there is a communication between the two plural cavities (Ciliga *et. al.*, 1966; Sisson, 1968; Nickel, 1973; Getty, 1975; Jafary, 1977). Our results were not in agreement with those of O'connor (1958) from surgical point, who mentioned that those of the entrance of the air into the chest of equine invades both plural sacs which was excluded by opening of the thorax and the animal was alive. The successful thoracotomy without using inflating pump in this study was not in agreement with king (1974) who observed that it is impossible to perform thoracic surgery without using inflating pump, while it confirms the results of Jawad (1981).

These findings indicate that it is possible to perform thoracotomy in equine without inflating pump and there is no communication between the pleunal sacs and the mediastinum is strong enough to resist the difference in the pressure of the plural sacs.

## REFERENCES

- Al. Jafary, M.A.H. (1977). Discriptive ,Anatomy of Domestic Animals. Halpoo University.



- Ciliga et al (1966). A contribution to the Anatomy of the mediastinum in Domestic Equines vet. Archiv, 36.
- Frank, E.R. (1955) Veterinary surgery. 2nd ed. Burgess publishing company, Minneapolis, Minnisote.
- Getty, R. (1975). The Anatomy of the Domestic Animals. W. B. Saunders company, London. 5th. ed, pp. 54-58.
- Hickman, J. and Walker, R. G. (1973). An Atlas of Veterinary surgery. Oliver and Boyd, Edinburgh.
- Jawad, N. M. A. (1981). Thoracic Surgery in the Donkey. The Iraqi J. Vet. Med. 5:50-54.
- King, A. S. (1974). A Guide to the physiology and clinical Anatomy of the Thorax. 3 rd. ed. Dept. of Vet. Anatomy. University of Liverpool, Liverpool.
- Nickel, R. Schummer, A. and Seiferle, E. (1979) the viscera of the Domestic Animals. 2nd, ed. Verlag paul parey, Berline, Hamburg.
- O'conner, J. J. (1958) Dollars Veterinary Surgery. 4th ed., London, Bailliere, Tindall Cox.

### جراحة الصدر في الفصلة الحادية

تسبب محمد عطا جواد، فرع الجراحة، كلية الطب البيطري،

#### الخلاصة

اجريت عمليات فتح الصدر لتسعة وعشرون حمارة ودمه وعشرون جوادا وكان عمرها تتراوح بين ٤-١٠ سنة وبدون استعمال التخدير الاصطناعي.

ان الاسترواح الصدري الجراحي لم يؤثر على حياة الحيوان طبيا. لقد تم شفاء ثمانية عشر جوادا واربعه وعشرون حمارة سريريا واغلق الجرح خلال فترة ٣٠ يوما ولكن نفق جوادين بالتهاب الجنب.