

## BONY SHUTTLE PIN SPLINT

H. Shnain, F.R. Khalid, and N.H. Markus

Surgery Department, College of Veterinary Medicine,  
University of Baghdad, Baghdad , Iraq

### SUMMARY

Fifteen bony shuttle pins are used to immobilize induced radial and tibial fractures in the distal third. Good alignment and healing are seen by radiological examination . There is no side effect due to application of such kind of splints which are eventually resorbed.

### INTRODUCTION

Fractures of the radius in dogs commonly occur in the distal half (1,2) and are mostly transverse, oblique and simple (2). Radial and tibial fractures in the distal third heal slowly and are frequently the site of delayed union and nonunion (1). Therefore, permanent intramedullary pins are most suitable splints for fixation of fractures of these bones, particularly, the Leighton shuttle pin.

Permanent shuttle pin is easy to apply and efficient for proper alignment and immobilization . In this experiment bony shuttle pins are used instead of the metallic pins to evaluate their efficiency and the possible complications.



## MATERIALS AND METHODS

Fifteen local breed dogs are used. Bony shuttle pins of different sizes made from cooked horse bone (cortical part).

Pins are made by cutting a long bone into long proper width strips by an electric saw, then with an electric grindstone, pins of different sizes are made similar to the matalic Leighton shuttle pin in shape. A small hole is made in the middle of each pin by a drill.

These pins are sterilized by autoclave. Nylon monfilament thread is used to pull the bony pin with the Leighton shuttle pin tightener. In addition to the above mentioned materials ordinary surgical set is needed. Under general surgical anesthesia (15 mg/kg.B.W Ketamine mixed with 5 mg/kg.B.W. Xylazine are given 1/m) (3), the radius is exposed from the craniomedial aspect, care has been taken to avoid the cephalic vein which passes along the cranial border . Fracture in the distal third of the radius was made with a surgical blade saw, soft tissues surrounding the site of fracture are protected with two curved scissors pushed under the bone one from each side.

As the open reduction is performed, the medullary cavity of the proximal and distal segments are reamed with the pin to facilitate introduction of the pin. About 20 cm long nylon suture is threaded through the hole of the bony pin, then the pin is inserted into the long proximal segment of the fractured bone until a tiny portion of the pin protrudes . The fracture is reduced with the nylon suture emerging from between the fractured ends. Then the tightener is used to pull the bony pin into the distal segment across the fracture line. Penicillin powder is put into the fracture area and soft tissues in the area approximated with simple interrupted stitches of surgical silk No.00. Mason meta splint is necessary as an additional external support which should always be used to prevent rotational motion (4,5,6), but here it is used only for one week. Systemic antibiotic is used for three post operative days. Radiographs were taken to the fractured bone at weekly intervals to follow up the progress of healing for one month, then radiographs were taken once a month to follow up



resorption of the pins.

The same technique was used for the distal third of the tibia. Tibia was exposed from the medial side. Angled Mason meta splint had been used as an additional external splint fixed to the anterior aspect of the limb involving the tibia and metatarsal bones.

## RESULTS

Clinically there was no any apparent complication, animals started using the limbs few days after operation. Progressive radiographical study indicated good callus formation and gradual resorption of the bony pin (fig 1,2,3,4).

One of the splints failed due to mutilation of the external additional splint by the animal and resulted in fracture of the bony shuttle pin.

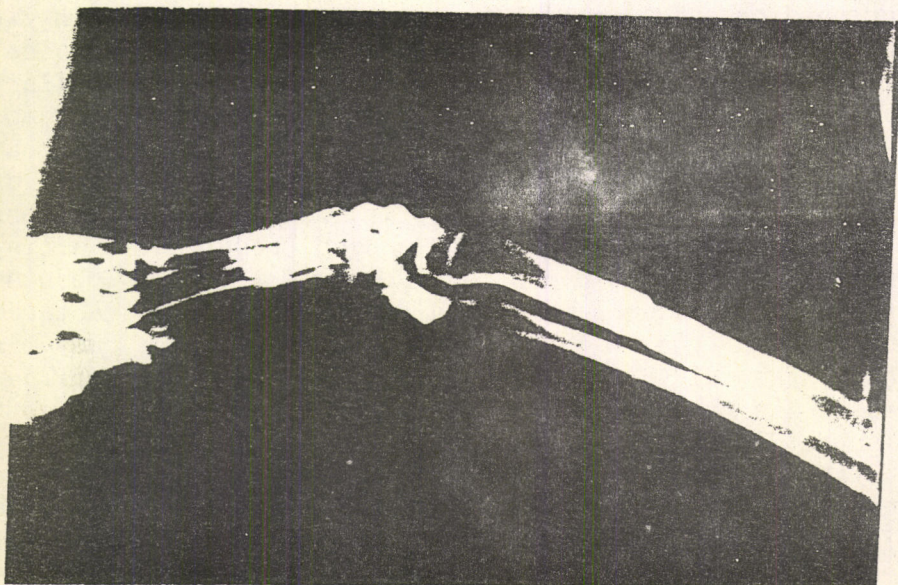


Fig.1: X-Ray film after two weeks from the time of operation






Fig.2: X-Ray film after four weeks from the time of operation.




Fig.3: X-Ray film after three months from the time of operation.






Fig.4: X-Ray film after one year from the time of operation.

#### DISCUSSION

It is recommended (7) that fractures of the distal third of the radius be repaired by pinning. Intramedullary pinning is regarded by some surgeons as the popular form of internal fixation used by veterinarians today (8). Permanent intramedullary Leighton shuttle pin has been used successfully for fixation of certain fractures of the distal third of the radius (9,19,11).

In the present work, bony shuttle pin has been used for fixation of fractures in the distal third of the radius and tibia. Bony pin was good enough to immobilize these fractures & was as good as the metallic shuttle pin.

The bony pin is eventually resorbed while the metallic pin is permanent and corrosion is possible due to the difference in the oxygen potential at some points on the



metal implant (8). Also we should take into consideration the shape of the shuttle pin which is fit for the oval medullary canal of the radius as a result the possible rotation of the segments will be reduced more than that with round intramedullary pin.

This experimental work indicates that the bony shuttle pin could be used for immobilization of certain distal third fractures of the radius and tibia in clinical cases and have some advantages over the metallic pin.

#### REFERENCES

- 1- Brinker, W.O. (1974). Canine Surgery , 2nd Archibald ed. American Veterinary Publications, Inc, Santa Barbara California. P.978.
- 2- Leonard, E.P. (1971). Orthopedic Surgery of the Dog and Cat 2nd ed. P. 163 W.B. Saunders Company, Philadelphia. London. Toronto.
- 3- Al-Asadi, R.B. (1987). M.Sc. Thesis Baghdad University
- 4- Brinker, W.O. (1974). Canine Surgery. 2nd Archibald ed. American Veterinary Publications, Inc, Santa Barbara California . P. 1033.
- 5- Deyoung, D.J. & Probst, C.W. (1985). Textbook of Small Animal Surgery Vol. II. W.B. Saunders Rio de Janeiro, Sydney. Tokyo. P.1949.
- 6- Egger, E.L. (1985). Textbook of Small Animal Surgery Vol. II. W.B. Saunders Company, Philadelphia. London, Toronto, Mexico City, Rio de Janeiro. Sydney. Tokyo, P.2111.
- 7- Berge, E.& Westhues, M. (1966). Veterinary Operative Surgery 1st English ed. Medical Book Company 7 Aaboulevard. Copenhagen. Denmark. P.18.



- 8- Leonard, E.P. (1971). Orthopedic Surgery of the Dog and Cat 2nd ed. W.B. Saunders Company, Philadelphia. London. Toronto. P.55.
- 9- Leighton, R.L. (1950). A New Method of Permanent Intramedullary Pinning. J. Am Vet Med. assn. 117:202.
- 10- Leighton, R.L. (1952). Further reports of New Method of Permanent Intramedullary Pinning. J.Am. Vet. Med. Assn.
- 11- Leighton, R.L. (1963). Permanent Intramedullary Fixation of the Distal Fractures of the Radius and Ulna in Dogs. Southwestern vet., 16:97-100

### جبيرة المكوك العظمية

حمزة سنين، فيصل رضا خالد و نادية حنا مرقص

فرع الجراحة/كلية الطب البيطري  
جامعة بغداد

### الخلاصة

استعملت خمسة عشر من جبائر المكوك العظمية لتثبيت كسور في الثلث القامي من عظمي الكعبرة والظنوب. فظهر الترميم والشفاء شعاعياً جيد ولم تحدث اي اختلاطات نتيجة استعمال هذا النوع من الجبائر العظمية والتي تتلاشى بعد حدود الشفاء وانتقاء الحاجة لها.