



Evaluation of the Acute Toxicity of Acetaminophen in Mice

Suhad H Hashem^{*1} , Falah MK AL-Rekabi¹ , Selman Ali²

¹Department of Physiology, Biochemistry and Pharmacology, College of Veterinary Medicine, University of Baghdad, Baghdad Iraq, ²Interdisciplinary Biomedical Research Centre, School of Science and Technology, Nottingham Trent University, Nottingham NG11 8NS, United Kingdom

A B S T R A C T

Acetaminophen (N-acetyl-para-aminophenol, APAP), widely used for pain relief across species, poses significant toxicity risks. This study aimed to assess the acute toxicity profile of APAP by determining the median toxic dose (TD₅₀) in a murine model. Sixty male Balb/c mice, aged 8 weeks and weighing 20-30 g, were randomized into six equal groups. Five groups received single oral doses of APAP (150, 200, 300, 500, and 700 mg/kg BW), while the control group received distilled water. The TD₅₀ was computed utilizing the probit method. Animals were monitored for 24 h for any sign indicative of clinical toxicity. Post-exposure, liver and kidney necropsies were conducted for histopathological analysis. Predominant symptoms of toxicity included prostration, hematuria, heightened agitation, lacrimation, cyanosis, and recumbency across doses from 150 to 700 mg/kg BW. The TD₅₀ for APAP was estimated to be 732 mg/kg BW. The liver histopathological examination of mice treated with 700 mg/kg BW APAP revealed severe multifocal hyper eosinophilic hepatocytes, indicating areas of centrilobular necrosis, disorganized hepatic cords, and multiple hemorrhage regions. The kidney examination exhibited no pathological changes in treated mice with 700 mg/kg BW APAP. In conclusion this investigation provides critical insights into the acute toxicity profile of APAP. The findings not only highlight the potential risk associated with APAP usage but also the necessity of strict monitoring for stringent dosage control. Further research is also needed to understand the underlying mechanism of APAP-induced toxicity and pave the way for the development of efficacious therapeutic strategies to counter APAP overdose.

Keywords: acute toxicity, acetaminophen, mice, TD₅₀, analgesic

*Correspondence:

Sohad.mohammed1500a@covm.uobaghdad.edu.iq

Received: 07 November 2023

Revised: 21 November 2023

Accepted: 28 December 2023

Published: 28 December 2023

DOI:

<https://doi.org/10.30539/9pts5w38>



This article is an open access distributed under the terms and conditions of the Creative Commons Attribution License (CC BY 4.0)

Cite:

Hashem SM, AL-Rekabi FMK, Ali S. Evaluation of the acute toxicity of acetaminophen in mice. Iraqi J. Vet. Med. 2023;47(2):81-87.

INTRODUCTION

Acetaminophen, known chemically as N-acetyl-para-aminophenol (APAP) and also widely referred to as paracetamol, has been extensively utilized as an antipyretic and analgesic for treating both acute and chronic pain (1). It is also prescribed to patients for whom nonsteroidal anti-inflammatory drugs (NSAIDs) are contraindicated, such as those with gastric ulcers and bronchial asthma, and has been used as a home analgesic for over three decades (2).

In the early 1980s, APAP surpassed aspirin as the preferred over-the-counter analgesic in the United Kingdom (3).

APAP is available in various dosage forms, including syrup, injection, suppository, regular pills, and effervescent tablets. Adults typically take 325–650 mg every 4–6 h, or 1 g of immediate-release oral formulations as needed, with a maximum daily limit of 4 g (4). In veterinary medicine, APAP is occasionally used as an oral pain reliever and antipyretic for cattle suffering from viral diseases such as three-day sickness and cow pox, and it is also administered

to dogs (5). For long-term use, defined as over five days, it may be advisable to adjust the administration frequency to every 12 h, especially at the minimum dosing range. Recommended doses for small mammals such as mice, rats, gerbils, hamsters, guinea pigs, and chinchillas range from 1-2 mg/mL in their drinking water (6). Horses receive 0.04-0.1 mg/kg intramuscularly with dosing intervals of 6-12 h, extending preferably to 36-48 h for conditions like perioperative analgesia or laminitis (7). Dogs with chronic pain conditions are often prescribed analgesics containing paracetamol at a dosage of 10 to 15 mg/kg regularly (8).

Despite widespread beliefs in its safety, APAP poisoning is common due to its easy accessibility. APAP is frequently combined with other medications, including opioids and diphenhydramine, often without consumer awareness (9). Combining APAP with other compounds, such as acetylsalicylic acid, codeine, oxycodone, propoxyphene, caffeine, dextromethorphan, various antihistamines, and decongestants, is a significant factor in the occurrence of poisoning incidents (10). N-acetyl-p-benzoquinone imine (NAPQI), a toxic metabolite of APAP, when produced, leads to cellular damage proportional to the consumed amount. This results in glutathione depletion, activation of glutathione S-transferases (GSTs), and accumulation of NAPQI to toxic levels (11). NAPQI's interaction with mitochondrial proteins can impair respiration, increase oxidative stress, and cause mitochondrial dysfunction, leading to acute liver failure, centrilobular hepatic necrosis, renal tubular necrosis, and hypoglycemic coma (12, 13).

APAP toxicity is common, as it is readily available and easily accessible as an over-the-counter medication. It is a matter of grave concern owing to its ability to cause liver damage. The process of liver regeneration is fundamental for recuperation from APAP-induced liver injury; however, in cases of severe overdose, it can hinder liver regeneration and contribute to unsuccessful recovery and possible fatality (14). APAP poisoning, whether intentional or accidental, represents a significant public health challenge, with its toxicity becoming increasingly prevalent worldwide (15). The rise in APAP poisoning cases in dogs and cats can be attributed to the increased accessibility of paracetamol in various over the counter and non-prescription products. It is worth noting that the toxicity of APAP is more pronounced and severe in cats compared to dogs (16). This phenomenon occurs due to cats frequently being exposed to toxic doses of APAP. A primary reason for this exposure is the owners' tendency to administer the medication without consulting a qualified veterinarian. By avoiding the crucial step of seeking professional advice and guidance, owners neglect the expertise of feline healthcare specialists (17).

The objective of this research is to assess the immediate toxicological impact of APAP by determining the median toxic dose (TD₅₀) in a murine model. This endeavor is anticipated to enhance our comprehension of the hazards

associated with APAP overdose, thereby offering insights for its safe usage.

MATERIALS AND METHODS

Ethical Approval

All procedures in this study were reviewed and approved by the local Animal Care and Use Committee (Approval No. P.G. 1247) at College of Veterinary Medicine, University of Baghdad.

Animals

Sixty male Bulb/c mice reached the age of 8 weeks and ranged in body weight from 20-30 g. The mice used in this study were raised and housed under standard laboratory conditions. They were maintained on a 12-h light/dark cycle, with ad libitum access to food and water. The temperature in the animal house was kept constant at 22 ± 2 °C, with a relative humidity of 50 ± 10%.

Estimation of Median Toxic Dose (TD₅₀)

The animals in this study were divided into six equal groups. Five of these groups were given varying dosage rates (150, 200, 300, 500, and 700 mg/kg BW) orally as a singular dose of APAP (SDI, Samara, Iraq). The sixth group received distilled water only as a control. To determine the TD₅₀ for APAP acute toxicity, the probit approach was used for the study (18). Continuous observation was maintained over a span of 24 h to detect any indications of APAP-induced toxicity in the animal subjects. All animals exhibiting signs of toxicity were managed with the utmost humane consideration.

Preparation of APAP Dosing Solutions

Five dosage rates have been used as illustrated in Table 1. Accordingly, five separate concentrations of APAP were prepared to correspond to these specified dosages.

Table 1. Dosage rates and concentrations of N-acetyl-para-aminophenol (APAP)

No.	Dosage rate (mg/kg BW)	Concentration (mg/mL)	Dosage volume mL/10 g mouse BW
1	150	15	0.1
2	200	20	0.1
3	300	30	0.1
4	500	50	0.1
5	700	70	0.1
Control	-Distilled water	-	0.1

Histopathology

The histopathological patterns of the liver and kidneys of mice were examined following a dosage of 700 mg/kg BW of APAP (approximately equivalent to TD₅₀). The process began with the euthanasia of the mouse using diethyl ether (THOMAS BAKER, India) within a closed chamber, also known as a dissector. This method entailed the controlled administration of diethyl ether vapor,

ensuring a rapid and humane approach to euthanasia. The process continued until the mice became unconscious and subsequently exhibited cessation of cardiac and respiratory functions. Subsequently, a midline incision is made to expose the abdominal cavity, enabling the careful extraction of the liver and kidneys.

These organs were then immediately fixed in 10% neutral buffered formalin (Alfa lab Chemika, China) for 48 h. Following fixation, the samples were sectioned to a thickness of 0.5 cm and placed in plastic cassettes. Dehydration and clearing of the tissues were automated using a Histo-Line Laboratories ATP 1000 tissue processor (Italy). Subsequently, the dehydrated tissues were embedded in paraffin wax using a Histo-line laboratory HESTION TEC 2900 embedding system, with temperature regulation managed by a TEC 2900 Thermal console (Histo-line Laboratories, Italy). Tissue blocks were then sectioned at 4-5 μm thickness using a Histo-Line Laboratories MRS3500 rotary microtome (Italy). The sections were floated in a water bath and placed on a temperature-controlled hot plate, both regulated by the TEC 2900 Thermal console, before mounting on glass slides. The staining was performed using Hematoxylin and Eosin (H&E, Dakocytomation, Denmark). Detailed histopathological assessments were conducted under a light microscope (Olympus, Japan) by a trained pathologist, focusing on the liver and kidneys' structural changes (19).

Statistical Analysis

The TD_{50} was estimated using the probit method implemented in SPSS software Version 26 (IBM Corp., Armonk, NY, USA) (20).

RESULTS AND DISCUSSION

Acute Toxicity Manifestations

Several clinical manifestations were observed following APAP exposure, included an arched back, convulsions, muscular tremors, and instances of epistaxis and oral bleeding in a subset of the animal subjects (Figure 1 A). Hematuria was also documented (Figure 1 B). Most of the animals displayed critical signs of poisoning such as heightened agitation, lacrimation, cyanosis, and recumbency (Figure 1 C). Approximately 2 h post-exposure, the animals' respiration patterns transitioned from rapid and shallow to slow and labored. Within a span of 15 h, a minority of the animals that were critically affected died due to respiratory failure.

In laboratory mice, the manifestation of bleeding from the nose and mouth as a result of APAP poisoning can be attributed to several potential mechanisms. One such mechanism involves the detrimental effect of APAP on liver cells, which consequently leads to a reduction in the production of clotting factors (22, 23). This reduction in clotting factors ultimately results in an increased propensity for bleeding. Additionally, the damaging impact of APAP on blood vessels serves as another mechanism by which bleeding can occur (23). This damage can trigger inflammation and hemorrhage in various organs, including the lung, kidneys, and gastrointestinal tract (24). Lastly, APAP has the ability to induce oxidative stress, thereby impairing the functionality of platelets, which are vital for proper blood clotting (25).

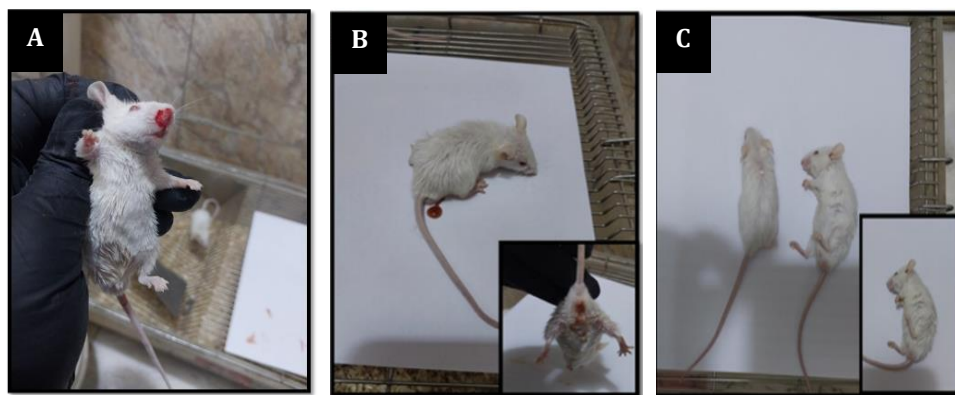


Figure 1. Clinical manifestations in Balb/c male mice following a single oral N-acetyl-para-aminophenol (APAP) exposure at a dose of 700 mg/kg BW for 24 h: **(A)** Epistaxis and mouth bleeding, **(B)** Haematuria, and **(C)** Recumbency

Patients suffering from acute liver failure induced by APAP exhibit a combination of hypercoagulable and hypocoagulable alterations within their blood coagulation system, which ultimately affects their ability to form blood clots (26). Cyanosis symptoms could potentially be

associated with methemoglobinemia, a medical condition characterized by insufficient oxygen transportation in the blood as a result of a chemical interaction with specific medications, such as APAP (27). Cyanosis symptoms can potentially be associated with the occurrence of liver failure

or respiratory distress because of APAP poisoning. The manifestation of liver failure or respiratory distress can lead to diminished levels of oxygen in the bloodstream,

thereby resulting in the development of bluish skin or lips (referred to as cyanosis) in both human beings and animals (28).

Table 2. Probit analysis data for determining median toxic dose (TD₅₀) of orally administered N-acetyl-para-aminophenol (APAP) in Balb/c male mice after 24 h

Group	Dose (mg/kg BW)	Log Dose	Number of Animals per Group	Number of Animals Dead	% of Animals Dead	Toxic Signs Grade (%)*	Probit Number
1	150	2.17	10	0	0	7.50	3.52
2	200	2.30	10	1	20	15.0	3.96
3	300	2.77	10	1	40	17.5	4.05
4	500	2.69	10	2	40	32.5	4.53
5	700	2.85	10	5	60	52.0	5.85
Control	DW**	-	-	0	0	-	-

*The total toxic grade for each dose was determined based on the number of toxic signs observed. This grade was converted into a percentage, and then to a probit number. The log dose-probit response curve is used for TD₅₀ calculation. **DW: distilled water

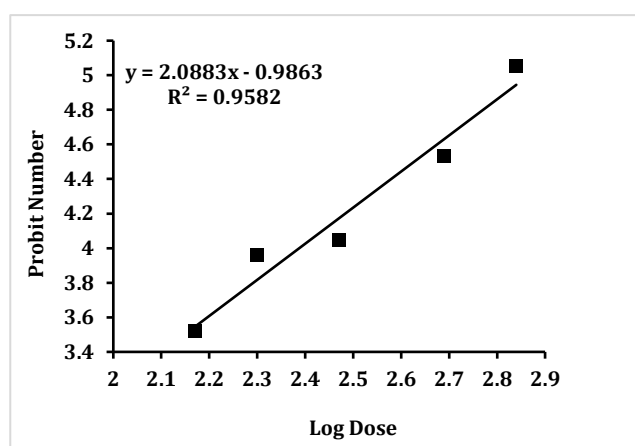


Figure 2. Dose-response curve for acute toxicity of N-acetyl-para-aminophenol (APAP) in Balb/c male mice. The curve represents the probit analysis of log-transformed doses of APAP, demonstrating the correlation between the administered dose and the resultant probit numbers indicative of toxic effects. The data points are derived from a 24-h observation period post-administration

TD₅₀ of APA in Mice

The calculated TD₅₀ value for APAP, when orally administered to male mice, was established as 736 mg/kg BW after a 24-h period (Table 2 and Figure 2). The TD₅₀ value derived from the stipulated equation and logarithm is found to be 2.8669. Utilizing the antilogarithm of this value allows us to infer that the TD₅₀ of APAP for mice, upon oral administration, is commensurate with 736 mg/kg BW. In the context of the existing scholarly literature, there appears to be an absence of studies specifically addressing the estimation of the TD₅₀ value for APAP. Consequently, this precludes the possibility of establishing a correlation or conducting a comparative analysis between the findings of the present study and those of analogous research papers. It is significant to note that the determination of the median lethal dose (LD₅₀) of APAP, which stood at 1120.28 mg/kg

BW when administered orally in mice, was conducted with a subsequent 24-h observational period (29). The substantial mortality observed among the experimental subjects during LD₅₀ determination necessitated the transition to measuring TD₅₀ instead, as an ethical measure aimed at mitigating the requirement for animal sacrifice. Therefore, we believe that this information could be valuable for future studies focused on therapeutic interventions in cases of acute APAP poisoning in laboratory animals.

Liver and Kidney Histopathology

The histopathological examination of the liver (Figure 3 A) and kidney (Figure 3 B) in the negative control group showed normal liver architecture. However, the livers of mice treated with 700 mg/kg BW APAP exhibited severe multifocal hyper eosinophilic hepatocytes, with areas of

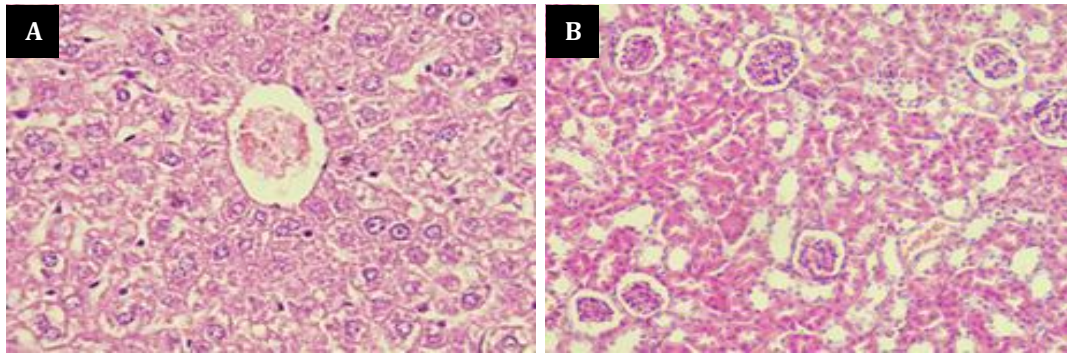


Figure 3. Histopathological sections of liver (A) and kidney (B) in Balb/c male mice of negative control group showing normal architecture

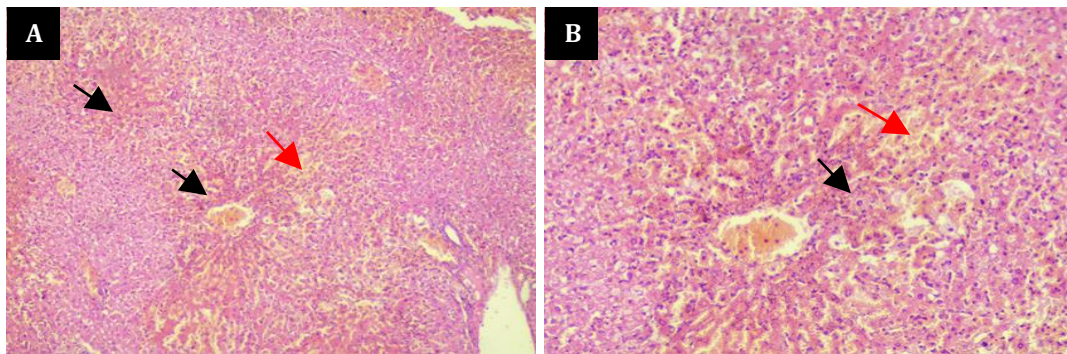


Figure 4. Histopathological sections of liver in Balb/c male mice following a single oral N-acetyl-para-aminophenol (APAP) exposure at a dose of 700 mg/kg BW for 24 h showing severe multifocal hyper eosinophilic hepatocytes which demonstrated areas of centrilobular necrosis of hepatocytes (black arrows), disorganized of hepatic cords and several areas of hemorrhage (red arrows). H&E stain: (A) 10 \times , (B) 20 \times

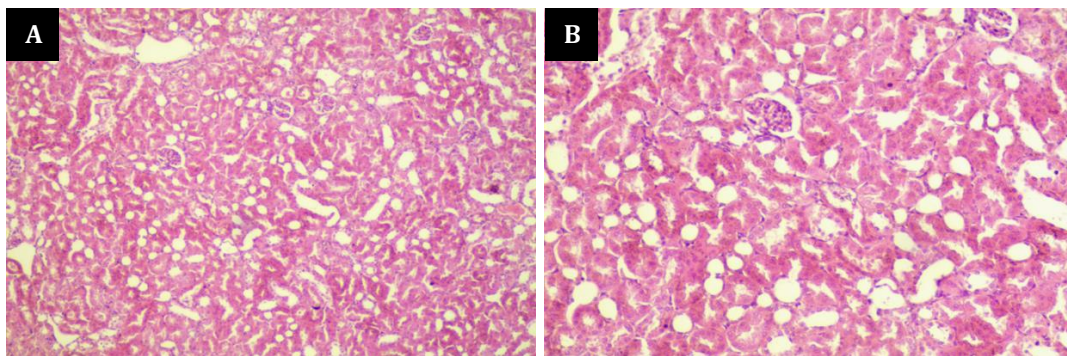


Figure 5. Histopathological sections of kidney in Balb/c male mice following a single oral N-acetyl-para-aminophenol (APAP) exposure at a dose of 700 mg/kg BW for 24 h showing no pathological changes of kidney architecture. H&E stain: (A) 10 \times , (B) 20 \times

centrilobular necrosis, disorganized hepatic cords, and several areas of hemorrhage (Figure 4 A, B). The histopathological examination of the kidneys of mice treated with 700 mg/kg BW APAP showed no pathological changes (Figure 5 A, B).

A prior investigation revealed a strong association between high doses of APAP and severe hepatic and renal damage. The study observed that APAP administration led to hepatic and renal toxicity by disrupting antioxidant status, lipid profiles, and histomorphological architecture.

In rats receiving a 700-milligram dose of APAP, the histopathological examination of the liver showed inflammatory cell infiltration, shrunken hepatocytes with chromatin condensation, and hepatocellular injury marked by diffuse cytoplasmic vacuolation (30). Moreover, an overdose of APAP at a dosage of 300 mg/kg in mice caused hepatocellular necrosis, inflammatory cell infiltration, and liver hemorrhage (31). In a different study, the administration of 600 to 800 mg/kg of APAP to male wild-type mice led to elevated plasma concentrations of liver

enzymes, specifically alanine aminotransferase. The observed consequences included hepatic necrosis and renal tubular necrosis. These lesions indicate the possibility of substantial adverse effects on both the liver and kidneys in response to higher dosage rates of the drug in the context of wild-type animals (32). In another study, a single intraperitoneal administration of APAP (300 mg/kg) in mice showed a notable increase in serum ALT levels. Additionally, massive hepatocellular necrosis, inflammation, and hemorrhage were observed in the livers of mice given an APAP overdose (33).

The collective results from these studies focus on the fact that APAP overdose leads to significant and intense liver damage in mice. This damage includes hepatocyte necrosis, inflammation, and hemorrhage. Noticeably, the intensity and extent of liver damage are influenced by factors such as the dosage rate and period of exposure to APAP. In addition, the genetic background and physiological state of mice play crucial roles in defining the severity of adverse effects initiated by APAP overdose.

APAP is a medication agent capable of inducing hepatic injury and inflammation. Its metabolic breakdown within the liver results in the generation of a harmful compound that combines with proteins and disrupts the integrity of mitochondria. This provokes an immunological effect that elicits the production of IL-1 β , a cytokine that promotes the development of fibrotic tissue and constriction of the sinusoidal spaces. Therefore, this hinders the transfer of blood and oxygen to hepatocytes while concurrently enhancing the levels of toxic substances in the circulatory system (34).

Sinusoids, which are the small blood vessels responsible for carrying blood from the portal vein and hepatic artery to the hepatocytes, have a characteristic structure characterized by fenestrated endothelial cells and the absence of a basement membrane. This distinct structure enables efficient exchange of materials between the blood and liver cells. The manifestation of narrow sinusoids is a characteristic feature of liver fibrosis, a condition characterized by the excessive accumulation of scar tissue in the liver due to chronic inflammation. Narrow sinusoids impede the blood flow and oxygen supply to the hepatocytes, thereby exacerbating their damage and inflammation. Additionally, narrow sinusoids hinder the clearance of bacterial products and other toxic substances from the portal circulation, thereby further stimulating the inflammatory response in the liver (35). The constriction of blood vessels leads to a decrease in blood circulation and the delivery of oxygen to the cells of the kidney, resulting in additional harm and inflammation. Moreover, this process amplifies the presence of toxins within the bloodstream, which, in turn, stimulates a heightened activation of immune receptors and subsequent reactions within the kidney (36).

In conclusion, this investigation provides insights into the acute toxicity profile of APAP. The findings not only highlight the potential risks associated with APAP usage but also emphasize the necessity of strict monitoring for stringent dosage control. Furthermore, further research is needed to elucidate the underlying mechanisms of APAP-induced toxicity and pave the way for the development of efficacious therapeutic strategies to counter APAP overdose.

ACKNOWLEDGEMENTS

The authors extend their deepest appreciation to Dr. Omar Hussein Khalaf from the Department of Pathology and Poultry Diseases, College of Veterinary Medicine, University of Baghdad, for his valuable contribution to the interpretation of the histopathology slides.

CONFLICT OF INTEREST

The authors declare no conflict of interest.

EDITORIAL PROCESS TRANSPARENCY

Falah MK AL-Rekabi is the Editor of The Iraqi Journal of Veterinary Medicine. Despite this role, the peer review process and the final publication decision were made independently and impartially, ensuring no influence from the author's editorial position.

REFERENCES

- Bandoli G, Palmsten K, Chambers C. Acetaminophen use in pregnancy: Examining prevalence, timing, and indication of use in a prospective birth cohort. *Paediatr Perinat Epidemiol.* 2020;34(3):237-246. [10.1111/ppe.12595](https://doi.org/10.1111/ppe.12595)
- Hegazy A, Abd Al Hameed EA, El-Wafaey D, Khorshed O. Effect of paracetamol administration on the rat kidney structure: a morphological study. *Zagazig Univ Med J.* 2021;27(4):567-576. [10.21608/zumi.2019.11494.1194](https://doi.org/10.21608/zumi.2019.11494.1194)
- Bertolini A, Ferrari A, Ottani A, Guerzoni S, Tacchi R, Leone S. Paracetamol: new vistas of an old drug. *CNS Drug Rev.* 2006;12(3-4):250-75. [10.1111/j.1527-3458.2006.00250.x](https://doi.org/10.1111/j.1527-3458.2006.00250.x)
- McEvoy GK. American hospital formulary service. AHFS Drug Information Am Soc Heal Pharm Bethesda, MD. 2007;2184.
- Bello AM, Dye C. Current perceptions and use of paracetamol in dogs among veterinary surgeons working in the United Kingdom. *Vet Med Sci.* 2023;9(2):679-686. [10.1002/vms3.1058](https://doi.org/10.1002/vms3.1058)
- Plumb DC. *Plumb's veterinary drug handbook: pocket.* 9th ed. Hoboken: John Wiley & Sons; 2018.
- Papich MG. *Papich Handbook of Veterinary Drugs-E-Book.* 5th ed. St. Louis: Elsevier; 2020.
- Paulista E. *Veterinary Anaesthesiology*, September 12-16, 2006, Santos, Brazil. *Vet Anaesth Analg.* 2007 (34):1-77. [10.1111/j.1467-2995.2007.00371a.x](https://doi.org/10.1111/j.1467-2995.2007.00371a.x)
- Chakraborti T, Agarwal S, Khaezaeni Y, Rizk Y, Isahagian V. D3BA: a tool for optimizing business processes using non-deterministic planning. In: *International Conference on Business Process Management.* Springer; 2020(1):181-193. [10.1007/978-3-030-66498-5_14](https://doi.org/10.1007/978-3-030-66498-5_14)
- Doyon S, Klein-Schwartz W, Lee S, Beuhler MC. Fatalities involving acetaminophen combination products reported to United States poison centers. *Clin Toxicol (Phila).* 2013;51(10):941-948. [10.3109/15563650.2013.848282](https://doi.org/10.3109/15563650.2013.848282)
- Yoon E, Babar A, Choudhary M, Kutner M, Pysopoulos N. Acetaminophen-induced hepatotoxicity: a comprehensive update. *J Clin Transl Hepatol.* 2016;4(2):13. [10.14218/JCTH.2015.00052](https://doi.org/10.14218/JCTH.2015.00052)

12. McGill MR, Jaeschke H. Metabolism and disposition of acetaminophen: recent advances in relation to hepatotoxicity and diagnosis. *Pharm Res.* 2013;30(9):2174-2178. [10.1007/s11095-013-1007-6](https://doi.org/10.1007/s11095-013-1007-6)
13. De-Giorgio F, Lodise M, Chiarotti M, d'Aloja E, Carbone A, Valerio L. Possible fatal acetaminophen intoxication with atypical clinical presentation. *J Forensic Sci.* 2013;58(5):1397-1400. [10.1111/1556-4029.12205](https://doi.org/10.1111/1556-4029.12205)
14. Ferretti S, Curatola A, Chiaretti A, Graglia B, Gatto A, Capossela L, Pansini V. Early treatment with N-acetylcysteine reduces hepatotoxicity in acute acetaminophen poisoning. *Acta Biomed.* 2023;94(S1):e2023033. [10.23750/abm.v94iS1.13714](https://doi.org/10.23750/abm.v94iS1.13714)
15. Hameed HA, Hassan AF. The prophylactic anti-inflammatory effect of omega-7 against paracetamol-induced liver injury in rats. *Iraqi J Vet Med.* 2022;46(2):43-47. [10.30539/ijvm.v46i2.1412](https://doi.org/10.30539/ijvm.v46i2.1412)
16. Yanuartono Y, Nururrozi A, Indarjulianto S, Raharjo S, Purnamaningsih H, Haribowo N. Keracunan Parasetamol Pada Kucing Dan Anjing: Gejala Klinis dan Terapi: Paracetamol Poisoning in Cats and Dogs: Clinical Symptoms and Therapy. *J Ilmu Peternak dan Vet Trop (J Trop Anim Vet Sci).* 2020;10(1):55-62. [10.46549/ijpv.v10i1.86](https://doi.org/10.46549/ijpv.v10i1.86)
17. Avizeh R, Najafzadeh H, Jalali MR, Shirali S. Evaluation of prophylactic and therapeutic effects of silymarin and N-acetylcysteine in acetaminophen-induced hepatotoxicity in cats. *J Vet Pharmacol Ther.* 2010;33(1):95-99. [10.1111/j.1365-2885.2009.01100.x](https://doi.org/10.1111/j.1365-2885.2009.01100.x)
18. Yu J, Xie J, Mao X, Wang M, Li N, Wang J, et al. Hepatotoxicity of major constituents and extractions of radix polygoni multiflori and radix polygoni multiflori praeparata. *J Ethnopharmacol.* 2011;137(3):1291-1299. [10.1016/j.jep.2011.07.055](https://doi.org/10.1016/j.jep.2011.07.055)
19. Suvarna KS, Layton C, Bancroft JD. Bancroft's theory and practice of histological techniques. 2nd Edi. Elsevier health sciences; 2018.
20. IBM Corp. IBM SPSS Statistics for Windows (Version 27.0) [computer program]. Version 27.0. Armonk (NY): IBM Corp.; 2020.
21. Barile FA. Acetaminophen, Salicylates, and Nonsteroidal Anti-Inflammatory Drugs (NSAIDs). In: Barile's Clinical Toxicology. CRC Press; 2019. p. 271-86. [10.1201/9780429154829-18](https://doi.org/10.1201/9780429154829-18)
22. Saccomano SJ. Acute acetaminophen toxicity in adults. *Nur Crit Care.* 2019;14(5):10-17. [10.1097/01.CCN.0000578816.14164.9f](https://doi.org/10.1097/01.CCN.0000578816.14164.9f)
23. Ohashi N, Kohno T. Analgesic effect of acetaminophen: a review of known and novel mechanisms of action. *Front Pharmacol.* 2020;11:580289. [10.3389/fphar.2020.580289](https://doi.org/10.3389/fphar.2020.580289)
24. Yang CC, Deng JF, Lin TJ. Pancytopenia, hyperglycemia, shock, coma, rhabdomyolysis, and pancreatitis associated with acetaminophen poisoning. *Vet Hum Toxicol.* 2001;43(6):344-348.
25. Prescott LF. Paracetamol (acetaminophen) poisoning: the early years. *Br J Clin Pharmacol.* 2023;95(1):3-12. [10.1111/bcp.15903](https://doi.org/10.1111/bcp.15903)
26. Groeneveld DJ, Poole LG, Bouck EG, Schulte A, Wei Z, Williams KJ, et al. Robust coagulation activation and coagulopathy in mice with experimental acetaminophen-induced liver failure. *J Thromb Haemost.* 2023;21(1):3-12. [10.1016/j.jth.2023.03.040](https://doi.org/10.1016/j.jth.2023.03.040)
27. James LP, McCullough SS, Lamps LW, Hinson JA. Effect of N-acetylcysteine on acetaminophen toxicity in mice: relationship to reactive nitrogen and cytokine formation. *Toxicol Sci.* 2003;75(2):458-467. [10.1093/toxsci/kfg181](https://doi.org/10.1093/toxsci/kfg181)
28. Papackova Z, Heczko M, Dankova H, Sticova E, Lodererova A, Bartonova L, et al. Silymarin prevents acetaminophen-induced hepatotoxicity in mice. *PLoS One.* 2018;13(1):e0191353. [10.1371/journal.pone.0191353](https://doi.org/10.1371/journal.pone.0191353)
29. Aseel HM. Therapeutic Trial of liver injury parallel acetaminophen administration in mice (Thesis). University of Baghdad: Iraq. 2021.
30. Adil M, Kandhare AD, Ghosh P, Venkata S, Raygude KS, Bodhankar SL. Ameliorative effect of naringin in acetaminophen-induced hepatic and renal toxicity in laboratory rats: role of FXR and KIM-1. *Ren Fail.* 2016;38(6):1007-1020. [10.3109/0886022X.2016.1163998](https://doi.org/10.3109/0886022X.2016.1163998)
31. Jeong T Bin, Kim J-H, Kim SH, Lee S, Son SW, Lim Y, et al. Comparison of toxic responses to acetaminophen challenge in ICR mice originating from different sources. *Lab Anim Res.* 2019;35:1-7. [10.1186/s42826-019-0017-x](https://doi.org/10.1186/s42826-019-0017-x)
32. Zaher H, Buters JTM, Ward JM, Bruno MK, Lucas AM, Stern ST, et al. Protection against acetaminophen toxicity in CYP1A2 and CYP2E1 double-null mice. *Toxicol Appl Pharmacol.* 1998;152(1):193-199. [10.1006/taap.1998.8501](https://doi.org/10.1006/taap.1998.8501)
33. Mossanen JC, Tacke F. Acetaminophen-induced acute liver injury in mice. *Lab Anim.* 2015;49(1_suppl):30-36. [10.1177/0023677215570992](https://doi.org/10.1177/0023677215570992)
34. Muthukanagarajan SJ, Karnan I, Srinivasan P, Sadagopan P, Manickam S. Diagnostic and prognostic significance of various histopathological features in extrahepatic biliary atresia. *J Clin Diagnostic Res.* 2016;10(6):EC23. [10.7860/JCDR/2016/19252.8035](https://doi.org/10.7860/JCDR/2016/19252.8035)
35. Greuter T, Shah VH. Hepatic sinusoids in liver injury, inflammation, and fibrosis: new pathophysiological insights. *J Gastroenterol.* 2016;51:511-519. [10.1007/s00535-016-1190-4](https://doi.org/10.1007/s00535-016-1190-4)
36. Wandile PM. Approach to Acute Kidney Injury: Diagnosis and Management. *Open J Nephrol.* 2023;13(3):306-316. [10.4236/ojneph.2023.133027](https://doi.org/10.4236/ojneph.2023.133027)

تقييم السمية الحادة للأسييتامينوفين في الفئران

سهاد محمد هاشم، فلاح موسى كاظم الركابي

فرع الفلسفة والكيمياء الحياتية والادوية، كلية الطب البيطري، جامعة بغداد، بغداد، العراق

الخلاصة

يعد الأسييتامينوفين مسكن ألم شائع الاستخدام ضد الالام الحادة والمزمنة عند البشر والحيوانات. إن حقيقة انتشار التسمم بالأسييتامينوفين كانت وراء الهدف الرئيسي لهذه الدراسة، وهو تقييم السمية الحادة للأسييتامينوفين من خلال تقدير الجرعة السامة المتوسطة في الفئران كنموذج تجريبي. تم تقسيم ما مجموعه ستين فأراً ذكوراً من سلالة Balb/c بعمر 8 أسابيع ونطاق وزن 20-30 جم إلى ست مجموعات متساوية تلقت جرعات مختلفة من الأسييتامينوفين (150، 200، 300، 400، 500، و 700 ملغ لكل كغم من وزن الجسم) عن طريق الفم كجرعة واحدة، بينما تلقت المجموعة السادسة ماء مقطر عن طريق الفم كجرعة واحدة واعتبرت مجموعة سيطرة. تم احتساب الجرعة السامة المتوسطة بطريقة البروبيت. وخضعت جميع الحيوانات للمراقبة لمدة 24 ساعة لأي علامات سمية سريرية التي أظهرت مؤشرات شديدة للتسمم، بما في ذلك الانبساط، والبول النموي، والاضطراب المفرط، والدموع، والزرقة في الأغشية المخاطية، والرقود كانت الجرعة السامة المتوسطة لعقار الأسييتامينوفين عن طريق الفم هي 732 ملغم لكل كيلوغرام من وزن الجسم بعد 24 ساعة. تم الحصول على عينات من الكبد والكلى من الحيوانات للكشف عن أي تغيرات مرضية. تم ملاحظة علامات الجرعة السامة في معظم الحيوانات. أظهر الفحص المجهرى للكبد وجود احتقان في الوريد المركزي، يصاحبه تنكس في خلايا الكبد وتضيق في الجيبانبات الكبدية. أظهر الفحص المجهرى للكلى تنكس في الكبيبات، وانتفاخ خلوي حاد للنبيبات. بالإضافة إلى ذلك، تم ملاحظة وجود خلايا لمفاوية متجمعة حول الوعاء الدموي، جنباً إلى جنب مع تنكس النبيبات. وأخيراً توفر هذه الدراسة رؤى حول ملف السمية الحادة لعقار الأسييتامينوفين. بالإضافة إلى أنه نتاج هذه التجربة لا تسلط الضوء فقط على المخاطر المحتملة المرتبطة باستخدام الأسييتامينوفين، ولكنها تبرز أيضاً ضرورة المراقبة المكثفة للتحكم الدقيق في الجرعة. بالإضافة إلى ذلك، هناك حاجة لمزيد من البحث لتوضيح الآليات الكامنة وراء سمية العقار المذكور وتمهيد الطريق لتطوير استراتيجيات علاجية فعالة لمواجهة الجرعات الزائدة منه.

الكلمات المفاحية: الأسييتامينوفين، مسكن ألم، السمية الحادة، الفئران