



Therapeutic Trial of Modified Levofloxacin (MOLVX) Against Induced Colorectal Aberrant Crypt Foci (Precancerous Tissue) in Mice

Mohammed K Tarab*¹ , Falah M AL-Rekabi² 

¹Department of Clinical Pharmacology, College of Medicine, University of Kirkuk, Kirkuk, Iraq, ²Department of Physiology, Biochemistry and Pharmacology, College of Veterinary Medicine, University of Baghdad, Baghdad, Iraq

A B S T R A C T

Colorectal cancer ranks as the third most commonly diagnosed cancer and the second leading cause of cancer-related deaths globally. Fluoroquinolones, particularly Levofloxacin, have garnered interest for their potential anti-cancer effects, primarily due to their high affinity for metallic ions like copper. This affinity enhances their spectrum of activity and enables greater interaction with DNA in cancer cells, thereby inhibiting proliferation. Building on our prior work, where we synthesized copper-modified Levofloxacin (MOLVX), this study explores its therapeutic potential in treating precancerous colorectal lesions, known as Aberrant Crypt Foci (ACF), in a murine model. Sixty female Balb-C mice were randomized into six groups (n=10 per group). The first group served as a negative control and received no treatment. The remaining groups were administered azoxymethane (AOM) at 10 mg/kg body weight (BW) twice weekly to induce ACF. Among these, the second group acted as a positive control and received no further treatment. The third group was intraperitoneally administered doxorubicin at 16.2 mg/kg BW once a week for four weeks. The fourth group was treated with Levofloxacin at 25 mg/kg BW via oral lavage daily for four weeks. The final two groups received daily oral lavage treatments of MOLVX at doses of 5 mg/kg and 2.5 mg/kg BW for four weeks, respectively. Histopathological analysis of ACF tissues, stained with hematoxylin and eosin, revealed a statistically significant reduction ($P<0.05$) in ACF count among groups treated with MOLVX, doxorubicin, and Levofloxacin, compared to the positive control. Additionally, both MOLVX-treated groups showed a significant decrease ($P<0.05$) in proliferating cellular antigen (PCNA) levels. In conclusion, both MOLVX dosages (2.5 mg/kg and 5 mg/kg BW) demonstrated promising therapeutic efficacy against precancerous colorectal lesions in mice. However, the 5 mg/kg BW dose appeared to be more potent.

Keywords: colorectal cancer, MOLVX on ACF, therapeutic trial of MOLVX, levofloxacin

*Correspondence:

dr.turab.pharma@uokirkuk.edu.iq

Received: 24 September 2022

Accepted: 12 November 2022

Published: 29 December 2022

DOI:

<https://doi.org/10.30539/ijvm.v46i2.1554>



This article is an open access distributed under the terms and conditions of the Creative Commons Attribution License (CC BY 4.0)

Cite:

Tarab MK, Al-Rekabi FM. Therapeutic trial of modified levofloxacin (MOLVX) against induced colorectal aberrant crypt foci (precancerous tissue) in mice. *Iraqi J. Vet. Med.* 2022;46(2):53-65

INTRODUCTION

Colorectal carcinoma (CRC) is the world's second most frequent disease, with the second-highest death rate when compared to other cancers (1). The disease path is characterized by the development of abnormal crypt foci, polyps, mucosal cell clusters, adenocarcinoma, and adenomas (2). Because of exposure to toxins associated with food, the gut has high acceptability for the occurrence of cancer disease lesions, and the epithelial cells have a rapid ability to turnover, therefore, during this period, colorectal cancer will be converted from adenoma to

carcinoma stage (1). Colorectal cancer etiological agents include molecular, genomic, and pathological changes (3,4). Azoxymethane (AOM)-induced morphological changes were linked to the formation of abnormal crypt foci (ACF) and damaged DNA of the proliferating cells (5).

Some quinolones have anticancer properties in addition to antibacterial properties (6), anti-inflammatory properties (7), antiviral (8), and antifungal (9). Quinolones are promising anticancer agents, with some of them currently undergoing clinical trials (10). Furthermore, the first anticancer quinolone in its class to receive FDA

approval for the treatment of acute myeloid leukemia was levofloxacin (11). There is much research into the potential anticancer effect of various antibacterial fluoroquinolones that were thoroughly studied and used in medicine. Fluoroquinolone drugs, as some anti-cancer medications such as doxorubicin, can inhibit the type II topoisomerases necessary for DNA replication in eukaryotic cells to produce an antitumor effect (12). Compared to other topoisomerase II inhibitors and having desirable physicochemical properties, fluoroquinolones have a lower level of toxicity, emerging and developing resistance and proclivity for the development of drug-induced secondary neoplasia, and higher potency (13).

Several studies on the potential genotoxic and cytotoxic effects of fluoroquinolones, including levofloxacin, were conducted using various *in vivo* and *in vitro* studies (14–16). It was discovered that some drugs that are not anticancer have recently been discovered like Levofloxacin may play a significant role in breast cancer treatment (17) and Levofloxacin decreases cancer cell proliferation, clone formation, and xenograft tumor growth by arresting cells in G2/M and promoting apoptosis (18). Importantly, Quinolones' structural characteristics that are necessary for their anticancer activity were identified. The majority of the structural changes required to convert fluoroquinolones from antibacterial to anticancer analogs happened at position 3 (carboxylic group) and position 7 (cyclic amino group) (12).

Derivatives of copper phenanthroline exhibit significant biological activity, such as antitumor activity and nuclease (19). A 1,10-phenanthroline-derived copper complex has effective DNA cleavage activity (20). Copper (II) complexes are crucial in naturally occurring biological systems such as [Cu, Zn-superoxide dismutase (SOD)]. SOD is important to organisms for eliminating a load of reactive superoxide radicals since it degrades superoxide quickly (20). Copper-based complexes are now widely recognized as the best alternative to cisplatin drugs and are widely used in cancer chemotherapy (21). Interestingly, Because of the effectiveness of levofloxacin and levofloxacin-metal-based complexes in several experimental *in vivo* and *in vitro* cancer research (22). Thus, the current study aimed to investigate the potential anti-colorectal cancer activity of chemically modified levofloxacin (MOLVX) in AOM-induced colorectal cancer mice, using immunohistochemistry (IHC) assay for detection of PCNA and histopathological method for detecting changes of ACF.

MATERIALS AND METHODS

All procedures used in this study were reviewed and approved by the Scientific Committee of Pharmacy and Toxicology Department, College of Veterinary Medicine, University of Baghdad in compliance with the ethical principles of animal welfare.

Preparation of Animals

We received 60 adult healthy female albino Balb-C mice from the National Center of Drug Control and Research. These mice were maintained in the animal house of the University of Baghdad, College of Veterinary Medicine, and employed in the current study. At 7-10 weeks of age, and weighing 22-41 g, they were all healthy. Plastic cages containing hardwood chips for bedding were changed weekly to maintain a sanitary environment. Mice were kept in an air-conditioned room at 25 °C±2 with a 13/11 light/dark cycle. The mice were housed in conventional laboratory settings with *ad libitum* food and water.

Preparation of Azoxymethane Injection

Azoxymethane (AOM), A5486-25MG, 13.4 M, ≥98%, ampoule 25 mg SEGMA-ALDRICH PCode: 1002937430 USA, for stock solution 0.5 mg/mL, AOM ampoule was dissolved in sterile 50 mL 0.09% normal saline and kept at 4 °C. The dose volume was 0.1 mL per 10 g of mice weight, which represents the ideal dose of 10 mg/kg BW (23) for induction of aberrant crypt foci.

Preparation of levofloxacin solution

The raw material of the levofloxacin (TaviPharma, Holand) stock solution was prepared by dissolving raw levofloxacin 25 mg complete to 10 mL distilled water to get a final concentration of 2.5 mg/mL. The dosing volume given to the mouse was 0.1 mL/10 g of mouse body weight according to.

Preparation Doses of the MOLVX

The first dose of 5 mg/kg was prepared by dissolving 2.5 mg of MOLVX and 5 mL distilled water which equals 50-fold cytotoxic concentration. The final concentration will be 0.5 mg/mL, and the dosage rate becomes 0.05mg/10 g BW and each mouse received 0.1mL/10 g BW. The second dose of 2.5 mg/kg was prepared by dissolving 1.25 mg of MOLVX in 5 mL distilled water, where 2.5 mg is equal to 25 folds of cytotoxic concentration.

The above-modified levofloxacin (MOLVX) that has been used in this study was prepared by our previous experiment, which was published in the International Journal of Health Sciences in the upcoming special issue of 2022 (24), using Schiff's base method, where the chemical formula of MOLVX is $[\text{Cu}(\text{Levo})(\text{Phenan})\text{Cl}]\text{Cl}$, molecular weight = (C30H33Cl2CuFn5O4) 681.07 g/mol⁻¹.

Preparation of Doxorubicin Solution

Based on the species' actual body weight, it is possible to accurately convert a mg/kg dose to a mg/m² dose. The surface area was computed using the formula mg/m²=km mg/kg for converting doses. For all species, the *K_m* factor fluctuates and rises as body weight does (25). The dose was converted from mg/m² to mg/kg divided by a factor of 37, Human Equivalent Dose (HED)=16/37= 0.432 mg/kg BW in humans (16= is the intermediate dose that causes a less

cardiotoxic effect in humans, which is used for minimizing cardiotoxicity). To convert the dose from humans to mice, it was divided by factor 12(2) Animal Equivalent Dose (AED)= Human dose \times K_m ratio, where k_m is the factor (26) This yielded a dose of 0.053 mg/10 g BW in mice, which is equivalent to 5.3 μ g/10 g BW or 530 μ g/kg BW.

To prepare a 5 μ g/mL concentration solution of doxorubicin for fitting the dose of 5 μ g/10 g BW/mice in 0.1 mL of doxorubicin solution: ampoule of doxorubicin 50 mg was dissolved up to 25 mL normal saline to get the concentration of 2 mg/mL (stock solution). It was taken of 0.5 mL from a stock solution that contained 1 mg of doxorubicin, then completed up to 20 mL to get 50 μ g/mL, So, the dosing volume was 0.1 mL/10 g BW mice, which represented the curative dose of doxorubicin.

Grouping of the Animals

On the day of the experiment, the thirty-six mice were randomly divided into six equal groups, Control Negative healthy animal without induction, and was administered normal saline for a month. Control positive included animals that were by 10 mg/kg BW-IP of AOM once weekly for two weeks without any treatment. After 2 weeks they received 0.1 mL of normal saline once daily for 4 weeks. Group (doxorubicin) animals induced with AOM were then treated with doxorubicin (16.2 mg/kg BW) once weekly for 4 weeks. Group (levofloxacin) animals induced with AOM were then treated with Levofloxacin 25 mg/kg BW, once daily for a month. Group (5mg MOLVX) animals induced with AOM then treated with and then treated with modified levofloxacin 5 mg/kg (MOLVX) 0.1 mL/10 g BW once daily for a month. Group (5mg MOLVX) animals induced with AOM then treated with and then treated with modified levofloxacin 5 mg/kg (MOLVX) 0.1 mL/10 g BW once daily for a month.

Identification of Aberrant Crypts Foci (26 Bird, 1987).

All animals were sacrificed with diethyl ether after four weeks following the second AOM injection. After sacrifice, the colon and rectum and flushed with ice-cold PBS to eliminate any material then opened longitudinally and preserved in 10% neutral buffered formalin. A specialist pathologist identified and counted ACF after 24 hours in fixative. The colon was stained with methylene blue on the slide under the microscope after counting the ACFs, removing the stain by adding methanol at 25 °C. ACF differed from surrounding normal crypts by size, extended luminal entrance, greater separation between cells' luminal and basal surfaces, 2 or more aberrant crypts with thickened epithelial 54-cell linings, and larger pericryptal region (27, 28). After counting ACFs, the dye was removed with 70% methanol and moderate shaking for 4-6 min to prepare sections for hematoxylin and eosin (H&E) staining.

IHC for PCNA Procedure

IHC labeling was used to assess the presence of the specified proteins in the colonic tissues. The experiment was conducted according to the previously mentioned specifics (29). The program Image J software was used to grade each stained segment, with 0 representing negative, weakly positive, positive, and strongly positive, for 1, 2, and 3 respectively. According to the staining intensity and percentage of the positive area, an average score was utilized to measure the relative expression of proteins.

The IHC was applied according to the manufacturer's instructions using the Dako "EnVision detection immunohistochemistry kit (Envision FLEX, Dako, K8000, Denmark). Primary anti-PCNA (rabbit polyclonal anti-PCNA antibody: E-AB-70004, Elabscience, China) was used to detect PCNA protein expression in this study. Anti-PCNA 100-fold dilutions of primary antibodies (EnVision FLEX Antibody Diluent, Dako, K8006, Denmark). Sections of paraffin-embedded large intestinal tissue were cut at 4 μ M and mounted on positively charged glass slides (CrystalCruz® Electro-Staticly Charged Micro Slides, sc-363562, Santa Cruz Biotechnology, USA) using a hot plate (K&K HYSH11, Korea). Preheated the large intestine tissue section to 55 °C, deparaffinized it twice (10 min each), and rehydrated it in four changes of 100%, 100%, 90%, and 70% ethanol alcohol for 2 min each. Rinsed tissue slices were submerged in tris-buffered saline (TBS, SM831) for 5 min. After wiping, the excess buffer was tapped off". Rinsed tissue pieces were immersed for 5 min in TBS. Tissue sections were incubated at 97 °C for 25 min in EnVision™ FLEX Target Retrieval Solution, High pH, DM828. Tissue sections were soaked in a TBS buffer solution for 5 min after 20 min in cold water. Tissue paper was used to wipe off the excess buffer. Tissue slices on glass slides were circled with a wax pen (Gene Tech Pen, Elabscience, E-BC-R531, China) to contain the reagent. Tissue slices were submerged for 5 min in EnVision FLEX Wash Buffer (SM831). "Wipe off tissue buffer. Tissue sections were flooded with 100 μ L of peroxidase-blocking reagent (SM801) and incubated in a humidity chamber for 10 min before being rinsed and submerged in two changes of TBS buffer bath for 5 min each. Tapping and wiping removed tissue slide buffer. The sections were incubated with anti-PCNA primary antibodies for one hour at room temperature, then washed and submerged in two changes of TBS buffer bath (EnVision FLEX Wash Buffer) for 5 min each. Tissue pieces were cleaned to remove the excess buffer. Next, 100 μ L of secondary antibody colored with horseradish peroxidase (EnVision FLEX/HRP, SM802) was applied to tissue sections and incubated at room temperature for 30 min before being rinsed and submerged in two changes of TBS buffer bath (EnVision FLEX Wash Buffer, SM831). Tissue paper removed extra buffer. 100 μ L of DAB plus a substrate-chromogen solution which was applied to tissue slices and incubated for 10 min. After rinsing, sections were given 2-

5 minute TBS buffer baths (EnVision FLEX Wash Buffer, SM831). Counterstaining with Mayer hematoxylin (Bio-Optica, 05-06002/L, Italy) took 3 min. Two-minute drains were performed in 70%, 90%, and 100% ethanol. After two 10-minute xylene washes, tissue sections were mounted with DPX and coated with coverslips. Tissue sections were magnified 100× and 400×. IHC was assessed according to (30). The quantity score (QS) of stained tumor cells was estimated as follows: Estimation of staining intensity was scored into (1) being the most negative; (2) being the weakest positive; (3) being the strong positive; According to the staining intensity and percentage of the positive area, an average score was utilized to measure the relative expression of proteins. follows: score 0, no staining; score 1, weak staining; score 2; moderate staining; and score 3, strong staining. The IHC score was obtained from the multiplication of the staining intensity scores and expression scores.

Statistical Analysis

A one-way Analysis of Variance (ANOVA) was used to assess the differences between means at $P \leq 0.05$ during the

procedure using SPSS version 24. For comparing between means, the least significant differences (LSD) were used.

RESULTS

Body Weight

The results of the body weight summarized in Table 1 showed that there was a significant ($P < 0.05$) decrease in the third week from the beginning of the experiment exactly at the second dose of AOM in all groups in comparison with positive control. Also, there were no significant differences between the groups treated with (doxorubicin) and the group treated with (levofloxacin) in comparison with the control negative. Groups treated with MOLVX5 mg/kg and group (MOLVX2.5 mg/kg) showed a significant decrease ($P < 0.05$) in comparison with the control positive, especially from the third till the end of the last week of the experiment, and the group treated with (AOM and doxorubicin) and the group treated with (levofloxacin) as well. Interestingly, the result showed no significant change in the 7th and the last week of the experiment between the control positive and control negative.

Table 1. Body weight (g) of experimental groups

Groups	Induction			Weeks After treatment			
	Before	1 week	3 weeks	4	5	6	7
Negative control	32±1.81	32±2.11	33±2.08 ^{ab}	33±2.14 ^a	34±1.95 ^{ab}	35±1.86 ^a	35±1.88 ^a
Positive control (AOM)	33±2.83	29±2.30	37±1.51 ^a	32±3.25 ^{ab}	38±3.31 ^a	34±2.65 ^{ab}	35±3.25 ^a
AOM+Doxorubicin	33±0.80	31±0.71	30±1.00 ^{bc}	31±0.99 ^{ab}	32±0.85 ^b	30±0.92 ^{bc}	30±1.11 ^b
AOM+Levofloxacin	30±1.16	30±1.14	31±1.35 ^b	30±0.95 ^{ab}	31±0.89 ^{bc}	30±0.94 ^{bc}	30±0.69 ^b
AOM+MOLVX5	32±1.51	30±1.09	25±1.30 ^d	25±1.22 ^c	26±1.05 ^d	28±0.46 ^c	29±0.71 ^b
AOM+MOLVX2.5	32±1.04	30±0.91	27±0.32 ^{cd}	28±0.73 ^{bc}	28±0.79 ^{cd}	28±0.42 ^c	29±0.47 ^b
LSD	4.29	3.99	3.81	4.521	4.036	3.769	4.153
P-value	0.694	0.581	<0.0001	0.0072	<0.0001	0.0031	0.0035

Values are means±SEM, n = 6 per treatment group. ^{a-d}Means in a column with different superscript letters significantly different ($P \leq 0.05$). The negative control group (was G1) administered normal saline; the Positive control group (G2) injected with 10 mg/kg BW intraperitoneal (I.P.) of azoxymethane (AOM) once weekly for two weeks without any treatment, after 2 weeks received only 0.1 mL of normal saline once daily for 4 weeks; AOM+Doxorubicin group (G3), injected with 10 mg/kg BW I.P. of AOM once weekly for two weeks, then treated with doxorubicin (16.2 mg/kg BW) once weekly for 4 doses; AOM+Levofloxacin group (G4), injected with 10 mg/kg BW I.P. of AOM once weekly for two weeks, then treated with levofloxacin (25 mg/kg BW) once daily for 30 days; AOM+MOLVX5 (G5) and AOM+MOLVX2.5 (G6), injected with 10 mg/kg BW I.P. of AOM once weekly for two weeks, then treated with 5 mg/kg and 2.5 mg/kg of modified levofloxacin (MOLVX 5mg and MOLVX 2.5mg, respectively) once daily for 30 days

Table 2. Aberrant crypt foci (ACF) of experimental groups

Groups	Number of ACF
Negative control	9.628±0.793 ^a
Positive control (AOM)	0.000±0.000 ^f
AOM+Doxorubicin	2.880±0.427 ^c
AOM+Levofloxacin	3.504±0.257 ^b
AOM+MOLVX5	1.772±0.240 ^d
AOM+MOLVX2.5	1.094±0.174 ^e
LSD	1.763

Histopathological Study

ACF histopathology

Histopathological examination of ACF has been done by a consultant pathologist under a light microscope using H&E staining. The result of ACF showed that otherwise a significant ($P < 0.05$) decrease in ACF of all treated groups

group (AOM and doxorubicin), group (AOM and Levofloxacin), group (AOM and MOLVX5 mg/kg), group (AOM and MOLVX2.5 mg/kg) in comparison with Control positive which received azoxymethane only) (Table 2).

In the current study, the results of ACF demonstrate greater cellularity (cellular hyperplasia), loss of goblet cell population, elongation of nuclear, loss of cellular.

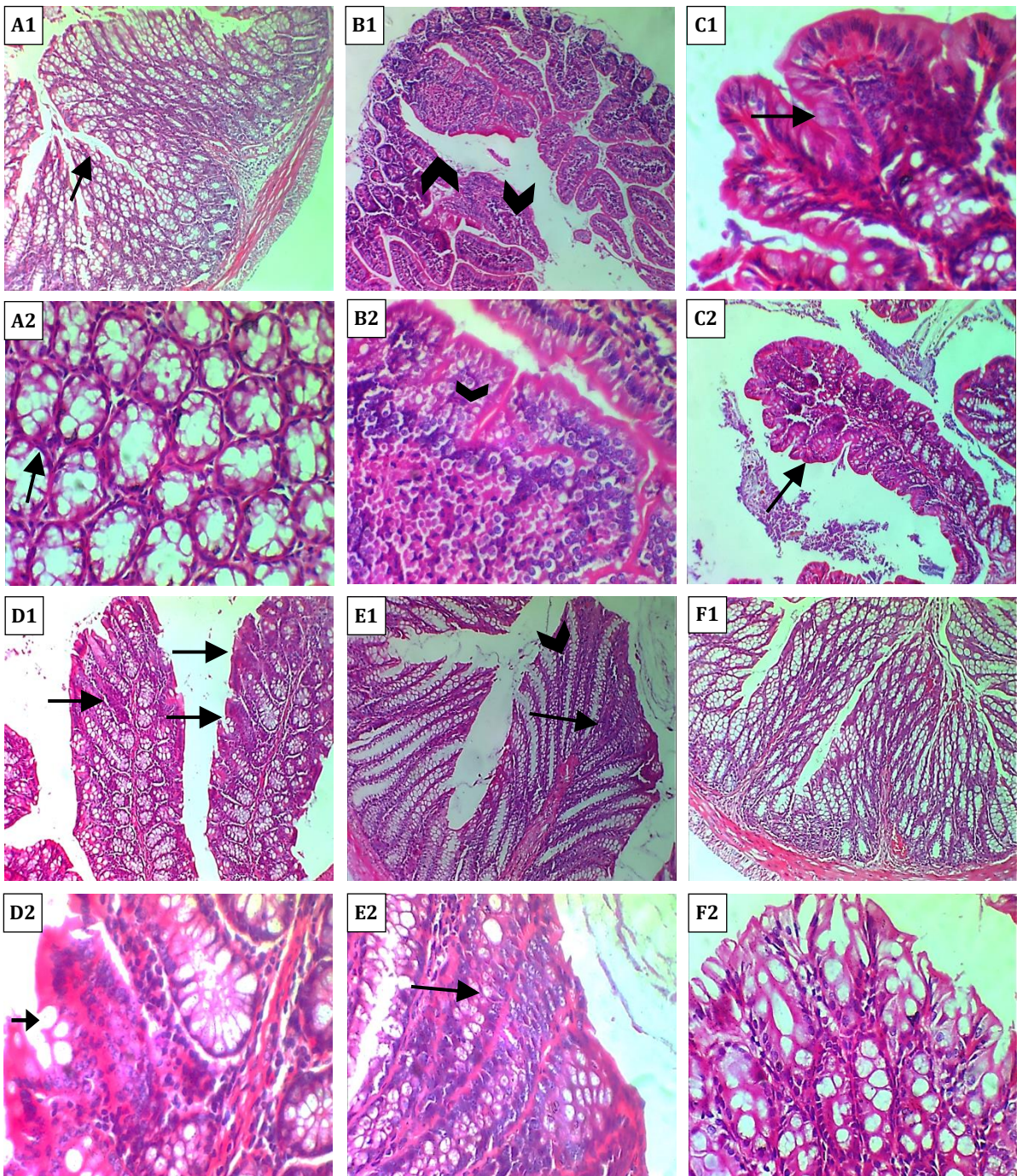


Figure 1. Histopathological section (H&E) of adult local Balb-C female mice colon in (A1, A2) Negative control group (G1) showing the normal histological structure of the colon. A1: 10× and A2: 40×. (B1, B2) Positive control group (G2, azoxymethane (AOM group)) mice showing dysplastic aberrant crypt foci feature manifested with enlarged villi (arrowhead) of the colon due to proliferation of pleomorphic neoplastic epithelial cells, where the neoplastic cells showed eosinophilic and basophilic color. Also, mitotic activity (arrow) was observed in neoplastic cells. B1: 10× and B2: 40×. (C1, C2) AOM+Doxorubicin 16.4 mg/kg group (G3) mice showing hyperplastic aberrant crypt foci manifested with the proliferation of preneoplastic cells (arrow [both 10× and 40×]) in the villus head led to enlarge of the affected villus head. C1: 10× and C2: 40×. (D1, D2) AOM+Levofloxacin 25 mg/kg group (G4) mice showing hyperplastic aberrant crypt foci manifested with the proliferation of preneoplastic cells (arrow) in the villus. D1: 10× and D2: 40×. (E1, E2) AOM+modified levofloxacin 5 mg/kg (MOLVX5) group (G5) mice showing the colon villi showed normal histology features with the presence of mild hyperplasia (arrow) of epithelial cells in the head of the villi. E1: 10× and E2: 40×. (F1, F2) AOM+modified levofloxacin (MOLVX) 2.5 mg/kg group (G6) mice. The colon villi showed normal histology. It is seen that the tissues undergo a slow restoration process, characterized by a reduction in the occurrence of aberrant crypt foci (ACF) and a decline in mitotic activity. F1: 10× and F2: 40×

orientation, enlarged villi of the colon due to the proliferation of pleomorphic neoplastic epithelial cells in the AOM group (Figure 1 B1, B2) show in comparison to normal histological findings of the colon. The experimental groups, group (G5) administered MOLVX at a dose of

2.5mg/kg exhibits (figure 1 E1, E2), and group (G6) administered MOLVX at a dose of 5mg/kg (figure 1 F1, F2) have been shown to significantly improve tissue histology, and decrease the number of ACF and demonstrated a statistically significant decrease ($P < 0.05$) in the number of

aberrant crypt foci (ACF) compared to the positive control group (Table 2). Based on these findings presented it can be inferred that MOLVX, administered at both doses, has superior efficacy compared to the other medications examined in this study. Specifically, MOLVX demonstrates notable effectiveness in addressing precancerous tissue damage caused by the carcinogenic chemical AOM, as well as in avoiding colorectal cancer (CRC) in individuals with high-risk adenomas. Nevertheless, it is imperative to conduct more extensive and prolonged investigations to validate these discoveries

PCNA Labeling Index

The results of PCNA scoring showed various percent areas of stained tissue and intensity of staining (Table 3).

The treatment period took a month with once-daily administration; the treated groups showed a therapeutic effect on experimental Azoxymethane-induced adenocarcinoma in mice in comparison to the positive group. Groups treated with 2.5 mg/kg MOLVX, 5 mg/kg MOLVX, Levofloxacin, and doxorubicin exhibited a significant decrease ($P < 0.05$) in comparison with control positive. Therefore, the current study found that MOLVX2.5 mg/kg is a more effective drug than other treated groups, which is assumed to function as anti-PCNA, so, it is considered the best antiproliferative agent in the current study according to the above findings as Figure 2 (A, B, C, D, E, and F).

Table 3. Proliferating cell nuclear antigen (PCNA) of experimental groups

Groups	Stained cells (%)	Score quantity	Stain intensity	Score intensity	Total score	PCNA-LI % M±SE
Negative control	70	1	No stain	Zero	0	0.00±0.00 ^d
	80	1	No stain	Zero	0	
	75	1	No stain	Zero	0	
	75	1	No stain	Zero	0	
	70	1	No stain	Zero	0	
Positive control (AOM)	90	4	Strong	Three	12	10.8±0.73 ^a
	80	3	Strong	Three	9	
	85	4	Strong	Three	12	
	70	4	Strong	Three	12	
	80	3	Strong	Three	9	
AOM+Doxorubicin	15	3	Moderate	Two	6	7.20±1.36 ^b
	15	2	Moderate	Two	4	
	10	4	Moderate	Two	8	
	5	3	Moderate	Two	6	
	10	4	Strong	Two	12	
AOM+Levofloxacin	90	2	Moderate	Two	4	3.20±0.49 ^c
	90	2	Moderate	Two	4	
	75	2	Moderate	Two	4	
	80	2	Weak	One	2	
	75	2	Weak	One	2	
AOM+MOLVX5	75	1	Moderate	Two	2	1.80±0.20 ^{cd}
	85	1	Moderate	Two	2	
	85	1	Moderate	Two	2	
	90	1	Moderate	Two	2	
	75	1	Weak	one	1	
AOM+MOLVX2.5	65	0	Weak	One	0	0.80±0.37 ^d
	80	1	Weak	One	1	
	75	1	Moderate	Two	2	
	80	1	Weak	One	1	
	75	0	No staining	One	0	
LSD						1.993
P-value						<0.001

Values are means±SEM, n = 5 per treatment group. ^{a-d}Means in a column with different superscript letters significantly different ($P \leq 0.05$). The negative control group (G1) was administered normal saline; the Positive control group (G2) was injected with 10 mg/kg BW intraperitoneal (I.P.) of azoxymethane (AOM) once weekly for two weeks without any treatment, after 2 weeks received only 0.1 mL of normal saline once daily for 4 weeks; AOM+Doxorubicin group (G3), injected with 10 mg/kg BW I.P. of AOM once weekly for two weeks, then treated with doxorubicin (16.2 mg/kg BW) once weekly for 4 doses; AOM+Levofloxacin group (G4), injected with 10 mg/kg BW I.P. of AOM once weekly for two weeks, then treated with levofloxacin (25 mg/kg BW) once daily for 30 days; AOM+MOLVX5 (G5) and AOM+MOLVX2.5 (G6), injected with 10 mg/kg BW I.P. of AOM once weekly for two weeks, then treated with 5 mg/kg and 2.5 mg/kg of modified levofloxacin (MOLVX5 and MOLVX2.5, respectively) once daily for 30 days

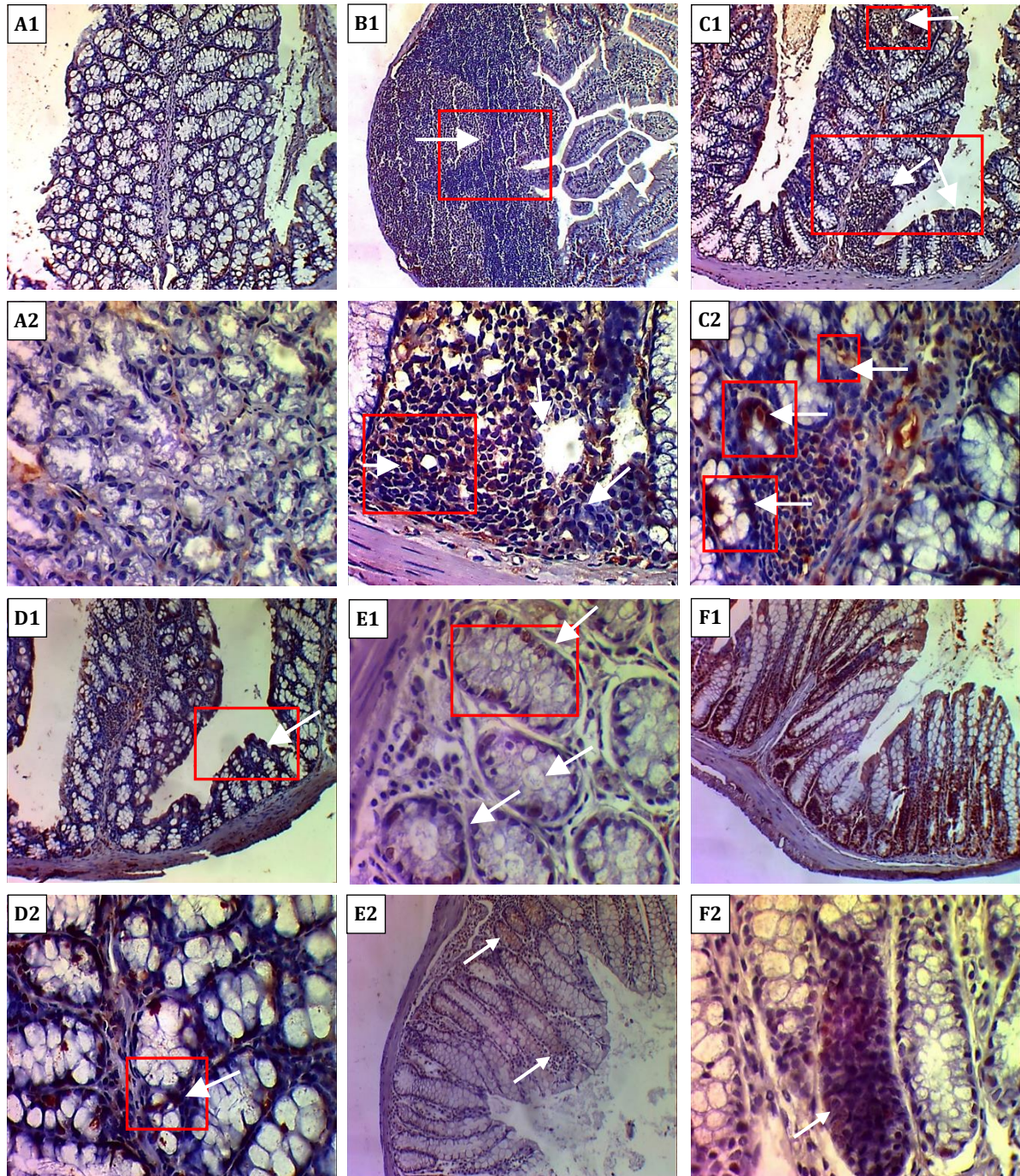


Figure 2. Photomicroscopic image (DAB & hematoxylin stain) of adult local Balb-C female mice colon in **(A1, A2)** Negative control group (**G1**) mice showing normal expression of proliferating-cell nuclear antigen (PCNA) protein in intestinal epithelial cells (arrows). A1: 100× and A2: 400×. **(B1, B2)** Positive control group (**G2**, azoxymethane (AOM group)) showing overexpression of PCNA (arrowhead) in neoplastic intestinal epithelial cells, with aggregation of neoplastic cells forming a huge mass (arrow) within the villi. B1: 100× and B2: 400×. **(C1, C2)** AOM+Doxorubicin 16.4 mg/kg group (**G3**) mice showing overexpression of PCNA protein (arrows) in neoplastic intestinal epithelial cells, with aggregation of neoplastic cells forming a mass in affected villi. C1: 100× and C2: 400×. **(D1, D2)** AOM+Levofloxacin group (**G4**) mice showing expression of PCNA protein in intestinal epithelial cells (arrows). D1: 100× and D2: 400×. **(E1, E2)** AOM+modified levofloxacin 5 mg/kg (MOLVX5) group (**G5**) mice showing normal expression of PCNA protein in intestinal epithelial cells (red section) of villi and crypts (white arrows). E1: 100× and E2: 400×. **(F1, F2)** AOM+modified levofloxacin 2.5 mg/kg (MOLVX2.5) group (**G6**) mice showing overexpression of PCNA protein in intestinal epithelial cells (arrows) of villi and crypts (arrowhead). F1: 100× and F2: 400×

DISCUSSION

Effect of MOLVX and levofloxacin on the body weight and the ACF

Weight loss and wasting can occur in up to 80% of cancer patients, according to (31). Wasting is losing weight and muscle. In addition, cancer patients feel fatigued, weak, and have energy loss (32), examined the changes in body weight following the transferring of CD4+CD25- T cells and AOM therapy, and after treatment (AOM/TRANS) showing loss of body weight in mice. All induced animals showed clinical and histological symptoms of colitis, such as sticky feces, diarrhea, and inflammation, however, their body weight began to differ from the non-transplanted AOM group during the last 10 days of the experiment. From day 7 to 39, the TRANS/ AOM group showed more severe body weight loss, which is inconsistent with our findings that there was no significant decrease in body weight of all experimental groups throughout the study period". This could be supported by the absence of any clinical signs that may contribute to weight loss, such as anorexia, diarrhea, vomiting, and a slight change in stomach epithelium and adjusted gland. This finding is consistent with our results, which have seen there were minor significant changes in the body weight of control negative and control positive groups along the period of study that may be attributed to plats with high riched protein being used in the feeding of experimental animals, these could be supported by the absence of any clinical signs that may contribute to weight loss like poisonings such as anorexia, diarrhea, and vomiting; on the other hand, the treated groups exhibit significant variations within the same group based on treatment period as well as between groups that may attribute to drug's adverse effects, these effects could involve changes in bowel microflora and a slight change in stomach epithelium and adjusted gland. Furthermore, amelioration in body heath in all treated groups especially groups of MOLVX 5mg/kg and 2.5mg/kg resulted in a gradual increase in body weight.

Azoxymethane affects colon crypt histology leading to weight loss and inflammation when it is given to animals. AOM causes cryptal morphological changes in the large intestine as a decrease in crypt numbers and an increase in crypt width (aberrant crypts), thickened epithelial cell lining, irregular lumen, increasing pericryptal space, and elevation from mucosa which is associated with colon inflammation (26). In a study, dysplastic properties similar to those seen in colonic tumors were discovered in the colons of AOM-treated rats. The absence of sparse production of mucins is the most prominent feature of this lesion (33). This lesion also has distorted cryptal lumens that are smaller than the surrounding crypts, elevation from the mucosa, and crypt multiplicity of more than three crypts (34). However, AOM administration to mice in our study resulted in no significant changes in body weight,

possibly due to the short period of administration and no impairment in the absorption process, which produces precancerous tissue in the colon.

Many researchers have used the formation of ACF as a biomarker in the early stages of colorectal carcinogenesis. Previously described ACF as a preneoplastic colonic lesion and mucin-depleted foci (MDF) as well. Using the novel A/J Min/+ mouse model, researchers refined the method of detecting flat ACF and further characterized and defined them as early lesions through histological examination and comparison with MDF (35). Like patients with familial adenomatous polyposis, mice with multifocal intestinal neoplasia are heterozygous for a mutation in the tumor suppressor gene *Apc* (FAP). Numerous neoplastic intestinal polyps develop as a result of this mutation. APC inactivation with beta-catenin accumulation mimics would not be signaling pathway stimulation (36, 37).

Mice are one of the best models for colorectal cancer because they spontaneously develop a large number of colonic lesions that evolve from monocystal to adenoma and, eventually, carcinoma (38). Besides that, the efficacy of 41 potential chemopreventive agents in CRC was assessed by (39), who used the inhibition of "AOM-induced ACF" as a measure of efficiency.

The current study found that MOLVX can suppress the early stage of colon cancer by reducing the number and size of aberrant crypt foci induced by (AOM) in mice's colorectal. When compared to the control positive group (AOM), there was a significant $P \leq 0.05$ decrease in ACF in groups treated with MOLVX that received 2.5mg and 5 mg/kg.BW of mice. Histological characteristics and immunohistochemistry features supported by cytotoxicity MTT assay, MOLVX showed much better efficacy in the treatment of precancerous tissue than the other drugs that are used in this study. These findings are unique for this newly synthesized complex (MOLVX), where there are no recent studies about MOLVX related to the therapeutic trial for precancerous tissue in colorectal cancer. Furthermore, groups treated with levofloxacin human equivalent dose (HED) 25 mg/kg and Doxorubicin (HED) 16.2 mg/kg significantly reduced ACF numbers when compared to control positive. Besides that, other histological characteristics confirmed in this study included the restarting of goblet cell populations, a decrease in overall number, and a decrease in cell proliferation. Therefore, depending on these results, MOLVX with both doses is considered the best drug for the treatment of precancerous damaged tissue induced by carcinogenic chemicals (AOM) among all drugs used in this study. "Histopathology illustrations depicted the inspection of hematoxylin and eosin-stained sections figures (6 and 7). Except for the azoxymethane-treated mice (figures 4 and 5), all samples revealed maintained mucosal architecture and higher levels of mitotic activity in the crypts than the non-induced group (control) and those treated with both doses of

MOLVX in the presence of AOM, particularly 2.5 mg/kg, which is possibly due to reduced deleterious effects than larger doses of MOLVX (figures 8 and 9). AOM-induced ACF was studied extensively, this is a potent carcinogenic chemical that is widely used in the evaluation and safety of anticancer drugs leading to the inducing of precancerous tissue (ACF) by different mechanisms including oxidative stress and developing into adenocarcinoma if delayed diagnosis or/and left without treatment or improper treatment (39), our study results confirm the effectiveness of the newly synthesized complex MOLVX against AOM-induced precancerous tissue for a period one-month once-daily administration.

Song and his colleagues (2016) (40) discovered that Levofloxacin (conc. 50-200 g/mL) inhibits cell proliferation and induces apoptosis in lung cancer cells by inducing mitochondrial dysfunction and oxidative damage, this is in agreement with our results, where the group G4 (mice induced by AOM and treated by levofloxacin (LED) 25 mg/kg BW) showed significant inhibition in ACF's numbers in comparison to control positive group, Levofloxacin is the third generation of fluoroquinolones which is commonly used to treat urinary tract infections, diarrhea, anthrax, pneumonia, and some serious infections(41), however, it was recently discovered that Levofloxacin was used in chemotherapy, which causes "mitochondrial damage, that results in oxidative free radical and cell death. It disrupts tubulin assembly and interferes with mitochondrial DNA replication (42). They are being researched for their tumor-killing powers, and their mechanism of action as topoisomerase interrupts (topo enzymes are essential for "normal DNA replication) is being investigated as a chemotherapeutic treatment. Levofloxacin can kill cancerous tumor cells because it also kills eukaryotic cells in addition to bacterial cells; Levofloxacin disrupts the mitochondrial DNA (mtDNA) replication process, which leads to mitochondrial damage, oxidative stress, and cell death (43). In comparison to normal breast cells, levofloxacin has been shown to selectively target breast cancer cells resulting in cell death (44). It should be emphasized that fluoroquinolones with high eukaryotic enzyme activity have the same "DNA-damaging characteristics" as other topoisomerase poisons (45).

In a second investigation, researchers discovered that enoxacin could increase the creation of microribonucleic acids (miRNAs) that inhibit tumor growth by attaching to the miRNA biogenesis protein, trans-activation response RNA-binding protein-2(TRBP) (46). Microribonucleic acids (miRNAs) are small-RNA molecules that regulate "gene expression at the post-transcriptional level". They are essential for many cellular pathways, and their disruption is frequently linked to the development of human tumors (47-49).

Since chromosomal instability (CIN) and microsatellite instability (MSI), these pathways for the development of

CRC have accumulated more evidence. However, no significant increase in chromosome aberration (CA) was observed in the groups MOLVX 2.5 and 5 mg/kg and levofloxacin. This indicates that both groups had a decrease in ACF, and since both groups had a decrease in ACF, mismatch repair deficiency for DNA may be reversed. this is evidence of a decrease in ACF in both groups, and since these two groups showed a decrease in ACF mismatch repair deficiency for DNA may be reversed as indicated by (50).

The current study showed multiple numbers of ACF were seen in the group (control positive) than in other experimental treated groups (Table 2), chromosomal aberrations from the present cytogenetic study, as well as in groups 6 and 5 were treated with (MOLVX 2.5 mg/kg and 5mg/kg BW of mice), which the above agree with study that confirmed by (51) in which it was found that chromosomal instability (CIN) that is characterized by multiple chromosomal abnormalities and a high frequency of loss of heterozygosity(LOH), appears to be the major pathway to colon cancer, as well as these results were confirmed by (52) in which it was suggested that chromosomal abnormalities can occur early in colon neoplasia.

Finally, MOLVX significantly reduced the mean number of ACF, and not all mice tested positive for the presence of ACF in their colon and rectum which is revealed in the table (3). As the above result, the slides that showed negative results for ACF in MOLVX-treated mice were excluded and for that, only 4-5 slides from each group were used for PCNA analysis, which revealed ACF in H&E-stained slides.

Antiproliferative (Anti-PCNA) effect of MOLVX and pure levofloxacin

PCNA immunostaining, according to (53), is a simple tool for prospective studies on pathological material aimed at evaluating the potential relevance of proliferative induced to clinical prognosis or colorectal cancer risk prediction. PCNA is a 36-kDa (auxiliary protein of DNA polymerase delta) that interacts with cyclin D and cyclin-dependent kinases, according to (54). It is found in proliferating cell nuclei and was linked to both "neoplastic and non-neoplastic cell proliferation". Throughout the late G1 and S phases, the Proliferating Cell Nuclear Antigen protein is abundant in growing cells (54). PCNA immunohistochemistry can highlight the proliferative compartment in normal and malignant colonic mucosa. PCNA 's direct relationship with cell proliferation makes it a prognostic factor in colorectal cancer (55).

Proliferating Cell Nuclear Antigen labeling index levels (PCNA-LI) are enhanced by normal large intestine mucosa, hyperplastic polyp, tubular adenoma with low-grade atypia, and tubular adenoma with high-grade atypia and cancer (52). Proliferating Cell Nuclear Antigen labeling index levels in high-grade dysplastic adenomas are raised regardless of histological type or tumor size. Proliferating

Cell Nuclear Antigen labeling index levels (PCNA-LI) are linked to “tumor-grade, vascular invasion, distant metastasis, and prognosis (56). Angiogenesis is usually found after invasive cancer. Even in the premalignant stage, epithelial cells proliferate more field effect and require more blood. Angiogenesis might begin with a tiny adenomatous polyp or aberrant ACF (57).

Qasim et al. (2012) (58) found positive PCNA immunohistochemistry in all colorectal cancer cases and the control group. This is demonstrated by the fact that PCNA is expressed in all proliferating cells, even though intestinal mucosal cells are constantly proliferating and shedding. Furthermore, PCNA is involved in DNA repair, and it is known that Proliferating Cell Nuclear Antigen immunostaining may appear in cases where DNA repairs occur. Furthermore, the Proliferating Cell Nuclear Antigen, in contrast to Ki-67, may still be expressed in cells that have exited the cell cycle (54).

In terms of staining intensity, carcinoma cases had a significantly higher frequency of cases with strong staining, followed by an adenoma, and then control groups. When comparing the three digital parameters of Digimizer software (A: area, N: number of objects, and I: intensity), carcinoma cases had a significantly higher frequency of cases with strong staining. PCNA-LI cells were found in the colonic crypts of normal mucosa. In carcinoma, the stained cells showed a uniform distribution in the lower half of the crypts (the active proliferative zone), indicating a stronger proliferative activity than in adenoma and carcinoma.

Several studies support the current study findings as discovered that the positive rate of PCNA expression increases in a normal mucosa–mucosa-mucosa-mucosa-mucosa-mucosa-mucosa-adenoma-carcinoma sequence (59, 58) and discovered that the positive expression of Proliferating Cell Nuclear Antigen increases significantly during the development of colorectal adenoma to carcinoma (60). Overexpression of PCNA was also connected to lymph node metastases in colorectal cancer, according to (60) Zi-Jian and Li (2001) and (61). (58) and (61) concluded that Proliferating Cell Nuclear Antigen expression in colorectal carcinoma is associated with the degree of differentiation and lymph node metastasis, And this is consistent with what we found in terms of an increase in PCNA expression in animals that were injected with azoxymethane, in contrast to what we found of a decrease in PCNA expression in animals treated with doses of 2.5 and 5 mg/kg BW of MOLVX clearly, and indicates its effectiveness in overcoming cancer cells in the colon.

Kang and Park (2001) (61) discovered a nonsignificant relationship between PCNA expression and colorectal cancer stage. According to (63, 64) PCNA labeling index (PCNA-LI) increased in proportion to the degree of dysplasia and the size of the adenoma.

PCNA expression was found to be significantly higher in a normal mucosa–mucosa-adenoma-carcinoma sequence. It was significantly higher in ≥ 1 cm adenomas and those with severe dysplasia, and it had a significant positive correlation with colorectal carcinoma grade and lymph node involvement (58).

The results of (65) demonstrated that the mean PCNA-LI was significantly correlated with high-grade dysplasia regardless of histologic type of adenoma size. In this study, (66) found that carcinoma cells have significantly higher PCNA-LI than adenomas or control specimens and that PCNA was overexpressed in villous, moderate, or severe dysplastic, and larger adenomas. In addition, the mean Proliferating Cell Nuclear Antigen labeling index levels (PCNA-LI) of the transitional mucosa adjacent to the carcinoma were elevated.

However, because most canine and human osteosarcoma treated with fluoroquinolone improved after surgery, it suggested that fluoroquinolone antibiotics would directly inhibit cell proliferation and survival of canine osteosarcoma cells. “Fluoroquinolones suppress p21WAF1, which decreases cell proliferation and increases S-G2/M (67). Furthermore, fluoroquinolones induce apoptosis in canine osteosarcoma cells as evidenced by caspase-3 and PARP cleavage and caspase-3/7 activation”, these findings provide support for additional research into the potential impact of fluoroquinolones on osteosarcoma survival and cell proliferation (67). Fluoroquinolone exposure also induced apoptosis in canine osteosarcoma cells, as evidenced by caspase-3 and PARP cleavage and caspase-3/7 activation. The findings point to the need for more research into the effects of quinolones on osteosarcoma survival and cell proliferation. The above findings support the effectiveness of MOLVX in the prevention progression of precancerous tissue (ACF) in mice that were treated with both doses of MOLVX groups MOLVX 2.5mg/kg and group MOLVX 5mg/kg and group levofloxacin as well. Fluoroquinolones (FQs), which include levofloxacin(lvx), ciprofloxacin (CPFX), and enrofloxacin (ENFX), target topoisomerase enzymes and thus share a mechanism with traditional anti-neoplastic agents like doxorubicin, irinotecan, and etoposide (68,69).

In our under-publishing manuscript in vitro work, we showed MOLVX's cytotoxic effect on the HRT-18 colorectal cancer cell line. Results of the in vitro study were discussed in vitro study section, we showed an inhibitory concentration of MOLVX ON HRT-18, the value of IC₅₀ was 4.28 $\mu\text{g/mL}$, and the direct observation by inverted microscopy demonstrated that HRT-18 treated with MOLVX showed characteristic features of apoptosis including cell shrinkage, vascularization, and autophagy. Cell underwent early apoptosis during 72 h. Although, the mechanism of the action remained unclear, however, “based on our in vivo cytogenetic under publishing study results, which supports our point of view that corresponds

to a decrease in the S and G2/M phase populations. In addition, depending on the other proposed actions of levofloxacin and/or copper complex with other fluoroquinolones on the different cancer lines (70), we elucidated this mechanism based on pieces of evidence from the IHC assay, where we observed the anticancer effect of MOLVX treated groups. The positive control group that received AOM only showed overexpression of PCNA protein in neoplastic intestinal epithelial cells and aggregation of neoplastic cells within the villi. Intestinal epithelial cells of villi and crypts revealed normal Proliferating Cell Nuclear Antigen labeling (PCNA) expression in MOLVX-treated groups. Increased proliferative activity in AOM-injured mice's colon samples suggested an injury response. The crypt epithelial cells showed higher turnover, likely due to AOM's mitogenic action. MOLVX-treated AOM-injected animals demonstrated reduced mitotic activity, indicating cryoprotection. By examining histopathological characteristics and immunohistochemistry Proliferating Cell Nuclear Antigen labeling (PCNA) (figures 10. to 15.) supporting cytogenetic results including mitotic index from our previous cytogenetic result (activity) under publishing study, we showed a significant $p \leq 0.05$ decrease in mitotic activity in AOM-induced groups treated with MOLVX 2.5 mg/kg, and MOLVX 5 mg, Doxorubicin 16.2 mg/kg, and levofloxacin 25 mg/kg respectively in comparison to positive control. By examining and explaining Table 3. and the PCNA figures results from different experimental groups. The PCNA data represents the percentage of stained cells Proliferating Cell Nuclear Antigen labeling index levels (PCNA-LI) and staining intensity, which indicates the score. In descending order, groups (MOLVX 2.5 mg/kg BW), MOLVX 5 mg/kg BW, the Group treated with (doxorubicin 16.2 mg/kg BW), and the group treated with (levofloxacin 25 mg/kg BW) demonstrated a significant $P \leq 0.05$ decrease in the number of PCNA in comparison to the Control Positive. In this study, histopathological examination with H& E staining was also performed to confirm the presence of ACF in each slide before we took sections from formalin-fixed-paraffin embedded tissue blocks on positively charged slides. According to (71), ACF is analyzed based on the presence of dysplasia of various grades (mild, moderate, or severe), reduction in goblet cells, loss of differentiation, and elongation of the nuclei.

Finally, Proliferating Cell Nuclear Antigen (PCNA) plays an important role in colorectal neoplastic progression and can be used as an auxiliary marker for the risk of malignant transformation in colorectal adenomas, as it is highly correlated with high-grade dysplasia and increasing size. In conclusion, MOLVX may exhibit a significant and encouraging result in the reduction of cancer cells in mouse colon, but still, further studies in the other animal models

are recommended for a better understanding of its anti-cancer function.

ACKNOWLEDGMENTS

N/A.

CONFLICT OF INTEREST

The authors declare no conflict of interest.

REFERENCES

- Eisenach PA, Soeth E, Röder C, Klöppel G, Tepel J, Kalthoff H, et al. Dipeptidase 1 (DPEP1) is a marker for the transition from low-grade to high-grade intraepithelial neoplasia and an adverse prognostic factor in colorectal cancer. *Br J Cancer*. 2013;109(3):694–703.
- Harrison S, Benziger H. The molecular biology of colorectal carcinoma and its implications: a review. *Surg*. 2011;9(4):200–210.
- Issa JP. Colon cancer: it's CIN or CIMP. *Clin Cancer Res*. 2008;14(19):5939–5940.
- Worthley DL, Leggett BA. Colorectal cancer: molecular features and clinical opportunities. *Clin Biochem Rev*. 2010;31(2):31.
- Lai C, Li S, Liu C Bin, Miyauchi Y, Suzawa M, Ho C, et al. Effective suppression of azoxymethane-induced aberrant crypt foci formation in mice with citrus peel flavonoids. *Mol Nutr Food Res*. 2013;57(3):551–5.
- Yamashita Y, Ashizawa T, Morimoto M, Hosomi J, Nakano H. Antitumor quinolones with mammalian topoisomerase II-mediated DNA cleavage activity. *Cancer Res*. 1992;52(10):2818–22.
- Bobbarala V. A searches for antibacterial agents. *BoD-Books on Demand*; 2012.
- Zolopa AR, Berger DS, Lampiris H, Zhong L, Chuck SL, Enejosa JV, et al. Activity of elvitegravir, a once-daily integrase inhibitor, against resistant HIV type 1: results of phase 2, randomized, controlled, dose-ranging clinical trial. *J Infect Dis*. 2010;201(6):814–822.
- Ozdek SC, Miller D, Flynn PM, Flynn Jr HW. In vitro antifungal activity of the fourth generation, fluoroquinolones against *Candida* isolates from human ocular infections. *Ocul Immunol Inflamm*. 2006;14(6):347–51.
- Lancet JE, Ravandi F, Rickles RM, Cripe LD, Kantarjian HM, Giles FJ, et al. A phase Ib study of vosaroxin, an anticancer quinolone derivative, in patients with relapsed or refractory acute leukemia. *Leukemia*. 2011;25(12):1808–1814.
- Jamieson GC, Fox JA, Poi M, Strickland SA. Molecular and pharmacologic properties of the anticancer quinolone derivative vosaroxin: A new therapeutic agent for acute myeloid leukemia. *Drugs*. 2016;76(13):1245–1255.
- Abdel-Aal MAA, Abdel-Aziz SA, Shaykoon MSA, Abu-Rahma GEA. Towards anticancer fluoroquinolones: A review article. *Arch Pharm (Weinheim)*. 2019;352(7):1800376.
- Idowu T, Schweizer F. Ubiquitous nature of fluoroquinolones: the oscillation between antibacterial and anticancer activities. *Antibiotics*. 2017;6(4):26.
- Brambilla G, Mattioli F, Robbiano L, Martelli A. Studies on genotoxicity and carcinogenicity of antibacterial, antiviral, antimalarial and antifungal drugs. *Mutagenesis*. 2012;27(4):387–413.
- Peacock M, Brem R, Macpherson P, Karran P. DNA repair inhibition by UVA photoactivated fluoroquinolones and vemurafenib. *Nucleic Acids Res*. 2014;42(22):13714–22.
- Smart DJ, Lynch AM. Evaluating the genotoxicity of topoisomerase-targeted antibiotics. *Mutagenesis*. 2011;27(3):359–65.
- Hawtin RE, Stockett DE, Byl JA, McDowell RS, Tan N, Arkin MR, et al. Voreloxin is an anticancer quinolone derivative that intercalates DNA and poisons topoisomerase II. *Plos one*. 2010; 5(4):e10186.
- He X, Yao Q, Hall DD, Song Z, Fan D, You Y, et al. Levofloxacin exerts broad-spectrum anticancer activity via the regulation of THBS1, LAPTM5, SRD5A3, MFAP5, and P4HA1. *Anticancer Drugs*. 2022;33(1):e235-e246.

19. Barceló-Oliver M, García-Raso Á, Terrón Á, Molins E, Prieto MJ, Moreno V, et al. Ternary copper (II) complexes with hippurate derivatives and 1, 10-phenanthroline: Synthesis and biological activity. *Inorganica Chim Acta*. 2009;362(13):4744–4753.
20. Chen CY, Chen QZ, Wang XF, Liu MS, Chen YF. Synthesis, characterization, DNA binding properties, and biological activities of a mixed ligand copper (II) complex of ofloxacin. *Transit Met Chem*. 2009;34(7):757–763.
21. Sorenson JR, Wangila GW. Co-treatment with copper compounds dramatically decreases toxicities observed with cisplatin cancer therapy and the anticancer efficacy of some copper chelates supports the conclusion that copper chelate therapy may be markedly more effective and less toxic than cisplatin therapy. *Curr Med Chem*. 2007;14(14):1499–1503.
22. Penman ID, El-Omar E, McGregor JR, Hillan KJ, O'Dwyer PJ, McColl KE. Omeprazole inhibits colorectal carcinogenesis induced by azoxymethane in rats. *Gut*. 1993;34(11):1559–1565.
23. Sader HS, Huynh HK, Jones RN. Contemporary in vitro synergy rates for aztreonam combined with newer fluoroquinolones and β -lactams tested against gram-negative bacilli. *Diagn Microbiol Infect Dis*. 2003;47(3):547–550.
24. Tarab MK, Khaleel AMN, Al-Rekabi FMK. Schiff base method characterization of the newly synthesized Modified Levofloxacin Complex (MOLVX) and its activity against the HRT-18 cell line isolated from a male patient with colorectal adenocarcinoma. *Int J Health Sci (Qassim)* [Internet]. 2022 Sep 13;6(S7 SE-Peer Review Articles):3922–50. Available from: <https://sciencescholar.us/journal/index.php/ijhs/article/view/12689>
25. Freireich EJ, Gehan EA, Rall DP, Schmidt LH, Skipper HE. Quantitative comparison of toxicity of anticancer agents in mice, rats, hamsters, dogs, monkeys, and men. *Cancer Chemother Rep*. 1966;50(4):219–244.
26. Bird RP. Observation and quantification of aberrant crypts in the murine colon treated with a colon carcinogen: preliminary findings. *Cancer Lett*. 1987;37(2):147–151.
27. McLellan EA, Bird RP. Aberrant crypts: potential preneoplastic lesions in the murine colon. *Cancer Res*. 1988;48(21):6187–6192.
28. Pretlow TP, O'Riordan MA, Somich GA, Amini SB, Pretlow TG. Aberrant crypts correlate with tumor incidence in F344 rats treated with azoxymethane and phytate. *Carcinogenesis*. 1992;13(9):1509–1512.
29. Wang N, Li Y, Wei J, Pu J, Liu R, Yang Q, et al. TBX1 functions as a tumor suppressor in thyroid cancer by inhibiting the activities of the PI3K/AKT and MAPK/ERK pathways. *Thyroid*. 2019;29(3):378–394.
30. Yousef EM, Tahir MR, St-Pierre Y, Gaboury LA. MMP-9 expression varies according to molecular subtypes of breast cancer. *BMC Cancer*. 2014;14(1):609.
31. Roeland EJ, Bohlke K, Baracos VE, Bruera E, Del Fabbro E, Dixon S, et al. Management of cancer cachexia: ASCO guideline. *J Clin Oncol*. 2020; 38(21), 2438-2453.
32. Venning FA, Claesson MH, Kissow H. The carcinogenic agent azoxymethane (AOM) enhances early inflammation-induced colon crypt pathology. *J Cancer Sci Ther*. 2013;5(11):377–383.
33. Femia A Pietro, Dolara P, Caderni G. Mucin-depleted foci (MDF) in the colon of rats treated with azoxymethane (AOM) are useful biomarkers for colon carcinogenesis. *Carcinogenesis*. 2004;25(2):277–281.
34. Caderni G, Femia A Pietro, Giannini A, Favuzza A, Luceri C, Salvadori M, et al. Identification of mucin-depleted foci in the unsanctioned colon of azoxymethane-treated rats: correlation with carcinogenesis. *Cancer Res*. 2003;63(10):2388–2392.
35. Sørdring M, Gunnes G, Paulsen JE. Detection and characterization of flat aberrant crypt foci (flat ACF) in the novel a/J min/+ mouse. *Anticancer Res*. 2016a;36(6):2745–2750.
36. Kwong LN, Dove WF. APC and its modifiers in colon cancer. *Apc Proteins*. 2009;85–106.
37. Paulsen JE, Steffensen I-L, Løberg EM, Husøy T, Namork E, Alexander J. Qualitative and quantitative relationship between dysplastic aberrant crypt foci and tumorigenesis in the Min/+ mouse colon. *Cancer Res*. 2001;61(13):5010–5015.
38. Sørdring M, Gunnes G, Paulsen JE. Spontaneous initiation, promotion, and progression of colorectal cancer in the novel A/JM in/+ mouse. *Int J Cancer*. 2016b;138(8):1936–1946.
39. Nowak R, Olech M, Nowacka N. Plant Polyphenols as Chemopreventive Agents. In: Watson RR, Preedy VR, Zibadi S, editors. *Polyphenols in Human Health and Disease*. Academic Press; 2014. p. 1289-1307.
40. Song M, Wu H, Wu S, Ge T, Wang G, Zhou Y, et al. The antibiotic drug levofloxacin inhibits proliferation and induces apoptosis of lung cancer cells by inducing mitochondrial dysfunction and oxidative damage. *Biomed Pharmacother*. 2016;84:1137–1143.
41. Dalhoff A. Global fluoroquinolone resistance epidemiology and implications for clinical use. *Interdiscip Perspect Infect Dis*. 2012;2012.
42. Kalghatgi S, Spina CS, Costello JC, Liesa M, Morones-Ramirez JR, Slomovic S, et al. Bactericidal antibiotics induce mitochondrial dysfunction and oxidative damage in mammalian cells. *Sci Transl Med*. 2013;5(192):192ra85–192ra85.
43. Suresh N, Nagesh HN, Sekhar KVGK, Kumar A, Shirazi AN, Parang K. Synthesis of novel ciprofloxacin analogs and evaluation of their antiproliferative effect on human cancer cell lines. *Bioorg Med Chem Lett*. 2013;23(23):6292–6295.
44. Yu M, Li R, Zhang J. Repositioning of antibiotic levofloxacin as a mitochondrial biogenesis inhibitor to target breast cancer. *Biochem Biophys Res Commun*. 2016;471(4):639–645.
45. Elsea SH, Osheroff N, Nitiss JL. Cytotoxicity of quinolones toward eukaryotic cells. Identification of topoisomerase II as the primary cellular target for the quinolone CP-115,953 in yeast. *J Biol Chem*. 1992;267(19):13150–13153.
46. Melo S, Villanueva A, Moutinho C, Davalos V, Spizzo R, Ivan C, et al. Small molecule enoxacin is a cancer-specific growth inhibitor that acts by enhancing TAR RNA-binding protein 2-mediated microRNA processing. *Proc Natl Acad Sci*. 2011;108(11):4394–4399.
47. Gaur A, Jewell DA, Liang Y, Ridzon D, Moore JH, Chen C, et al. Characterization of microRNA expression levels and their biological correlates in human cancer cell lines. *Cancer Res*. 2007;67(6):2456–2468.
48. He L, Hannon GJ. MicroRNAs: small RNAs with a big role in gene regulation. *Nat Rev Genet*. 2004;5(7):522–531.
49. Lu J, Getz G, Miska EA, Alvarez-Saavedra E, Lamb J, Peck D, et al. MicroRNA expression profiles classify human cancers. *Nature*. 2005;435(7043):834–838.
50. Heinen CD, Shivapurkar N, Tang Z, Groden J, Alabaster O. Microsatellite instability in aberrant crypt foci from human colons. *Cancer Res*. 1996;56(23):5339–5341.
51. Anderson GR, Brenner BM, Swede H, Chen N, Henry WM, Conroy JM, et al. Intrachromosomal genomic instability in human sporadic colorectal cancer measured by genome-wide allelotyping and inter-simple sequence repeat) PCR. *Cancer Res*. 2001;61(22):8274–8283.
52. Luo L, Li B, Pretlow TP. DNA alterations in human aberrant crypt foci and colon cancers by random primed polymerase chain reaction. *Cancer Res*. 2003;63(19):6166–6169.
53. Bleiberg H, Morret M, Galand P. Correlation between [³H] thymidine and proliferation cell nuclear antigen (PCNA)/cyclin indices in archival, formaldehyde-fixed human colorectal tissues. *Eur J Cancer*. 1993;29(3):400–403.
54. Georgescu CV, Saftoiu A, Georgescu CC, Ciurea R, Ciurea T. Correlations of proliferation markers, p53 expression and histological findings in colorectal carcinoma. *J Gastrointest Liver Dis*. 2007;16(2):133.
55. Zhang J-C, Wang Z-R, Cheng Y-J, Yang D-Z, Shi J-S, Liang A-L, et al. Expression of proliferating cell nuclear antigen and CD44 variant exon 6 in primary tumors and corresponding lymph node metastases of colorectal carcinoma with Dukes' stage C or D. *World J Gastroenterol WJG*. 2003;9(7):1482.
56. Van Poznak C, Tan L, Panageas KS, Arroyo CD, Hudis C, Norton L, et al. Assessment of molecular markers of clinical sensitivity to single-

- agent taxane therapy for metastatic breast cancer. J Clin Oncol. 2002;20(9):2319-2326.
57. Wali RK, Roy HK, Kim YL, Liu Y, Koetsier JL, Kunte DP, et al. Increased microvascular blood content is an early event in colon carcinogenesis. Gut. 2005;54(5):654-60.
58. Qasim BJ, Ali HH, Hussein AG. Immunohistochemical expression of PCNA and CD34 in colorectal adenomas and carcinomas using specified automated cellular image analysis system: a clinicopathological study. Saudi J Gastroenterol. 2012;18(4):268.
59. Yan-Fang A, Yong M, Jing-Hua L. The expressions of PCNA and Bcl-2 in colorectal adenoma and carcinoma and their clinicopathological and prognostic significance. Acta Academiae Medicinae Xuzhou. 2006;6:11-17.
60. Zi-Jian T, Li D. The Expression of p53 and PCNA and their significance in colorectal neoplasm. J Basic Clin Oncol. 2001; 6:40-48.
61. AN Y, MENG Y, LU J. The expressions of PCNA and Bcl-2 in colorectal adenoma and carcinoma and their clinicopathological and prognostic significance. Acta Acad Med Xuzhou. 2006;
62. Kang G, Park CJ. Clinical Significance of PCNA and nm23 Expression in Invasive Colorectal Carcinoma. Journal of the Korean Society of Coloproctology. 2001;17(1):47-52.
63. Katada M, Sugiyama Y, Kunieda K, Saji S, Watanabe S, Watanabe K. Significance of cell proliferation and expression of mutant p53 protein for carcinogenesis of colorectal adenoma by immunohistochemical examination. Nippon Daicho Komonbyo Gakkai Zasshi. 1999;52(3):193-199.
64. Shpitz B, Bomstein Y, Mekori Y, Cohen R, Kaufman Z, Grankin M, et al. Proliferating cell nuclear antigen as a marker of cell kinetics in aberrant crypt foci, hyperplastic polyps, adenomas, and adenocarcinomas of the human colon. Am J Surg. 1997;174(4):425-430.
65. Bielicki D, Markiewski M, Wielondek M, Chosia M, Domagała W. PCNA defined proliferative activity of epithelial tumor cells in adenomas of the colon. Polish J Pathol Off J Polish Soc Pathol. 1995;46(3):151-154.
66. Yang H, Hsu P, Chan S, Lee J, Shin J, Chow N. Growth kinetics of colorectal adenoma-carcinoma sequence: an immunohistochemical study of proliferating cell nuclear antigen expression. Hum Pathol. 1996;27(10):1071-1076.
67. Seo KW, Holt R, Jung Y-S, Rodriguez Jr CO, Chen X, Rebhun RB. Fluoroquinolone-mediated inhibition of cell growth, S-G2/M cell cycle arrest, and apoptosis in canine osteosarcoma cell lines. 2012; PLOS ONE, 7(8), e42960.
68. Holtom PD, Pavkovic SA, Bravos PD, Patzakis MJ, Shepherd LE, Frenkel B. Inhibitory effects of the quinolone antibiotics trovafloxacin, ciprofloxacin, and levofloxacin on osteoblastic cells in vitro. J Orthop Res. 2000;18(5):721-727.
69. Miclau T, Edin ML, Lester GE, Lindsey RW, Dahners LE. Effect of ciprofloxacin on the proliferation of osteoblast-like MG-63 human osteosarcoma cells in vitro. J Orthop Res. 1998;16(4):509-512.
70. Suaifan GARY, Mohammed AAM, Alkhawaja BA. Fluoroquinolones' Biological activities against laboratory microbes and cancer cell lines. Molecules. 2022;27(5):1658.
71. Paulsen JE, Knutsen H, Ølstørn HB, Løberg EM, Alexander J. Identification of flat dysplastic aberrant crypt foci in the colon of azoxymethane-treated A/J mice. Int J cancer. 2006;118(3):540-546.

التجربة العلاجية لدواء الليفوفلوكساسين المعدل ضد بؤر القولون والمستقيم الشاذة المستحثة (الأنسجة محتملة التسرطن) في الفئران

محمد خليل تراب علي الهمداني¹، فلاح موسى كاظم الركابي²
 فرع الأدوية السريري، كلية الطب، جامعة كركوك، كركوك، العراق، فرع الفلسفة والكيمياء الحياتية والأدوية، كلية الطب البيطري،
 جامعة بغداد، بغداد، العراق

الخلاصة

السبب الثاني الأكثر شيوعاً للوفاة في جميع أنحاء العالم وثالث أكثر أنواع السرطان انتشاراً هو سرطان القولون والمستقيم. يعرف الليفوفلوكساسين ومعظم الفلوروكينولونات بالمضادات الحيوية المعدنية بسبب تقاربها العالي للارتباط بالمعادن مثل النحاس لتوسيع طيفها وزيادة التقارب مع الخلايا السرطانية للحمض النووي لمنع معدل انتشار الخلايا السرطانية. تم إعداد الليفوفلوكساسين المعدل (MOLVX) الذي تم استخدامه في هذه الدراسة بواسطة تجربتنا السابقة. كان الهدف من هذه الدراسة هو الكشف عن التأثير العلاجي المحتمل لـ MOLVX على الأنسجة محتملة التسرطن القولون والمستقيم (بؤر السرداب الشاذة). شاركت ستون أنثى من الفئران Balb-C، مقسمة بالتساوي إلى ست مجموعات (G1 و G2 و G3 و G4 و G5 and G6). تركت المجموعة الضابطة G1 دون أي تدخلات؛ تلقت الفئران من المجموعات المتبقية أزوكسي ميثان (AOM) لتحريض ACF القولون والمستقيم، 10 AOM ملغم / كغم من وزن الجسم مرتين بواقع جرعة واحدة أسبوعياً؛ المجموعة الثانية G2 تركت دون أي علاج وتعتبر مجموعة تحكم إيجابية مع الدواء الوهمي، المجموعة الثالثة G3 عالجت داخل الصفاق مع 16,2 ملغ / كغم من وزن الجسم دوكسوروبيسين عن طريق إعطاء جرعة واحدة أسبوعياً لمدة أربعة أسابيع، تم إعطاء G4 عن طريق الفم جرعة واحدة يومية من ليفوفلوكساسين 20 ملغم / كغم من وزن الجسم لمدة شهر. أعطيت كلتا المجموعتين 5 و 6 عن طريق الفم جرعة واحدة يومية من 5 و 2.5 MOLVX و 20 ملغم / كغم من وزن الجسم لمدة شهر. خلال الفحص النسيجي المرضي لبؤر السرداب الشاذة المصبوغة بصيغة الهيماتوكسيلين والإيوسين. أظهرت النتائج انخفاضاً معنوياً ($p < 0.05$) لعدد ACF في المجموعات المعالجة مع 2.5 MOLVX مجم / كجم، doxorubicin، 5 mg / kg، و levofloxacin بالمقارنة مع السيطرة الإيجابية. بالإضافة إلى ذلك، أظهرت المجموعتان G5 و G6 انخفاضاً كبيراً ($p < 0.05$) في النسبة المنوية للمستضد الخلوي المنتشر (PCNA). في الختام: أظهر كل من 20 mg / kg و 5 mg / kg من جرعة MOLVX تأثيراً علاجياً محتملاً ضد الأنسجة السابقة للتسرطن في قولون الفأر. ومع ذلك، فإن جرعة 5 mg / kg كان BW أكثر فعالية من 20 mg / Kg.BW. لمعالجة الأنسجة السابقة للتسرطن.

الكلمات المفتاحية: مولفكس، الليفوفلوكساسين، بؤر القولون، التسرطن، الفئران