



Resveratrol Administration Ameliorates Hepatotoxicity in Mercuric Chloride-Induced Liver Injury in Rats

Rusul A Dawood¹ , Hasan F Alghetaa^{*1} , Ahmed K Aladhami²

¹Department of Physiology, Biochemistry and Pharmacology, College of Veterinary Medicine, University of Baghdad, Baghdad, Iraq, ²Department of Pathology, Microbiology and Immunology, School of Medicine, University of South Carolina, Columbia, South Carolina, USA

A B S T R A C T

Mercuric chloride (HgCl₂) pollution and poisoning has been a worldwide health concern for decades, especially after the industrial revolutions. The aim of this study was to investigate the role of resveratrol in reversing the deleterious effects of HgCl₂ exposure to resume the normal functions of hepatocyte. To achieve the study, mature Sprague Dawley rats were assigned to five groups. Negative control group (C) kept without any treatment; vehicle-treated group (D) received dimethyl sulfoxide (DMSO); resveratrol-treated group (R), received 100 mg/kg of resveratrol; HgCl₂-intoxicated group (HD), received i.p. injection of HgCl₂ at a dose of 1 mg/kg for 30 consecutive days along to oral gavage of DMSO; and finally HgCl₂-intoxicated group treated with resveratrol (HR) as same treatment strategy of R-group. At the endpoint of the experiment, blood samples were collected for biochemical liver function tests along with serum concentrations of malondialdehyde (MDA), glutathione (GSH), body weight, as well as histopathological investigation was done too. Study results revealed a significant ($P<0.05$) elevation in serum AST, ALP, GGT, and MDA in HD group in comparison with HR group. However, resveratrol treatment has led to a significant ($P<0.05$) increase in serum levels of GSH in HR group in comparison with the HD group. Histopathological sections showed vacuolar degeneration in HD hepatocytes while resveratrol treatment protected the hepatocytes against the chemical injury. Altogether, It is concluded that resveratrol administration has the ability to increase the resistance of liver against the HgCl₂-induced hepatotoxicity via increase the antioxidant yields such as GSH resulted in reduction of hepatocellular texture damage.

Keywords: resveratrol, HgCl₂-toxicity, GGT, oxidative stress, ROS

*Correspondence:

Kashifalkitaa@covm.uobaghdad.edu.iq

Received: 12 June 2023

Revised: 22 June 2023

Accepted: 16 July 2023

Published: 28 December 2023

DOI:

<https://doi.org/10.30539/ijvm.v47i2.1482>



This article is an open access distributed under the terms and conditions of the Creative Commons Attribution License (CC BY 4.0)

Cite:

Dawood RA, Alghetaa HFK, Aladhami AK.
Resveratrol administration ameliorates
hepatotoxicity in mercuric chloride-induced liver
injury in rats. Iraqi J. Vet. Med. 2023;47(2):1-8.

INTRODUCTION

Chemical poisoning is one of the recent era health problems due to exponentially progress of industrial revolution and many heavy metals are introduced to manufacture different daily demanded materials led to poor quality of air as well as water (1). Mercury (Hg) is a harmful heavy metal to human health. Inorganic Hg (Hg⁺⁺) is produced through the combustion of

fossil fuels, the exploration of mines, and industrial application. Numerous studies have shown that Hg is hazardous to a variety of organs, including the brain system and immune system (2), mercury poisoning can happen by eating, inhalation, or skin absorption. It can also infiltrate red blood cells or plasma. Mercury is mostly metabolized in the liver, where it can build up and cause severe hepatic damage (3). Mercury and its products contain a wide range of contaminants. The aquatic environment causes

destruction effects on aquatic animals. Many common forms of mercury in ecosystems. This is "elemental mercury", an organic substance such as ethyl, methylmercury, and inorganics (4, 5).

The liver is a vital organ that is engaged in numerous metabolic processes and a frequent target for several toxicants. The liver has been linked to the accumulation and excretion of mercury. One of the primary processes implicated in hepatotoxins-induced liver damage is oxidative stress, which is constantly increased by a combination of reactive oxygen species (ROS) overproduction and endogenous antioxidant capacity decrease (6).

Resveratrol, which is present in some plants, fruits, and derivatives like red wine, has a variety of health benefits, which it may be because of the way it is structured (7). It functions as an antioxidant activity by scavenging free radicals and chelating metal ions, which reduces or stops lipid oxidation (LPO) through altering many cellular antioxidant pathways. As an antioxidant, anti-platelet, anti-inflammatory, cytoprotective, neuroprotective, anti-hyperlipidemic, anti-carcinogenic, cardioprotective, immunomodulatory, vasorelaxant, and antidiabetic, resveratrol has attracted increasing attention (8). Resveratrol has been well-documented as anti-inflammatory (9), anti-asthmatic (10), inhibitor of early parasitemia in dogs (11), anti-oxidant (12), anticancer (7) and so many other biological properties. This study aimed to investigate how natural antioxidants, such as resveratrol, can ameliorate the severity of liver injury exposed to mercuric chloride.

MATERIALS AND METHODS

Ethical Approval

Before performing any experiment, the experimental design and protocols used in current study were examined and approved by the Ethics Committee of the College of Veterinary Medicine, University of Baghdad, Baghdad, Iraq under Animal Utilization Protocol Certificate P.G. 1293.

Experimental Animals

Forty-five of 8-10-week-old female Sprague Dawley rats weighed between 170-220 g were obtained from the animal house of the College of Veterinary Medicine, University of Baghdad. All rats were housed in specific room belong to the Department of Physiology, Biochemistry and Pharmacology, College of Veterinary Medicine, University of Baghdad. The rats were accommodated in plastic cages (20×30×50 cm³) with stainless-steel wire mesh lids and were allowed a two-week adaptation period prior to the commencement of the experiment. Food and drink were freely accessible, in addition, the dark/light cycle were approximately equal all the experiment periods.

Experimental Design

The animals were randomly allocated into five groups, each undergoing a distinct treatment regimen. The Negative Control Group (C) served as the baseline, where rats were kept without any medication, ensuring a standard reference for comparison. In contrast, the Vehicle Group (D) involved rats receiving an oral administration of dimethyl sulfoxide (DMSO) for 30 consecutive days, prepared at the same diluted rate as the resveratrol discussed in the subsequent section. The Resveratrol (R)-Treated Group was provided with an oral resveratrol supplement at a dose of 100 mg/kg daily, continuing this treatment for 30 days, as informed by methodologies outlined in references 9, 13, and 14. The Challenged Group (HD) differed in its approach, with rats receiving daily intraperitoneal injections of mercuric chloride (HgCl₂) at a dose of 1 mg/kg, coupled with oral DMSO administration, spanning a 30-day period, following protocols detailed in studies 15 and 16. Finally, the Challenged/Treated Rats (HR) experienced a combined treatment, receiving both HgCl₂ and resveratrol (HgCl₂ + RES) in the same regimen as defined for the R and HD groups.

Preparation of Resveratrol (RES)

Supplement capsules of 200 mg trans-resveratrol (Now, USA) was used in order to prepare homogenous solution, contents of two supplement capsules which were mixed rigorously with 500 µL of DMSO and once the solution became homogenized, 3500 µL of distilled water was added to achieve 100 mg/mL resulted then the RES-treated animals were administered 0.1 mL per each 100 g body weight (100 mg/kg BW).

Preparation of HgCl₂ Solution

The following method is used to create HgCl₂ solution. Ten mg of mercury chloride was dissolved in distilled water up to 10 ml, and the final concentration was 1 mg/mL. Thus, every 10 g of body weight of rats received 0.1 mL of the HgCl₂ solution.

Blood Samples

At the endpoint of the experiment, all animals were anesthetized deeply with an overdose of 4 mg/kg of xylazine and 150 mg/kg of ketamine mixture (17). Blood samples were obtained by using capillary pipettes to rupture the retro-orbital plexus vein to collect the dripping blood in a gel-enhancing blood clot tubes at the endpoint of the experiments.

Perfusion the Organs

In order to obtain clear histopathological images, the blood was perfused to avoid it from the extravasation into internal organs during the euthanasia process. Briefly, once the animal being under deep anesthesia, the ribcage was opened up and the right atrium was cut then heparinized

PBS was perfused through the heart ventricle to wash out the blood before collecting the target tissues for histopathology investigation.

Liver Collection

The liver was excised and weighed accurately by using sensitive electronic balance. The liver was preserved in formalin for histology after being weighed.

Studied Parameters

Liver function tests were evaluated following previous study (19) by using liver enzyme kits.

Aspartate transaminase (AST), Alanine transaminase (ALT) and Alkaline phosphatase (ALP) kits (Abbott, USA). Briefly, AST present in the sample catalyzes the transfer of the amino group from L-aspartate to 2-oxoglutarate, in the presence of pyridoxal-5'-phosphate, forming oxaloacetate and L-glutamate. ALT presents in the sample catalyzes the transfer of the amino group from L-alanine to 2-oxoglutarate, in the presence of pyridoxal-5'-phosphate, forming pyruvate and L-glutamate. Pyruvate in the presence of NADH and lactate dehydrogenase (LD) is reduced to L-lactate. The Activated the AST and ALT reagent is based on the optimized formulation as recommended by the International Federation of Clinical Chemistry (IFCC). Moreover, ALP in the sample catalyzes the hydrolysis of colorless p-nitrophenyl phosphate (p-NPP) to give p-nitrophenol and inorganic phosphate. In term to prepare serum samples for analysis, 0.85% to 0.90% NaCl saline was used to dilute the samples by using the Architect Systems auto dilution following to the manufacturer recommendations.

Gamma-Glutamyl Transferase (GGT) assay

GGT kit (MyBioSource, Canada) is an Enzyme-Linked Immunosorbent Assay (ELISA). All reagents, samples and standards, were prepared at room temperature, then 40 μ L of biological samples were used then mixed with 10 μ L of anti-GGT antibody in the sample wells. Later, 50 μ L of streptavidin-HRP added to sample wells and standard wells. Then the plate was covered with a sealer. Incubated for 60 minutes at 37 °C. Between each step, the plate was washed 4-5 times. Substrate solution A and B were added. Incubated for 10 min at 37 °C and then added stop solution and color was developed. The OD value was read within 10 min (19, 21).

Antioxidant status was evaluated in serum by measuring the Glutathione (GSH) assay: This experiment utilized a rat-specific kit (MyBiosource, Canada) of double-sandwich ELISA technique to measure the serum levels of GSH. All reagents, samples and standards were prepared and incubated at 37 °C for 90 min with shaking, then washed the plate, added the biotinylated antibody working solution, incubated at 37 ° for 60 min then washed three times before adding the enzyme working solution, and then added the color reagent solution, incubated at 37° for 30

minutes. At the end, OD values were recorded within 10 minutes after stop solution being added.

Malondialdehyde (MDA) assay: This experiment used double-sandwich ELISA technique and the ELISA Kit (MyBiosource, Canada). The pre-coated antibody is the human MDA monoclonal antibody, and the detecting antibody is polyclonal antibody with biotin labeled. Samples and biotin labeling antibody were added into ELISA plate wells and washed out with TBS. Then Avidin-peroxidase conjugates were added to ELISA wells in order; Use TMB substrate for coloring after reactant thoroughly washed out by PBS or TBS. TMB turns into blue in peroxidase catalytic and finally turns into yellow under the action of acid. The color depth and the testing factors in samples were positively correlated. 450 nm detection wavelength filter, 570 nm or 630 nm correction wavelength filters.

Body weight was measured weekly from the beginning of the study till the end of the experiment.

Histopathology exam was applied to collected liver specimens by using hematoxylin and eosin staining techniques.

Statistical Analysis

Collected data were statistically analyzed by using GraphPad Prism 8 software (GraphPad Inc., USA). Five rats per group were used as determined by power analysis unless stated differently. Average value \pm standar error mean (SEM) was represented in every parameter value. When there was comparison between two experimental groups, the students t-test was used to calculate the statistical differences post Holm-Sidak correction for multiple comparisons. While statistical comparison was achieved among three or more of experimental groups, the One-way ANOVA and Tukey's multiple comparisons post-hoc test was performed. Two-way ANOVA test was performed to calculate the two factorial effects of time and treatment strategy on the body weight of experimental animals. A P-value less than 0.05 was considered significant difference for all experiments and depicted as follows, *P<0.05, **P<0.01, ***P<0.001 and #P<0.0001, or different alphabet letters were used too to denote the statistical differences among the groups in table-based data visualization.

RESULTS

Ameliorative effects of resveratrol treatment on the liver function

Current study results revealed significant (P<0.05) increase in the serum levels of AST enzyme in comparison to all other study groups (Figure 1A). GGT, concentrations were significantly (P<0.05) higher in HD group in comparison with the HR group (Figure 1B). Moreover, resveratrol treatment to R-group led to significant (P<0.05) reduction in ALP concentration in comparison to the HD

group (Figure 1C), but ALP enzyme levels were not changed among the other groups. In other hand, the mercuric chloride toxicity did not change the ALT in comparison with the other groups (Figure 1D). Interestingly, neither administration of DMSO nor resveratrol to healthy rats caused significant changes in AST, ALP or ALT levels in comparison to the control group (Figure 1A, C, and D).

Redox system rebalanced by administration of resveratrol to the rats exposed to HgCl₂-mediated hepatotoxicity

Administration of resveratrol has improved the balance between the concentration of oxidant agent represented by

malondialdehyde (MDA) concentration in study groups and enhanced the antioxidants production in other side. Study results showed that there was a significant increase ($P<0.05$) in MDA concentrations in HD group in comparison with all other study groups (Figure 2A). Interestingly, the administration of resveratrol to the HgCl₂-intoxicated group (HR) led to significant increase ($P<0.05$) of total glutathione level in comparison with HD group (Figure 2B). Furthermore, treating healthy rats with DMSO or resveratrol did not cause any oxidative stress concluded via concentrations of MDA levels.

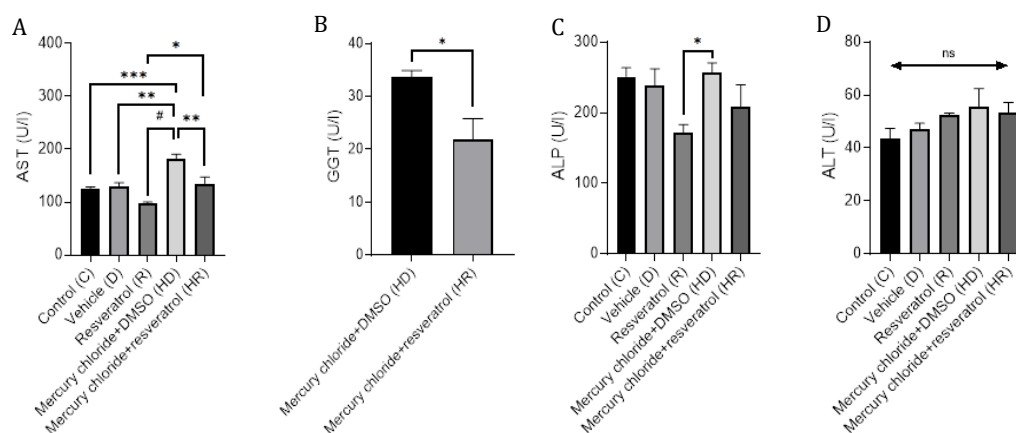


Figure 1. Evaluation of liver function via some serum biochemical tests in experimental rats post HgCl₂ exposure. **(A)** Aspartate transaminase (AST). **(B)** Gamma-glutamyl transferase (GGT). **(C)** Alkaline phosphatase (ALP). **(D)** Alanine transaminase (ALT). (n=5). * $P<0.05$, ** $P<0.01$, *** $P<0.001$, # $P<0.0001$; ns=non-significant

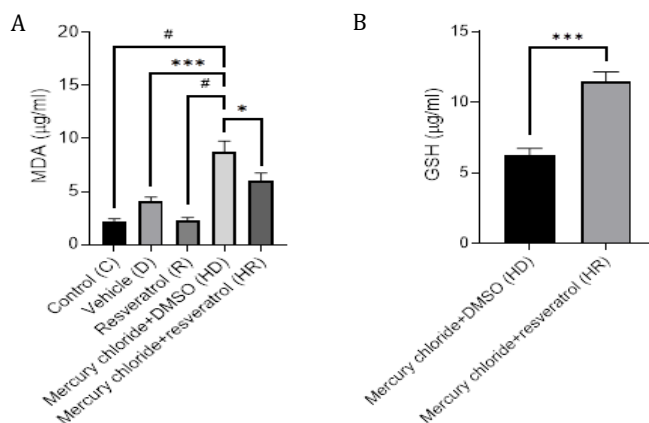


Figure 2. Evaluation of redox system post exposure to HgCl₂ intoxication in experimental rats. **(A)** Malondialdehyde (MDA) concentration. **(B)** Glutathione (GSH) concentration. (n=5); * $P<0.05$, ** $P<0.01$, *** $P<0.001$, # $P<0.0001$.

Ameliorative effects of resveratrol treatment on the biomass of the chemical-injured rats

Weekly monitoring of the body weight changes had revealed that chemical injury by mercuric chloride led to significant ($P<0.05$) decline in the body mass in HD group

after three weeks in comparison to beginning of the experiment (Table 1). Furthermore, administration of resveratrol to HgCl_2 -injured rats (HR) led to significant ($P<0.05$) increase in body weight of this group when compared the initial and terminal weights four weeks post HgCl_2 poisoning (Table 1).

Table 1. Effect of different treatments and experimental timeline on the body weight deviation percentages (%) normalized to the initial weight at Day-0

Day	Control (C)	Vehicle (DMSO)	Resveratrol	HgCl_2 + DMSO	HgCl_2 + Resveratrol
0	100±7.80 ^{Ba}	100±7.90 ^{Aa}	100±6.70 ^{Ba}	100±8.40 ^{Aa}	100±2.80 ^{Aa}
7	105±5.80 ^{ABa}	102±4.90 ^{Aa}	104±4.10 ^{ABa}	95.8±2.30 ^{Aa}	104±1.50 ^{Aa}
14	109±5.20 ^{ABa}	110±3.30 ^{Aa}	107±4.40 ^{ABa}	97.6±2.60 ^{Aa}	108±1.90 ^{Aa}
21	116±2.50 ^{ABa}	110±2.70 ^{Aab}	113±3.70 ^{ABab}	98.6±2.70 ^{Ab}	110±2.20 ^{Aab}
28	120±1.70 ^{Aa}	111±3.90 ^{Aab}	119±3.60 ^{Aa}	99.2±2.50 ^{Ab}	111±2.10 ^{Aab}

Mean±SEM, n=5. ^{A-B}Uppercase superscripts denote significant differences among different time points within the same treatment group. ^{a-b}Lowercase superscripts indicate significant differences among treatment groups at the same time point. Two-way ANOVA test was used for statistical analysis. DMSO, Dimethyl sulfoxide

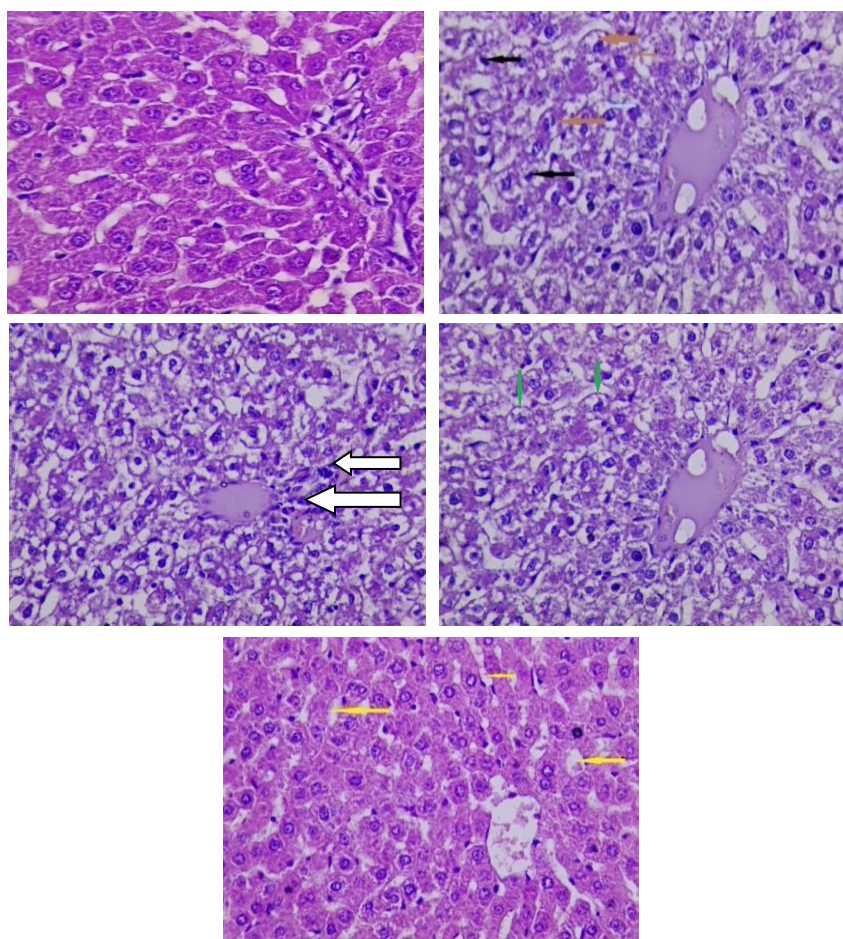


Figure 3. Histopathological sections of liver tissues following a 30-day period (H&E stain, 40×). **(A)** Control group (C) shows no pathological lesions. **(B)** HgCl_2 + DMSO (HD) group shows degenerative changes (red arrows) and rare apoptotic or necrotic cells (black arrow) of hepatocytes. **(C)** HgCl_2 + DMSO (HD) group following 30 days period shows infiltration of inflammatory cells (white arrows). **(D)** HgCl_2 -intoxicated (HD) group shows vacuolar degeneration (green arrows). **(E)** HgCl_2 + Resveratrol (HR) group shows normal histological structure with mild dilatation in sinusoids (yellow arrows)

Resveratrol administration protected the hepatic tissue and enhanced the repair of oxidative stress-mediated damaged liver parenchyma

Microsection of control liver did not show any pathological lesions except mild sinusoid dilatation (Figure 3A). Exposing rats to mercuric chloride contamination for 30 days was enough to cause deleterious effects on the hepatic tissue represented by degenerative features such as increase apoptotic cells (Figure 3B) and profound of infiltrating inflammatory cells (Figure 3C) and vacuolar degeneration of the hepatocytes (Figure 3D). Supplementing animals with resveratrol led to protect the hepatic tissue against the toxic effects of HgCl₂ poisoning to look like normal tissue at the end of the experiment with mild sinusoid dilatation (Figure 3E).

DISCUSSION

The clinical biochemical parameters ALT, AST, and ALP are thought to be helpful in determining liver toxicity. In Figure 1A, the concentration of serum AST in HD group is higher than other groups. The current study showed an increase in AST concentration that was consistent with other values, the interpretation is the outcome of tissue damage due to hepatocellular necrosis (22). The concentration of serum ALT did not significantly change in the study groups. However, Figure 1C showed increase of serum ALP in HD group, such a shift in liver enzyme activity may also be accompanied by a change in the balance of oxidants and antioxidants (Figure 2). Important indicators as biomarkers of liver dysfunction in clinical observations are an acute intoxication-induced hepatocellular injury and an increase in serum ALT, AST, and ALP activities. These findings are confirmed by earlier research. (23). Figure 1A shows significant increase of AST in HD group that could explain the increase of apoptosis or necrosis in hepatocytes (24). Furthermore, significant elevation of GGT levels in HD groups (Figure 1B) could also be helpful indicator for presence of oxidative stress, (25) through the metabolism of GSH which in turn plays important role of redox homeostasis (26) as shown in Figure 2A, B. These changes collectively could explain the histopathological findings of our study highlighting the exacerbation of necrosis or apoptosis rate as well as infiltrating of immunocytes to the hepatic parenchyma (27, 28). Immunological response against the mercury exposure could be pleomorphic forms depending on the animal species and its sensitivity (29). However, immunotoxicity is one of the expected outputs generated by immune system against exposure to mercuric chloride intoxication may lead to multiple organs dysfunction (29).

Exposure to mercury chloride toxicity led to an increase in the oxidative stress that in turn enhanced the MDA production (Figure 2A) and reduction in production of GSH (Figure 2B), these results came in consistence with results of previous research who found that exposure to mercury

chloride results in increase the MDA along with reduction in GSH concentrations in mice (30) and elevation of MDA levels in rats (16). GSH plays specific functions in defending the body against mercury toxicity. Mercury attaches to GSH, forming a complex that stops mercury from attaching to cellular proteins and harming enzymes and tissue. Mercury binds to GSH, and the removal of intracellular GSH as a consequence lowers the levels of GSH in the cell and lowers the antioxidant capacity of the cell (26, 31-33).

In Table 1, we can notice in group HD significantly decrease weight in HD group that exposed to HgCl₂ intoxication in comparison with the control group, this could be due to alterations in metabolism rate and neuropathic complications that derive loss of appetite (34) and agree with the findings of (16). In addition, we noticed a gradual increase in the weight of the rat in group HD in the fourth week of the experiment. This increase in weight seen in our study could be resulted from body's adaptive response to systemic toxicity being minimized (35, 36) and this also was declared by other researcher who found that the immunological response to mercury toxicity is varied according to the animal species and strain, particularly that the rats are more tolerant to mercury toxicants than mice or even Brown rats (29). Or it could be due to increase the status of oxidative stress (Figure 2A) which is also may lead to disturbance in the animal development ends with an increase in the body mass index (37). In other hand, treatment of resveratrol to HgCl₂-intoxicated rats (HR group) has reversed most of deleterious markers, AST (Figure 1A), GGT (Figure 1B), MDA (Figure 2A) which reflected on the liver tissue soundness (Figure 3E) and the body weight gaining (Table 1). These positive effects of resveratrol might be due to its chemical nature as polyphenolic antioxidant and other properties (7-11).

Current study results of resveratrol are streamed with other studies who have found that administration of resveratrol led to ameliorative effects during exposure to different metal intoxication (38), such as cadmium (39, 40), aluminum (41). Collectively, it can conclude that chemical poisoning such as in mercuric chloride contamination is a health concern that leads to liver injury even in small traces. While the resveratrol has the potent ability to ameliorate oxidative stress status through its well-known antioxidant and anti-inflammatory and could be used as protective supplement during the exposure to mercuric contaminants through mentioned properties and repair or at least prevent the parenchymal damage of hepatic tissue especially to workers who deal with mercury composed products.

ACKNOWLEDGEMENTS

N/A

CONFLICT OF INTEREST

The authors declare no conflict of interest.

REFERENCES

- Ouda YW, Kadhim KF, Amer AM. Study of some toxic metals in parts from catfish (*Silurus triostegus*) in Shatt Al-Arab river. *Iraqi J Vet Sci*. 2023;37(2):459-567. [10.33899/ijvs.2022.135004.2435](#)
- Yang Z, Zhao Y, Li Q, Shao Y, Yu X, Cong W, et al. Developmental exposure to mercury chloride impairs social behavior in male offspring dependent on genetic background and maternal autoimmune environment. *Toxicol Appl Pharmacol*. 2019;370:1-13. Available from [10.1016/j.taap.2019.03.006](#)
- Wadaan MAM. Effects of Mercury Exposure on Blood Chemistry and Liver Histopathology of Male Rats. *J Pharmacol Toxicol*. 2009;4(3):126-131. [10.3923/jpt.2009.126.131](#)
- Alrudainy AJ. Toxic effects of mercuric chloride on DNA damage, hematological parameters and histopathological changes in common (carp *Cyprinus carpio*). *Iraqi J Vet Med*. 2014;38(2):87-94. [10.30539/iraqijvm.v38i2.228](#)
- Mustafa SA, Al-Rudainy AJ. Impact of Mercury Chloride Exposure on Some of Immunological and Biochemical Assays of Common Carp, *Cyprinus Carpio*. *Iraqi J Agric Sci*. 2021;52(3):547-551. [10.36103/ijas.v52i3.1341](#)
- Liu W, Xu Z, Li H, Guo M, Yang T, Feng S, et al. Protective effects of curcumin against mercury-induced hepatic injuries in rats, involvement of oxidative stress antagonism, and Nrf2-ARE pathway activation. *Hum Exp Toxicol*. 2016;36(9):949-966. [10.1177/0960327116677355](#)
- Khayoon HA, Al-Rekabi FMK. Cytotoxic Effect of Resveratrol on Colorectal Cancer Cell Line. *Iraqi J Vet Med*. 2020;44(1):68-74. [10.30539/ijvm.v44i1.939](#)
- Glorigorijević N, Stanić-Vučinić D, Radomirović M, Stojadinović M, Khulal U, Nedić O, et al. Role of resveratrol in prevention and control of cardiovascular disorders and cardiovascular complications related to COVID-19 disease: mode of action and approaches explored to increase its bioavailability. *Molecules*. 2021;26(10):2834. [10.3390/molecules26102834](#)
- Alghetaa H, Mohammed A, Singh N, Wilson K, Cai G, Putluri N, et al. Resveratrol attenuates staphylococcal enterotoxin B-activated immune cell metabolism via upregulation of miR-100 and suppression of mTOR signaling pathway. *Front Pharmacol*. 2023;14:1106733. [10.3389/fphar.2023.1106733](#)
- Alharris E, Mohammed A, Alghetaa H, Zhou J, Nagarkatti M, Nagarkatti P. The ability of resveratrol to attenuate ovalbumin-mediated allergic asthma is associated with changes in microbiota involving the gut-lung axis, enhanced barrier function and decreased inflammation in the lungs. *Front Immunol*. 2022;13:805770. [10.3389/fimmu.2022.805770](#)
- Ukwueze C, Akpa P, Odo R, Aronu C, Anene B. The beneficial effects of resveratrol supplementation on parasitemia, oxidative stress and serum biochemical parameters in *Trypanosoma brucei* infected dogs. *Iraqi J Vet Sci*. 2022;36(3):753-760. [10.33899/ijvs.2022.131843.2009](#)
- Abdulla JM, Al-Okaily BN. Histomorphometric and histopathological alterations of rat testis following exposure to hydrogen peroxide: protective role of resveratrol supplement. *Iraqi J Vet Med*. 2022;46(1):17-23. [10.30539/ijvm.v46i1.1313](#)
- Alghetaa H, Mohammed A, Sultan M, Busbee P, Murphy A, Chatterjee S, et al. Resveratrol protects mice against SEB-induced acute lung injury and mortality by miR-193a modulation that targets TGF- β signalling. *J Cell Mol Med*. 2018;22(5):2644-2655. [10.1111/jcmm.13542](#)
- Alghetaa H, Mohammed A, Zhou J, Singh N, Nagarkatti M, Nagarkatti P. Resveratrol-mediated attenuation of superantigen-driven acute respiratory distress syndrome is mediated by microbiota in the lungs and gut. *Pharmacol Res*. 2021;167:105548. [10.1016/j.phrs.2021.105548](#)
- Said ES, Ahmed RM, Mohammed RA, Morsi EM, Elmahdi MH, Elsayed HS, et al. Ameliorating effect of melatonin on mercuric chloride-induced neurotoxicity in rats. *Helvion*. 2021;7(7): e07485. [10.1016/j.heliyon.2021.e07485](#)
- Shalan MG. Amelioration of mercuric chloride-induced physiologic and histopathologic alterations in rats using vitamin E and zinc chloride supplement. *Heliyon*. 2022;8(12):e12036. [10.1016/j.heliyon.2022.e12036](#)
- Sotoudeh N, Namavar MR. Optimisation of ketamine-xylazine anaesthetic dose and its association with changes in the dendritic spine of CA1 hippocampus in the young and old male and female Wistar rats. *Vet Med Sci*. 2022;8(6):2545-2552. [10.1002/vms3.936](#)
- Mohammed A, Alghetaa HK, Zhou J, Chatterjee S, Nagarkatti P, Nagarkatti M. Protective effects of Δ^9 -tetrahydrocannabinol against enterotoxin-induced acute respiratory distress syndrome are mediated by modulation of microbiota. *Br J Pharmacol*. 2020;177(22):5078-5095. [10.1111/bph.15226](#)
- Ahmed RM, Mohammed AK. Role of sodium butyrate supplement on reducing hepatotoxicity induced by lead acetate in rats. *Iraqi J Vet Med*. 2022;46(2):29-35. [10.30539/ijvm.v46i2.1408](#)
- Ahmed RM, Mohammed AK. Amelioration of hepatotoxicity by sodium butyrate administration in rats. *World's Vet J*. 2022:323-329. [10.54203/scil.2022.vwj41](#)
- Al-Rikabi FMK. Evaluation of selected parameters of rat liver injury following repeated administration of oseltamivir for different periods. *Iraqi J Vet Med*. 2012;36(1):145-156. [10.30539/iraqijvm.v36i1.559](#)
- Prasanna PL, Renu K, Valsala Gopalakrishnan A. New molecular and biochemical insights of doxorubicin-induced hepatotoxicity. *Life Sci*. 2020;250:117599. [10.1016/j.lfs.2020.117599](#)
- Alhusaini A, Alghilani S, Alhuqbani W, Hasan IH. Vitamin E and Lactobacillus Provide Protective Effects Against Liver Injury Induced by HgCl₂: Role of CHOP, GPR87, and mTOR Proteins. Dose-Response. 2021;19(2):15593258211011360. [10.1177/15593258211011360](#)
- Shojaie L, Iorga A, Dara L. Cell Death in Liver Diseases: A Review. *Int J Mol Sci*. 2020;21(24):9682. [10.3390/ijms21249682](#)
- Xing M, Gao M, Li J, Han P, Mei L, Zhao L. Characteristics of peripheral blood Gamma-glutamyl transferase in different liver diseases. *Medicine*. 2022;101(1):e28443. [10.1097/MD.00000000000028443](#)
- Zhang H, Forman HJ. Redox Regulation of γ -Glutamyl Transpeptidase. *Am J Respir Cell Mol Biol*. 2009;41(5):509-515. [10.1165/rcmb.2009-0169TR](#)
- Satué K, Miguel-Pastor L, Chicharro D, Gardón JC. Hepatic Enzyme Profile in Horses. *Animals*. 2022;12(7):861. [10.3390/ani12070861](#)
- Zhang J, Yang Y, Gong JY, Li LT, Li JQ, Zhang MH, et al. Low-GGT intrahepatic cholestasis associated with biallelic USP53 variants: Clinical, histological and ultrastructural characterization. *Liver Int*. 2020;40(5):1142-1150. [10.1111/liv.14422](#)
- Schwenk M, Klein R, Templeton DM. Immunological effects of mercury (IUPAC Technical Report). *Pure Appl Chem*. 2009;81(1):153-167. [10.1351/PAC-REP-08-04-02](#)
- Zhao Y, Zhou C, Guo X, Hu G, Li G, Zhuang Y, et al. Exposed to Mercury-Induced Oxidative Stress, Changes of Intestinal Microflora, and Association between them in Mice. *Biol Trace Elem Res*. 2020;199(5):1900-1907. [10.1007/s12011-020-02300-x](#)
- Khan H, Khan MF, Jan SU, Mukhtiar M, Ullah N, Anwar N. Role of Glutathione in protection against mercury induced poisoning. *Pak J Pharm Sci*. 2012;25(2):395-400.
- Muhammad Assumaidade AA, Ali NM, Fadhil AA. Effect of vitamin E as α -tocopherol acetate on mercuric chloride-induced chronic oxidative stress and nephrotoxicity in rats. *Iraqi J Vet Med*. 2019;43(2):98-108. [10.30539/iraqijvm.v43i2.538](#)
- Patrick L. Mercury toxicity and antioxidants: Part 1: role of glutathione and alpha-lipoic acid in the treatment of mercury toxicity. *Altern Med Rev*. 2002;7(6):456-471.
- Saldana M, Collins CE, Gale R, Backhouse O. Diet-related mercury poisoning resulting in visual loss. *Br J Ophthalmol*. 2006;90(11):1432-1434. [10.1136/bjo.2006.094821](#)
- Uzunhisarcikli M, Aslanturk A, Kalender S, Apaydin FG, Bas H. Mercuric chloride induced hepatotoxic and hematologic changes in rats. *Toxicol Ind Health*. 2016;32(9):1651-1662. [10.1177/0748233715572561](#)

36. Dawood RA, Algheta H. Deleterious effects of mercuric chloride toxicity initiated partially from physiological disorder of kidney, immunocytes and redox system, can be reversed by resveratrol administration. *Adv Anim Vet Sci.* 2023; In press. [10.17582/journal.aavs/2023/11.9.1465.1471](https://doi.org/10.17582/journal.aavs/2023/11.9.1465.1471)
37. Rothenberg SE, Korrick SA, Fayad R. The influence of obesity on blood mercury levels for U.S. non-pregnant adults and children: NHANES 2007-2010. *Environ Res.* 2015;138:173-180. [10.1016/j.envres.2015.01.018](https://doi.org/10.1016/j.envres.2015.01.018)
38. Nicolás-Méndez T, Ortiz-Muñoz AR, Mendoza-Núñez VM, García-Rodríguez MC. The role of resveratrol on heavy metal-induced oxidative stress. *Nutr Hosp.* 2020;37(2):374-383. [10.20960/nh.02846](https://doi.org/10.20960/nh.02846)
39. Liu C, Zhang R, Yang L, Ji T, Zhu C, Liu B, et al. Neuroprotection of resveratrol against cadmium-poisoning acts through dual inhibition of mTORC1/2 signaling. *Neuropharmacology.* 2022;219:109236. [10.1016/j.neuropharm.2022.109236](https://doi.org/10.1016/j.neuropharm.2022.109236)
40. Zhang Q, Zhang C, Ge J, Lv M-W, Talukder M, Guo K, et al. Ameliorative effects of resveratrol against cadmium-induced nephrotoxicity via modulating nuclear xenobiotic receptor response and PINK1/Parkin-mediated Mitophagy. *Food Funct.* 2020;11(2):1856-1868. [10.1039/C9FO02287B](https://doi.org/10.1039/C9FO02287B)
41. Al Dera HS. Protective effect of resveratrol against aluminum chloride induced nephrotoxicity in rats. *Saudi Med J.* 2016;37(4):369-378. [10.15537/smj.2016.4.13611](https://doi.org/10.15537/smj.2016.4.13611)

إعطاء الرزفيراترول يقلل من سمية الكبد الناجم عن تعرض الجرذان الى كلوريد الزئبق

رسل عدنان داود^١، حسن فلاح كاشف الغطاء^١، أحمد خليل الأعظمي^٢

^١ فرع الفلسفة والكيمياء الحياتية والادوية، كلية الطب البيطري، جامعة بغداد، بغداد العراق، ^٢ فرع الامراض والأحياء المجهرية والمناعة، كلية الطب، جامعة ساوث كارولينا، كولومبيا، الولايات المتحدة الأمريكية

الخلاصة

خلال العقود الأخيرة أصبح التلوث والتسمم بكلوريد الزئبق ($HgCl_2$) من المشاكل الصحية الناتجة من التطور الصناعي المتسارع في أماكن عدة حول العالم. هدفت الدراسة الحالية للتحقق من إمكانية استخدام الرزفيراترول في عكس التأثيرات السلبية التي ترافق حالات التسمم بكلوريد الزئبق من خلال إعادة الوظيفة الطبيعية للخلايا الكبدية. لتحقيق هدف الدراسة الحالية، تم استخدام جرذان بالغة من سلالة Sprague Dawley وتقسيمها الى خمس مجاميع تجريبية وهي: مجموعة السيطرة (C) تركت جرذان هذه المجموعة بدون أي علاج لتفسير النتائج المتوقعة من المجاميع الأخرى. المجموعة الثانية من الجرذان (D) تم معاملتها بالناقل المستخدم لإذابة الرزفيراترول وهو المذيب العضوي أوكسيد الكبريت ثنائي الميثيل (DMSO). اما المجموعة الثالثة (R) فقد تم إعطاء جرذان هذه المجموعة مركب الرزفيراترول فمويًا وبجرعة ١٠٠ ملغم/كغم من وزن الجسم يوميًا ولمدة ٣٠ يوم. المجموعة الرابعة (HD) تم تعريض الجرذان فيها الى الحقن الخلوي لمركب كلوريد الزئبق وبجرعة ١ ملغم/كغم من وزن الجسم ولمدة ٣٠ يومًا متواصلة. وأخيرًا المجموعة الخامسة (HR) والتي تم تجريعها مركب كلوريد الزئبق والرزفيراترول بالجرع نفسها المذكورة أعلاه. عند نهاية فترة التجريب تم جمع عينات الدم لغرض اجراء الفحوصات المصلية لوظائف الكبد من خلال تقدير كمية الانزيمات التالية: Aspartate amino transferase (AST), Gamma-glutamyl transferase (GGT), Alkaline phosphatase (ALP) and Alanine amine transferase (ALT) وتقدير بعض مكونات الجهاز المنظم للجهد التأكسدي بالجسم مثل Malondialdehyde (MDA) and Glutathione (GSH). أيضا تم اخذ وزن الجسم على طول مدة الدراسة وتم جمع نسيج الكبد في نهاية التجربة لأغراض الفحص المرضي المجهرى للتغيرات الحاصلة. أظهرت نتائج الدراسة حصول زيادة معنوية ($P < 0.05$) في تراكيز AST, GGT, ALP وMDA في مصل مجموعة HD بالمقارنة مع مجموعة HR. في حين ان إعطاء الرزفيراترول الى الجرذان المعرضة الى كلوريد الزئبق (HR) أدى الى زيادة معنوية ($P < 0.05$) في تركيز مضاد الاكسدة GSH بالمقارنة مع مجموعة HD. أظهرت الفحوصات المرضية لنسيج الكبد حصول استنزاف بمحتوى البروتين السكري من خلايا الكبد التابعة لمجموعة HD على حين ان العلاج بالرزفيراترول أدى الى تثبيت هذا الاستنزاف وتقليل ترشح الخلايا الالتهابية بالمقارنة مع مجموعة HD. مما تقدم يمكن الاستنتاج ان إعطاء الرزفيراترول خلال تعرض الجسم الى التلوث الكيميائي ولاسيما كلوريد الزئبق يزيد من مقاومة الكبد للأكسدة المؤدية الى التسمم الكبدي من خلال زيادة انتاج مضادات الاكسدة مثل GSH والتي بدورها تحول من حدوث التغيرات المرضية النسيجية في الكبد.

الكلمات المفتاحية: الرزفيراترول، سمية الكبد، كلوريد الزئبق