

An effect of hyaluronan as abdominal post-operative anti-adhesive in dogs, macroscopic, laparoscopic and histopathological study

Shatha, M. Hashim and Serwa, I. Salih

Department of Surgery and Obstetrics, College of Veterinary Medicine, Baghdad University, Iraq.

E-mail: shatha_m1973@yahoo.com

Accepted: 17/6/2015

Summery

The aim of this study was to evaluate the effectiveness of hyaluronan as abdominal anti-adhesive. Sixteen healthy adult local breed dogs, aged between (1-2 years) and weighed (15-20) kg were used. They were divided into two equal groups. First group is considered as a control group (A), the second group is the hyaluronic acid group (B); both groups underwent celiotomy under the effect of general anesthesia (combination of ketamine-xylazine at the dose rate of 15mg /kg and 5mg/kg B.W, respectively). Three sero-muscular incisions were 3cm long created at anti-mesenteric border in the descending colon and sutured with simple continuous suture using 4-0 chromic cat gut, abdominal wall closed in routine manner, in control group. The same procedure was performed in group B but 2 ml of 1% sodium hyaluronate was applied intra peritoneally prior to abdominal closure. Evaluation of the results was based on macroscopic, laparoscopic and microscopic examinations. Macroscopic examination showed severe adhesions in all animals in both 7th, 30th post operative days with high grade scores (grade 3-4), except in one animal there was no adhesion in group A. While in group B, all dogs had developed mild adhesion formation at 7th post operative day in low grade score (grade, 1). By 30th post operative day there was no adhesion (grade, zero) except mild adhesion, in one case between omentum and abdominal wall (grade, 1). Histopathological examination showed dense fibrous connective tissue with congested blood vessels and irregular collagen fibers in group A. While in group B there were fine bundles of cellular connective tissue, granulation tissue with mononuclear cells infiltration. There were significant differences ($P < 0.05$) between group B (1.00 ± 0.00) and group A (3.50 ± 0.28) at 7th, also at 30th post operation a significant difference ($P < 0.05$) was found between group B ($*0.25 \pm 0.25$) and group A (2.75 ± 0.94) macroscopically. Histopathological examination also revealed a significant difference ($P < 0.05$) between group B ($*1.00 \pm 0.81$) and group A (2.75 ± 0.50) at 7th and 30th post operative days group B ($*1.00 \pm 0.81$) and group A (2.25 ± 0.95). The study revealed, the effectiveness of hyaluronan in reducing intra-abdominal adhesions that occurred after abdominal surgery in dogs, in comparison with control group.

Keywords: Adhesion, Hyaluronan, Laparotomy, Laparoscope, Histopathology.

Introduction

Intra-abdominal adhesions develop after abdominal surgery as part of the normal healing processes that occur after damage to the peritoneum, they also cause significant morbidity, including adhesive small bowel obstruction, infertility and increased difficulty with re-operative surgery (1). Much efforts has gone into understanding the biochemical and cellular mechanisms that lead to adhesion formation (2). The early balance between fibrin deposition and degradation seems to be the critical factor in adhesion formation. Different attempts have been employed to prevent adhesion formation which can be grouped into four categories: general principles, surgical techniques, mechanical barriers and chemical agents or others like

gene therapy and abdominal lavage, that act in different mechanisms, by decreasing peritoneal damage which decrease the initial inflammatory response, prevent fibrin formation, increases fibrinolysis, prevention of collagen deposition (2 and 3). Hyaluronan (HA) a natural component of joint synovial fluid (4 and 5). The hydrating and lubricating actions of hyaluronic acid maintains the vital function of different body parts such as skin, heart, eye and synovial fluid (6), hyaluronic acid has the anti-adhesive property that prevent the development of intra-abdominal adhesions at damaged peritoneal surfaces (7), several studies suggested that hyaluronan based agents have different mechanisms to decrease intra-abdominal adhesion formation

(8). Sodium hyaluronate seems to improve peritoneal healing by facilitating cells detachment, migration and by increasing the proliferation rate of mesothelial cells, thereby helping to restore denuded areas of the mesothelial lining (9).

Diagnostic Laparoscope is the most important method for diagnosis and treatment of intra-abdominal adhesion, it is minimally access surgery combined with the possibility of viewing areas of the peritoneal cavity not seen in traditional celiotomy (10). The aim of this study was to evaluate the effectiveness of hyaluronan as abdominal anti-adhesive in dog.

Materials and Methods

Sixteen apparently healthy local breed dogs, aged between (1-2 years) and weighed (15-20) kg were used. They divided randomly into two equal groups and were used as follows: First group was considered as control group (A), and second group was the Hyaluronic Acid group (B). Dogs were premedicated with atropine sulfate in dose rate of 0.03 mg/kg, then after 10 minutes the dog was anaesthetized by a mixture of ketamine-xylazine in dose rate of 15mg /kg and 5mg/kg B.W intra-muscle respectively (11).

The ventral abdominal wall of each dog was prepared for surgical operation. The animal was put in dorsal recumbency. In group A and after preparation and anesthesia, caudal midline celiotomy approximately 10cm long is made. The descending colon was isolated from the remaining viscera, then three sero-muscular incisions were 3cm long created at anti-mesenteric border. Incisions are closed by simple continuous pattern with chromic catgut no. (4-0), then rinsed by normal saline 0.9 %, the abdominal wall was closed by routine method. In group (B), the same procedure as mentioned in group (A) was performed but 2 ml of Hyaluronic acid was applied at the peritoneal cavity then abdominal wall is closed (12). Clinical examination of animal to check the body temperature, respiratory rate, for first three days after surgery. The histopathological examinations were made by macroscopic and microscopic examination of intra-abdominal lesions in both groups on (7th and 30th) post-operative days. Eight animals were used for each group (four dogs/period). Macroscopic

examinations were performed by gross examinations and laparoscopic assessment, changes were recorded for adhesions at all periods and arranged in scores according to Zühlke autopsy valuation of post operation intraperitoneal adhesion scores (13). Biopsies of 1cm³ were obtained from the sites of colon incision, processed tissues, then embedded in the paraffin block and sectioned by microtome at 5-7micrometer thickness. The slides were stained with Hematoxylin-Eosin (H and E) dye and special stain (Van Gieson's stain) and then examined under light microscope (Olympus-Japan) that provided by a digital camera (MEM 1300). Photograph analysis was done using image J (Java-based image processing program that developed at the National Institutes of Health) program for image processing and evaluation, also there is histopathological scoring to adhesion formation (14).

Results and Discussion

Animals showed equitable viability, good appetite, no marked differences in body temperature, heart rate and respiratory rate and no mortality had been recorded, daily check of the abdominal suture line for any signs of redness, swelling and wound, infection within the first 3-5 days after surgery. Macroscopic quantification of adhesion formation were evaluated by many independent observers (celiotomy, laparoscopic assessment) according to Zühlke autopsy valuation of post-operative intraperitoneal adhesion scores depending on severity of lesion (13) and scoring strength schemes by (15). In group (A) severe adhesions were observed in all animals in both 7th day, 30th day post-operative day, except one animal showed no adhesion formation, these results come in agreement with observation made by (16) in a study performed in rat model, which sacrificed at 7 different time-points over 3 weeks, with persistent adhesions formed in all animals were confirmed, at 7th post-operative day, all animals in this period had strong to severe adhesion formation with beginning of vascularization, sharp dissection need to be lysed. The adhesion occur in more than one place, it found between colonic incisional site-omentum and/or involve other bowels in

pelvic cavity, or between abdominal wall-omentum which developed grade (2-3) scores (Table, 1) and (Fig. 1), these observation correlate with study in rat model that indicate formation of high grade scores after abdominal surgery (17). In this study chromic catgut was used for suturing colonic incisions, which is responsible for the increase in the severity of adhesion formed in control group by causing tissue reaction, this finding is consistent with (18), as well as the suture material used still in surgical site and not absorbed even at 30th day period, that cause tissue inflammatory reaction that indicated by (19 and 20) who suggested chromic catgut cause adhesion in dog and need 120 days after procedure to absorbed. The peritoneal adhesion develops only several hours after the abdominal surgical operations as a part of healing process, the serous fluid exudes from the injured sides of intestinal wall and then fibrinogen in the serous fluid transforms to fibrin and coagulates, causing formation of membranous peritoneal adhesion in the injured intestinal wall, If fibrinolysis is not effective enough, fibrous adhesion develop at 2 week after the surgical operation (21).

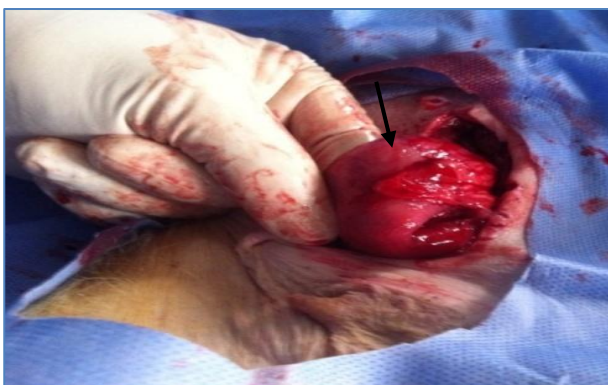At 30th post operative day the adhesion became stronger and graded between (3-4) (Fig. 2) grade score except one animal had no adhesion formation. The adhesion occurred in more than one place, it found between colonic incisional site-omentum and/or involved other bowels (small and large intestine) in abdominal cavity, or between abdominal wall-omentum. These results are similar to (22) who confirmed that incidence of adhesions formation was 75% after Abrasion of cecum and abdominal wall in rat model.

In this study steps were taken to minimize the effect of surgical technique or equipment on formation of adhesions. Some of these include: gentle handling, keeping the tissues moist, shortening surgical time and using starch-free and latex-free gloves, therefore one animal heal without any adhesion formation, this observation was supported by (23 and 24) whom suggested that the meticulous surgery technique can be effective in prevention of adhesion formation, in order to reduce unnecessary morbidity and mortality rates from these unwanted effects of surgery,

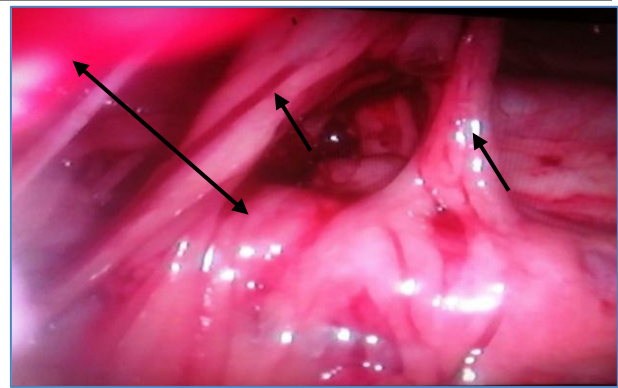
so the adhesion persist at this time of observation which mean that fibrinolysis had failed to minimize or lysis of primary fibrous adhesion before the 14th post operative day and the adhesion organized to form fibrous adhesion, this finding is described in a study of (21) which reported after several days from fibrin formation, the fibrinolytic system is activated and the fibrin is lyzed, so the membranous peritoneal adhesion is gradually reduced. If fibrinolysis through the plasminogen-plasmin cascade is not effective enough and induction of tissue hypoxia following reduction of blood delivery to mesothelial cells and sub-mesothelial fibroblasts, leading to collagen formation and angiogenesis, then collagen is deposited, furthermore the fibrin will be organized and develop fibrous adhesion, which usually forms at the 14th day after the surgical operation (25). In group (B) at 7th post operative day, all dogs showed mild adhesions formation at this period in low grade score (grade 1) (Table, 2), the adhesion occur in one region between (colonic incision-omentum) or (omentum-abdominal wall) (Fig. 3), which required gentle traction to broke it. This observation agree with the results of other study (17 and 26) whom that hyaluronan-based agents reduce adhesion formation after surgery in compared to the control group at the 10th day post operation.

Hyaluronan modulate the inflammatory response to injury and stimulate the angiogenesis that suggested by (27). Fibroplasia occurs during the proliferative phase of intestinal wound healing that continues from 3rd to 10-14 days. The fibroblasts produce large amounts of immature collagen, resulting in rapid gains in wound strength, collagen synthesis takes place in the presence of collagenolysis represented by collagenase activity at the wound edge that cause minimal and rapid gains in tensile and bursting strength (28). Sodium hyaluronate play important role in proliferative phase by improving the peritoneal healing by facilitating cells detachment and migration and increasing the proliferation rate of mesothelial cells and non-immunogenicity, this finding confirmed by (7). The hyaluronic acid nature make it good lubricant that facilitate the

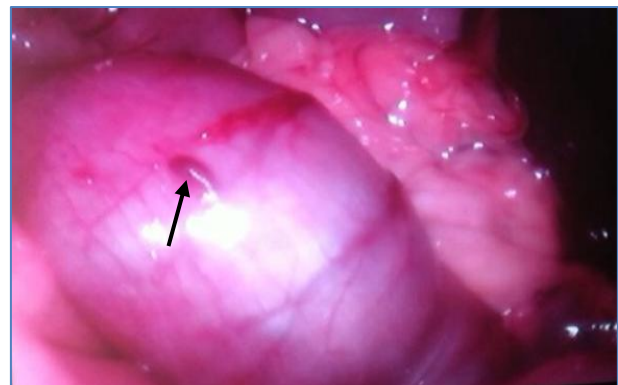gliding of movable intestinal part this agree with (28) who indicate that 1% solution of sodium hyaluronate are macromolecular properties at higher concentrations solutions is like jelly. Hyaluronic acid is one of the most hydrophilic molecules in nature and can be described as nature's moisturizer, decrease tissue dryness after gastro-intestinal surgery which lead to minimize adhesion formation, but at 30th post operative day, there was no adhesion in all cases except mild adhesion grade in one case between omentum and abdominal wall developed (grade,1) (Fig. 4). This result was close to those described by (29) in their study that compared the effect of a liquid sodium hyaluronate and HA-carboxymethyl cellulose membrane 'Seprafilm' in postsurgical adhesion formation in a murine model at 21th day post-operative day and confirmed that adhesion scores in mice receiving sodium hyaluronate and Seprafilm were lower than in mice of the control group and adhesion score for the sodium hyaluronate group was lower than the Seprafilm group. Other studies by (30 and 31) whom suggested that Hyaluronan-based agents reduce adhesion formation after surgery and indicated the use of hyaluronan solution in infectious conditions, to reduce abscess formation in experimental peritonitis. The result of observation at 30th post operative day more better than the observation at 7 day period, the mild adhesion disappear and the abdominal cavity healed normally with no adhesion formation.



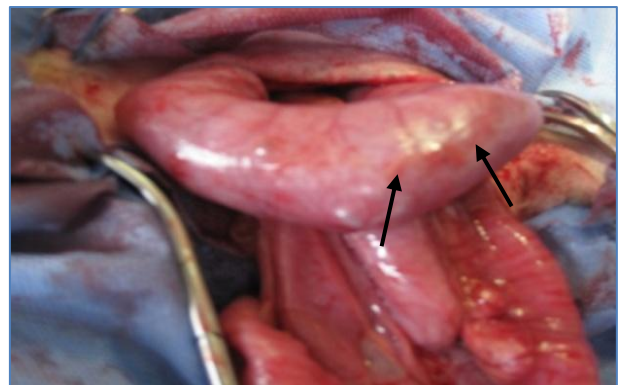
Figure, 1: Gross appearance of colon, shows severe adhesions at colonic incisional sites (arrow), beginning of vascularization (grade, 3), 7 days post-operation in group A.



Figure, 2: Laparoscopic image of pelvic cavity shows sever vascularized adhesions (arrows) covering the viscera and bind it with abdominal wall (↔), (grade, 4), at 30th day post-operation in group A.



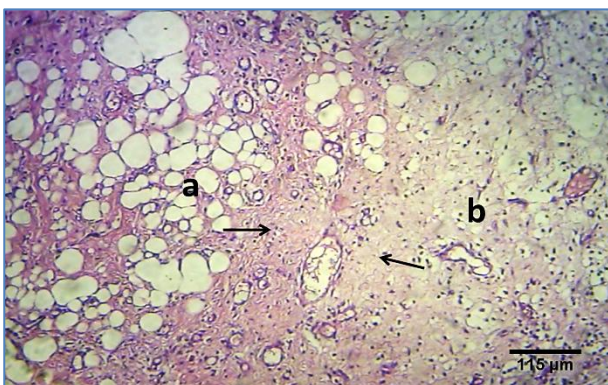
Figure, 3: Laparoscopic image of pelvic cavity, shows colonic incisional sites (arrow) with no adhesion formation (grade zero), 30th day post-operation in group B.



Figure, 4: Gross appearance of colon, shows the colonic incisional sites (thick, thin arrows) with no adhesions formation (grade, zero), 30th days post-operation in group B.

The histopathological results were recorded as histopathological fibrosis scores in (Table, 3), the control group at 7th day post operation the sections shows, marked fibrous connective tissue bundles in the serosa and omentum (Fig. 5), this closed to finding of (20). In study used chromic cat gut in colon of dog and at 7th days, the tunica muscularis was moderately to severely destroyed, where extensive areas of severe necrosis and inflammatory cells infiltration between muscle

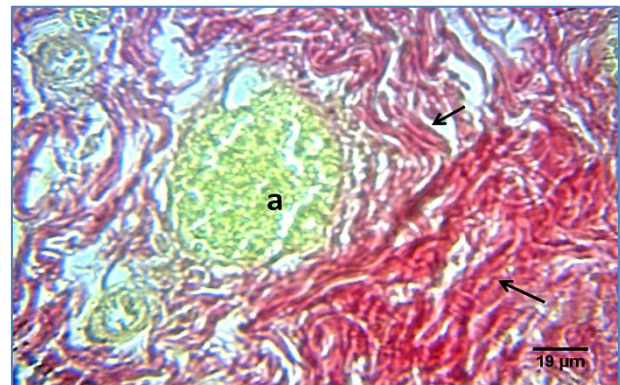
fibers were observed. The suture material was surrounded by large granulomas composed of numerous cellular infiltrations with fibroblastic capsule and the surrounding tissue was severely destroyed. In other study, histological examination of tissue from rats in the control group demonstrated lymphocytes, plasma cells, polymorphonuclear leucocytes and areas of fibrosis (17), while at 30th day post operation histopathological section in colon of animal shows congested blood vessels, with irregular collagen fibers red in color (grade, 3) by Van Gieson's stain (Fig. 6). This finding is close to (20), who showed that remnant of suture material is surrounded by large cellular granulomatous and fibrous connective tissue. The destruction of the tunica muscularis was subsided at 21 days in group sutured with chromic cat gut in colon of dog. In group B at 7th day post operation, histopathological section in colon of shows fine bundle of connective tissue with aggregation of mononuclear cell in serosa (Fig. 7) (grade, 1). This finding agree with study use hyaluronan based agent as abdominal anti-adhesive in rat cecum abraded model, and demonstrated formation of loose bundles of fibrous tissue in the treated group that reflect no adhesion formed at traumatized surfaces in comparison with strong fibrous tissue developed in control group that revealed adhesion formation between the traumatized surfaces (9).



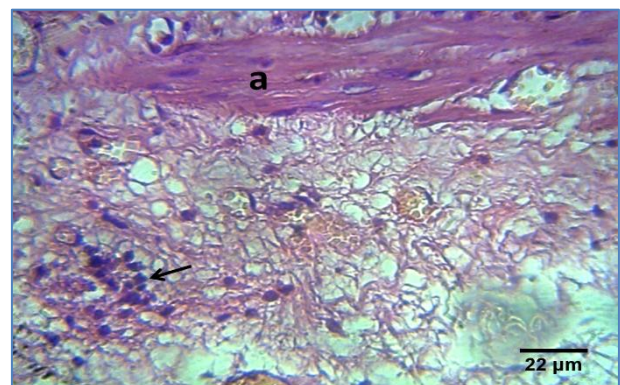
Figure, 5: Histopathological section in the colon and omentum of animal, shows marked fibrous connective tissue bundles (Arrows) in the omentum (a) and tunica serosa (b) also adhesion formation between them. H and E stain (grade, 3), 7th day post-operation, in group A.

At 30th day post operation, the histopathological section in colon shows red color fibrous tissue around suture material

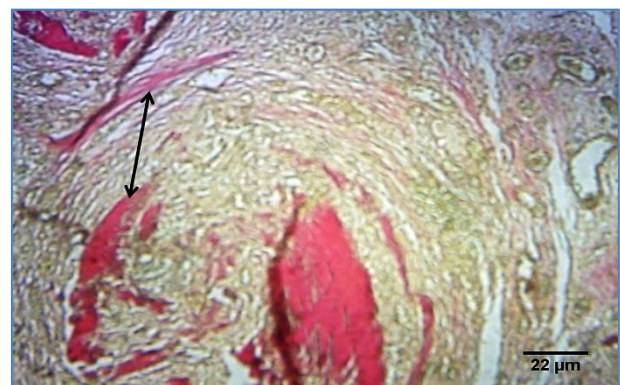(Fig. 8) (grade, 1), this results agree with (17) who demonstrated that decreased infiltration of inflammatory cells, fibroblasts and areas of fibrosis in group are treated with sodium hyaluronate base agent in rats model in compare with control group. Statistical analysis of histopathological results revealed a real difference ($P < 0.05$) between group A and B at 7 and 30 days post-operation (Table, 4).



Figure, 6: Shows congested blood vessels (a). Irregular collagen bundles (Arrows). (grade, 3) (Van Gieson's stain), 30th day post-operation, in group A.



Figure, 7: Shows bundle of connective tissue (a). Aggregation of mononuclear cells (Arrow). H and E stain (grade, 1), 7th day post-operation, in group B.



Figure, 8: Shows fibrous tissue around suture material (arrow). (Van Gieson's stain). (grade, 1), 30th day post-operation, group B.

According to all macroscopic, microscopic and static parameters, this study proved that

1% sodium hyaluronate is ideal abdominal anti-adhesion agent in dogs.

Table, 1: The adhesion scores according to macroscopic examination at 7th and 30th days post-operation for experimental groups.

Period of operation	Adhesion score							
	Group A				Group B			
7 th day	4	3	4	3	1	1	1	1
30 th day	0	3	4	4	0	1	0	0

Table, 2: The adhesion scores in each animal (microscopic examination) at the 7th and 30th days post-operation for experimental groups.

Period of operation	Adhesion score							
	Group A				Group B			
7th day operation	3	3	2	3	1	1	0	2
30th day operation	1	3	3	2	0	1	1	2

Table, 3: Means± SE of scores for the two groups according to Zühlke scores of post-operation intraperitoneal adhesions.

Group	Group A	Group B
7 days after operation	A 3.50±0.28 a	B 1.00±0.00 a
30 day after operation	A 2.75±0.94 a	B* 0.25±0.25 a

Means with different small letters in the same column differ significantly (P<0.05). Means with different capital letters in the same row differ significantly (P<0.05). *significant at the level of (P < 0.05).

Table, 4: Means± SE for both two groups according to histopathological grades of adhesions. Scores.

Group	Group A	Group B
7 days after operation	A 2.75±0.50 a	B *1.00±0.81 a
30 day after operation	A 2.25±0.95 a	B* 1.00±0.81 a

Means with different small letters in the same column differ significantly (P<0.05). Means with different capital letters in the same row differ significantly (P<0.05). *significant at the level of (P<0.05).

References

1. Ellis, H.; Moran, B. J.; Thompson, J. N. and Parker, M. C.; Wilson, M. S. and Menzies, D. (1999). Adhesion after abdominal and pelvic surgery, a retrospective cohort study. J. Lancet, 353: 1476-1480.
2. Schnüriger, B.; Barmparas, G.; Branco, B. C.; Lustenberger, T.; Inaba, K. and Demetriades, D. (2011). Prevention of Postoperative peritoneal adhesions: a review of the literature. Am. J. Surg., 1: 111–121.
3. Avital, S.; Bollinger, T. J. and Wilkinson J. D. (2005). Preventing of intra-abdominal adhesions with polylactic acid film: An animal study. Dis. Colon Rectum, 48: 153-157.
4. Alpaslan, H. and Alpaslan, C. (2001). Efficacy of temporo-mandibular joint arthrocentesis with and without injection of sodium hyaluronate in treatment of internal derangements. J. Oral Maxillofacial Surgery, 59(6): 613-618.
5. Hepguler, S.; Akkoc, S.; Pehlivan, M.; Ozturk, C.; Celebi, and Saracoglu, A. (2002). The efficacy of intra-articular sodium hyaluronate in patients with reducing displaced disc of the temporo-mandibular joint. J. Oral Rehabil., 29: 80-86.
6. Bill, C. (2010). Localization of hyaluronan in the skin. J. Invest. Dermato., 7: 39-45.
7. Cocolini, F.; Ansaloni, L.; Manfredi, R.; Campanati, L.; Poiasina, E.; Bertoli, P. and Catena, F. (2013). Peritoneal adhesion index (PAI): proposal of a World J. Emerg. Surg., 8(1): 8-42.
8. Robertson, J.; Linsay, R.; Feldkam, M.; Harris, D. and Rallison, M. (2010). J. Obstet Gynaecol. Can., 32: 598-608.
9. Jiang, S.; Wang, W.; Yan, H. and Cunyi Fan (2013). Prevention of Intra-abdominal adhesion by bi-Layer electrospun membrane. Int. J. Mol. Sci., 14(6): 11861–11870.
10. Claunch, K. and Mueller, P. (2012). Treating intra-abdominal adhesions: the surgeon's dilemma. J. Equine Vet. Edu., 24(11): 552–555.
11. Al-Asadi, R. N. and Al-Marashdi, H. H. (1990). The use of ketamine-xylazine combination as a general anesthesia for dogs. Iraqi Vet. Med. J., 1(2): 72-81.
12. Tobias, K. M. and Jonston, S. A. (2012). Veterinary small animal surgery. Williams, J. M., 2(93): 1542-1563.
13. Zühlke, H. V.; Lorenz, E. M.; Straub, E. M. and Savvas, V. (1990). Pathophysiology and classification of adhesions. J. Langenbecks Arch. Chir. Verh. Dtsch., 2: 1009-1016.

14. Yilmaz, H. G.; Tacyildiz, I. H.; Keles, C.; Gedik, E. and Kilinc, N. (2005). Micronized purified flavonoid fraction may prevent formation of intraperitoneal adhesions in rats. *Fert. Steril.*, 84(2): 1083–1088.
15. Lauder, C. I.; Garcea, G.; Strickland, A. and Maddern, G. J. (2011). Use of a modified chitosan-dextran gel to prevent peritoneal adhesions in a rat model. *J. Surg. Res.*, 171(2): 877-882.
16. Thaler, K.; Mack, J. A.; Berho, M.; Grotendorst, G.; Wexner, S. D. and Abramson, S. R. (2005). Coincidence of connective tissue growth factor expression with fibrosis and angiogenesis in postoperative peritoneal adhesion formation. *J. Eur. Surg. Res.*, 37(4): 235-241.
17. Emre, A.; Akin, M.; sikgonul, I.; Yuksel, O.; Anadol, A. Z. and Cifter, C. (2009). Comparison of intraperitoneal honey and sodium hyaluronate-carboxymethylcellulose (Seprafilm™) for the prevention of postoperative intra-abdominal adhesions. *J. Clinics*, 64(4): 363-368.
18. Akinrinmade, J. F. and Lawal, A. O. (2010). Gross and histologic evaluation of abdominal adhesions associated with chromic catgut and polypropylene sutured enteropexies in dog. *Int. J. Morphol.*, 28: 1221-1225.
19. Van Winkle, W.; Hastings, J. C.; Barker, E.; Hines, D. and Nichols, W. (1975). Effect of suture materials on healing skin wounds. *J. Surg. Gynecol Obstet.* 140(1): 7-12.
20. Zayed, M.; Haridy, M.; Misk, N.; Abd-El-Hady, Ab-N.; Sakai, H. and Yanai, T. (2014). Surgical and Histopathological Evaluation of Suture Materials for Closure of Colonic Wounds after Experimental Typhlectomy in Dogs. *Asian J. Anim. Vet. Adv.*, 9: 578-586.
21. Yang, B.; Gong, CH. Y.; Qian, Z. Y.; Zhao, X.; Li, Z. Y.; Qi, X. R.; Zhou, Qian Zhong, SH.T.; Luo, F. and Wei, Y. (2010). Prevention of post-surgical abdominal adhesions by a novel biodegradable thermosensitive PECE hydrogel. *J. Biomed Mater Res. B. Appl. Biomater.*, 96(1): 57-66.
22. Poehnert, D.; Abbas, M.; Kreipe, H. H.; Klempnauer, J. and Winny, M. (2015). High reproducibility of adhesion formation in rat with meso-stitch approximation of injured cecum and abdominal wall. *Int. J. Med. Sci.*, 12(1): 1-6.
23. Sulaiman, H.; Gabella, G.; Davis, C.; Mutsaers, S. E.; Boulos, P.; Laurent, G. and Sarah, E. (2001). Peritoneal adhesions. *J. Ann. Surg.*, 234(2): 256–261.
24. Liakakos, T.; Thomakos, N.; Fine, P. M.; Dervenis, C. and Young, R. L. (2003). Peritoneal adhesions: etiology, pathophysiology, and clinical significance. Recent advances in prevention and management. *Dig. Surg.*, 18: 260–273.
25. Coccolini, F.; Ansaloni, L.; Manfredi, R.; Campanati, L.; Poiasina, E.; Bertoli, P. and Catena, F. (2013). Peritoneal adhesion index (PAI): Proposal of a World J. Emerg. Surg., 8(1): 8-42.
26. Van Goor, H. (2007). Consequences and complications of peritoneal adhesions. *J. Colorectal Dis.*, 2: 25-34.
27. Collins, M. N. and Birkinshaw, C. (2007). Comparison of the effectiveness of four different crosslinking agents with hyaluronic acid hydrogel films for tissue-culture applications. *J. Appl. Polymer Sci.*, 104(5): 3183–3191.
28. Necas, J.; Bartosikova, L.; Brauner, P. and Kolar, J. (2008). Hyaluronic acid: a review. *J. Vet. Med.*, 53 (8): 397–411.
29. Oncel, M.; Remzi, F. H.; Senagore, A. J.; Connor, J. T. And Fazio, V. W. (2003). Comparison of a novel liquid (Adcon-P) and a sodium hyaluronate and carboxymethyl cellulose membrane (Seprafilm) in postsurgical adhesion formation in a murine model. *J. Dis Colon Rectum*, 46(2): 187-191.
30. Sikkink, C. J.; Zeebregts, C. J. and Reijnen, M. M. (2007). Hyaluronan-based antiadhesive agents in abdominal surgery: applications, results, and mechanisms of action. *J. Surg. Technol. Int.*, 16: 19-29.
31. Sikkink, C. J.; Reijnen, M. M.; Laverman, P.; Oyen, W. J. and Van Goor, H. (2009). Tc-99m-PEG-liposomes target both adhesions and abscesses and their reduction by hyaluronate in rats with fecal peritonitis. *J. Surg. Res.*, 154(2): 246-251.

تأثير الهائلورونان كمضاد للتصاقات في الجراحة الباطنية في الكلاب، دراسة عيانية و منظرية ونسجية مرضية

شذى مصطفى هاشم القصير و سرورة ابراهيم صالح
فرع الجراحة والتوليد، كلية الطب البيطري، جامعة بغداد، العراق.
E-mail: shatha_m1973@yahoo.com

الخلاصة

هدفت هذه الدراسة لتقييم عمل الهائلورونان كمضاد للتصاقات البطنية، قيمت نتائج التجربة اعتمادا على الفحوصات العيانية، المنظرية والمنظرية والدراسة النسجية المرضية. استعملت لهذه الدراسة ستة عشر من الكلاب المحلية البالغة، تراوحت أعمارها (1-2) سنة ووزن (15-20) كغم. قسمت على مجموعتين متساويتين. المجموعة الأولى اعتبرت مجموعة سيطرة (A)، والمجموعة الثانية هي مجموعة (B). خضعت كلتا المجموعتين لعملية فتح البطن تحت تأثير التخدير العام (مزيج الكيتامين-الزايلازين) بجرعة (15 ملغم/كغم-5 ملغم/كغم من وزن الجسم) بالتتابع. استحدثت ثلاثة جروح مصلية-عضلية بطول 3 سم لكل جرح في حافة مقابل المساريقي للقولون النازل، ومن ثم خيطت بالبسيط المستمر باستعمال قصابة الكروميك قياس (0-4)، وأغلق جدار البطن بالطريقة الروتينية، هذا بالنسبة لمجموعة (A). نفس التقنية أجريت في مجموعة (B) ولكن تم وضع (2) مل 1% هيلورونات الصوديوم في التجويف البريتوني قبل غلق البطن. قيمت النتائج اعتمادا على الفحوصات العيانية، المنظرية والفحص النسجي المرضي. أظهرت الدراسة فاعلية (B) في تقليل الالتصاقات داخل البطن مقارنة مع مجموعة (A). حيث بينت الفحوصات العيانية في مجموعة (A) وجود التصاقات شديدة في كل الحيوانات بالفترتين (اليوم السابع واليوم الثلاثين) بعد العملية وبدرجة (3-4)، باستثناء أحد الحيوانات حيث لم يلاحظ وجود التصاقات فيه. في حين في مجموعة (B) أظهرت تكوين التصاقات طفيفة عند اليوم السابع وبدرجة قليلة (درجة 1)، أما عند اليوم الثلاثين بعد العملية لم تظهر أي التصاقات (بدرجة- صفر) باستثناء حالة التصاقات طفيفة في احد الحيوانات والتي لوحظت بين الثرب وجدار البطن (درجة 1). بين الفحص النسجي المرضي، وجود نسيج ليفي رابط كثيف مع احتقان الأوعية الدموية وألياف غراوية غير منتظمة في مجموعة (A) بينما في مجموعة الهائلورونان كان هناك حزم دقيقة من النسيج الرابط، نسيج حبيبي وارتشاح الخلايا أحادية النواة. كانت هناك فروق معنوية عند مستوى ($P<0.05$) بين مجموعة B (1.00 ± 0.00) ومجموعة A (3.50 ± 0.28) عند اليوم السابع، وفي اليوم الثلاثين، كانت هناك فروقات معنوية ($P<0.05$) وجدت عيانيا بين المجموعة (B) (0.25 ± 0.25) والمجموعة (A) (2.75 ± 0.94). الفحص النسجي المرضي أيضا أظهر فرقا معنويا عند مستوى ($P<0.05$) بين المجموعة (B) ومجموعة (A) عند اليوم السابع وكذلك عند اليوم الثلاثين، حيث كانت لمجموعة B (1.00 ± 0.81) و (A) (2.75 ± 0.50) ثم (2.25 ± 0.95).

الكلمات المفتاحية: التصاقات، هائلورونان، فتح البطن الاستقصائي، المنظار البطني، الفحص النسجي المرضي.