

## Experimental study of Otitis media with *Pseudomonas aeruginosa* in mice and treated with alcoholic cold extract of dandelion compared with used of otucalm drops and *Lactobacillus acidophilus*

Narjis A. Al-khafaji

Zoonotic disease unit, College of Veterinary Medicine, Baghdad University, Iraq

E-Mail: [methaqn77@gmail.com](mailto:methaqn77@gmail.com)

Accepted on: 3/6/2013

### Summary

This study has revealed the importance of natural herbal products to control antibiotics resistant bacteria which are being a threat to human and animal health and focused on antibacterial potential of aqueous infusion of Dandelion alcoholic cold extract against *Pseudomonas aeruginosa*. The experimental studies include (18) healthy mice were randomly divided in to 6 equal groups, all 5<sup>th</sup> group injected with *P. aeruginosa* 10<sup>6</sup>CFU/ ml (0.05 ml) except 6<sup>th</sup> group which injected with phosphate buffer saline (control negative). 1<sup>st</sup> group killed after 48hr of injection, 2nd group treated with otucalm, 3<sup>rd</sup> treated with Dandelion cold alcoholic extract, 4<sup>th</sup> group treated with Dandelion locally and lactobacillus acidophilus orally, 5<sup>th</sup> group injected with bacteria (control positive) and killed after the end of the experiment. The result showed that the 4<sup>th</sup> group was the best group show the highly sensitive effect in vitro and no clear pathological lesion and increase the immunity and health of animal in vivo compare with other groups. Dandelion showed nontoxic effect and non-combination with other drugs and significantly increased the ability of *P. aeruginosa* isolated from otitis media it's more pathogenic than bacteria isolated from others organs in the same animals.

**Keywords:** Otitis media, Dandelion, Otucalm, *P. aeuginosa*.

### Introduction

*Pseudomonas aeruginosa* is a major infectious agent that causes otitis media, pneumonia, septicemia, enteritis, burn infection and sudden death. This bacterium is also a leading cause of nosocomial infection in human (1-3). Otitis media refers to inflammation of middle ear when infection occurs, the condition is called acute otitis media, or ear infection. Acute otitis occur when a cold, allergy, or upper respiratory infection including ear, nose, sinuses, larynx or voice box and throat. The presence of bacteria or virus lead to the accumulation pus, inflammation and mucus behind the eardrum, blocking the Eustachian tube.

*P.aeruginosa* is commonly resistant to antibiotics (4 and 5). Therefore, these studies suggest treating bacteria with others treatment like plant extract, probiotic bacteria compared with recent treatment otucalm.

Dandelion is type of plant, the common Dandelion, enemy of suburban lawns, is an unusually nutrition's food. It's leaves contain substantial levels of vitamins A, C, D and B complex as well as Iron, Magnesium, Zinc,

Potassium, Copper, Choline, Calcium, Boron and Silicon (6). The root has been used for the treatment of variety of liver and gallbladder problems. Other historical uses of and leaves include the treatment of breast disease, water retention, digestive problem, joint pain, fever and skin disease and have antiseptic inflammatory action. The most active constituents appear to be eudesmanolide and germacranolide other ingredients include taraxol, taraxerol and taraxasterol, along with stigmasterol, beta-sitosterol, caffeic acid and p-hydroxy phenylactic acid (7).

Otucalm is combination eardrops have more than one active ingredient and are generally designed to treat multiple aspects of otitis media or to otitis external. Analgesic ear drops are used to reduce or eliminate pain generally in association is normally use, combination of Antipyrine and Benzosanin (8).

*Lactobacillus acidophilus* was regarded as a major group of probiotic bacteria (9 and 10). The probiotic concept has been defined by (11) to mean a live microbial feed supplement which beneficially affects the host animal by improving it intestinal microbial balance (12). Various substrates like lactose, biogenic

amines and allergenic compound into short-chain fatty acids and other organic acids and gases (13). Synthesize enzymes, Vitamins, Antioxidants and Bacteriocins (14) in probiotic bacteria. The aim of this study is to reveal the importance of natural herbal products to control antibiotics resistant bacteria which are being a threat to human and animal health and focused on antibacterial potential of aqueous infusion of Dandelion alcoholic cold extract against *Pseudomonas aeruginosa*.

### Materials and Methods

For isolation of *P. aeruginosa* from ear otorrhea, samples were collected by ear swab of mice infection were spread on specific media (*Pseudomonas* agar) and incubated at 37°C for 24hr. Isolates were identified on the basis of colony pigment, Gram staining, catalase activity, oxidase and gelatin positive test (2).

Eighteen White Balb/C mice from both sexes were used. Animals were randomly divided in to six equal groups. The animal prepare to injection by fixed the animal on the table with low ether anesthesia and irritation the ear by needle, then inject with suspension of *P. aeruginosa* 10<sup>6</sup> CFU/ml, Bacterial suspension containing 10<sup>6</sup> CFU/ml live attenuated *P. aeruginosa* (15) by standard plat count (16). The first group was injected with 0.05 ml suspension of *P. aeruginosa* then killed after 48 hr (control positive). The 2<sup>nd</sup> group was treated with otucalm drops after 48hr of infection for 10 days. The 3<sup>rd</sup> group was treated with dandelion (cold extract) after 48hr of infection for 10 days. The 4<sup>th</sup> group was treated with Dandelion extract topically and *Lactobacillus acidophilus* 3X10<sup>8</sup> CFU/ ml orally, it were prepared suspension obtained from Agriculture College in 3X10<sup>8</sup> CFU/ml live attenuated (17). The 5<sup>th</sup> group was killed by anesthetized then anatomically incision collection of internal organs then kept in 10% formalin for histopathological after the end of the experiment (control positive without treatment). The 6<sup>th</sup> group was injected with phosphate buffer saline (control negative).

Histopathological examination ear canal section were done after the infection of the 1<sup>st</sup>,

5<sup>th</sup> and 6<sup>th</sup> groups; and after treatment of 2<sup>nd</sup>, 3<sup>rd</sup> and 4<sup>th</sup> groups to show the pathological changes and effect of treatment (18).

Otucalm is ear drop, analgesic and antiseptic composition. (PHARCO Pharmaceutical -Alexandria, Egypt). Phenazon 5 % W/W. Chlrbutol 1 % W/W. From Pharmaceuticals Alexandria. Discs of antibiotics include: Gentamicin, Doxycyclin, Cephalexin, Erythromycin, Amoxicilin+Clavulonic Acid, Carbenciline, Ampicilin, Trimethoprim and Azithromycin (19 and 20). (Bioanalyse<sup>R</sup>) Susceptibility Discs For Invitro Diagnostic Use.

Prepared the cold alcoholic extract of Dandelion plants (National Center for Complementary and Alternative Medicine).

Collection of the plant: The right location and time for collecting of plant very important (after the flowers are gone but before first frost, avoiding roadside growth in healthy soil. Rinse or wash the plant with normal saline 1-3 times to clean the plant material and remove any dirt, stones or insects. The plant was chopped into pieces of about 1/4 inch in size using a knife and cutting board being careful not to sever them. Then dry the plant for a way of the light in the air, then was kept the plant in blender until obtained fine powder, 150 gm of plant in flask was kept and added 450 ml of alcohol 70% Ethanol, put the flask in freeze (-20 C°) for 9 days after that put it on a magnetic stirrer for 20 minutes, filter the extract by gauze then filter paper (240mm) in size then kept in oven for 37C° for 3 days to preparation of dose concentration (3gm dissolved in 10 ml alcohol 70% to obtained 300 mg/ml Dandelion extract (for Invitro experiment)(21) .

For Invivo Experiment Dandelion extract is usually an herbal in liquid made of final extract alcohol and glycerin is generally using for externally ear drop (22).

The data were analyzed using one way analysis of variance (ANOVA) and data subjected according to (23).

### Results and Discussion

The results of inhibition effect of otucalm drops, Dandelion cold alcohol extract and *Lactobacillus acidophilus* in growth of *P. aeruginosa* Invitro was showed the effect of

Dandelion cold alcohol extract best of others treatment in this experimental that showed the heights value in its inhibitory effect (23.3 mm) zone of inhibition then followed by otucalm effect which showed significant inhibitory effect (21.3 mm) of *P.aerugenosa* growth while the *Lactobacillus acidophilus* showed the lowest significant effect with (15.6 mm) of inhibition zone( table, 1 and Fig. 1).

The result showed the sensitivity effect of *P. aerugenosa* for Azithromycin which gave 25 mm of zone inhibition and resistance for Gentamycin, Amoxicillin+Clavulanic acid, Doxycyclin, Cefalexin, Erthromycin, Ampicillin, Carbenicillin and Trimethoprin (table, 2).

The clinical signs of experimental infection post 48 hr of infection showed discharge of exudates from ear (otorrhea), swallowing of face, dyspnea, depression facial edema, circling or totting of head (torticollis) and weight loss (Fig. 2), compare with control group which injected with phosphate buffer saline.

The histopathological section showed purulent exudate consist from dead neutrophil in middle ear cavity with focal thickness of mucosa may be due to inflammation (Fig. 3), edema and inflammation cell mainly neutrophil are infiltrate in sub epithelial layer of external ear. (Fig. 4). Also inflammation cell around blood vessels of external ear, in other section hyper cellularity of fibrin network deposition in monolayer cavity of temporal bone (Fig. 5).

Market mononuclear cell infiltration in adipose tissue of ear (Fig. 6), congestion of blood vessels with neutrophil around. Also infiltrated reaction were seen around the hair follicle and between muscles fiber of external canal were seen in and inflammation cells between muscle fiber (Fig. 7 and 8).

The result of treatment by suspension of Dandelion cold alcoholic extract the examination of ear infected by *P. aerugenosa* which treated after 48 hr of infection and treated for 10 days the external ear showed no clear pathological signs and mice showed healthy appearance. Histological section show no clear pathological lesion except little

mononuclear cell infiltration between hair follicle of external canal (Fig. 9).

The result of otucalm drop treatment after 48 hr of infection and for 10 days the animals became healthy and no clear clinical signs were appeared.

Histopathological, there are few mononuclear cell were recorded between hair follicle, sweet gland of auricle of external gland and adjacent to deposit tissue of external canal, also in breast thickness in cell membrane may be due to proliferation of canal tissue as well as few inflammation cell infiltrated in middle canal (Fig. 10), the others parts of ear showed no clear lesion were reported.

The result of *Lactobacillus acidophilus* orally and Dandelion extract topically treatment after 48hr of ear infection for 10 days appeared the best group which shows the effect of treatment macroscopically and histopathological. The result of clinical signs of ear infection with *Lactobacillus acidophilus* orally and Dandelion extract topically show no pathological clinical signs and the animal became healthy.

The result of control groups which injected with *P. aerugenosa* without treatment and exterminate after 10 days the clinical signs of animals showed depression, weakness, dry hair, loss of appetite and some animal die. The histopathological examination showed fibrin proliferation and mononuclear cell in external canal and between fibrous connective tissue of membrane of pernal ear (Fig. 11), the others part of ear showed no clear lesion.

The result of clinical signs of all groups were showed acute clinical signs of otitis media which characterized by otorrhea, face edema and pain. This result agreed with (24 and 25), who reported that edema, discharge of ear and pain may be due to Eustachian tubes equalize pressure inside and outside of ear the reason of pain. Edema in this study due to pressure of fluid on sensory nerves and accumulation of fluid may be pressure on tube Eustachian, this makes its easier for fluid to get trapped in the middle ear and caused edema this results was agreed with (2). Also the pathogenesis of *P. aerugenosa* which cause

pressure of fluid behind the ear drum, usually bringing on relief from pain (26).

The histopathological section were showed purulent exudates consist from dead neutrophil in middle ear cavity with focal thickness of mucosa due to inflammation cells mainly neutrophil were infiltrate in sub epithelial layer of external ear, edema and hyper cellularity of fibrin network deposition in monolayer cavity of the temporal bone. On the other hand *P. aeruginosa* may provide the following benefits factors for infection, because the ability to stick to cells, production of proteins and toxin A those damage tissue, have protective outer coat, minimal food requirement and resistant to many antibiotics (4). Inflammatory changes similar to those observed in human middle ear infection and acute inflammatory cell infiltration was seen at 7 day and 14 day gradually decreasing to chronic inflammatory changes with fibroplasias at 60 days (27).

Bone resorption was observed at 7 and 14 days, changing to a bony deposition at 30 days. This results was agreed with (28) who raising the possibility that *P. aeruginosa* in otitis media is specific variety that displays particular characteristics.

This evidence was in agreement with other studies (28 and 29) who showed *P. aeruginosa* adhesion to the epithelium which was significantly increase for external otitis and otitis media by increase deoxyribonuclease production and significantly decrease production of pyocin and alginate .

In this study the result suggested that treatment of antibiotic was led to reduce the susceptibility of this isolate due to the period of treatment type of antibiotic, not complete of treatment period. Furthermore, resistance of *P. aeruginosa* to various antibiotics (30). The outbreak of *P. aeruginosa* infection and resistant to antibiotics lead to invasion of bacteria and act as immunosuppression by the progressive for all organs of body and some of animals die (31 and 32). This evidence was supported by the observation mentioned by (33), who was explained that *p. aeruginosa* has high virulent due to secretes several toxins and enzymes those enhance it virulence, three well characterized protease: two elastase and an

alkaline it's been widely proved that *P. aeruginosa* has remarkable effect of immune system because of protease which act synergistically to cleave connective tissue degraded by *P. aeruginosa*. Protease includes elastin and collagen those agree with studies that showed the protease may be mediate Hageman factor activation, immunoglobulin and complement degradation and cytokine in activation (34).

The results of studied treatment studies in laboratory animals in-vivo and agar well diffusion method plats in-vitro suggested that alcoholic extract of Dandelion showed the highest value in its inhibitory effect on *P. aeruginosa* growth in-vitro. Dandelion has played antiseptic effect due to the root has one of the terpenoid alcohols that's agree with studies showed the antibiotic action an herbal formula known as fuzhengquxic was just as effective as the antibiotics gentamycin in 75 cases. This agreed with the study that suggest no negative effect of Dandelion in combination with pharmaceutical drugs in rat found that 2gm/kg B.W. of Dandelion with drug ciprofloxacin greatly impaired absorption of this antibiotic due to minerals contents of dandelion (35 and 36). Other plants were used in treatment of otitis media like: Belladonna, Calendula, lavender and others plants which act as integrative therapies (37).

Growth In vivo this plant has anti-inflammatory effect, among the most important compound are sesquiterpene lactones believed to have anti-inflammation and anti-cancer effect, phenylpropanoids have inflammation –modulating effect (38). The ethanol extract of the dried Aerial part have been shown in rodents studies to reduce inflammation and inhibit angiogenesis though which constituents were responsible for this effect were not investigated (39). Also Dandelion is very safe to enhance the immune response to upper respiratory tract infection and as topical compress to treat abscess and mastitis. The pathological effect in histological section showed no clear lesion, the study suggest that Dandelion may help in relive fluid retention (edema) and treatment inflammatory condition (40). The effect of potassium to relive the fluid accumulation because of leaf of



Dandelion is a good source of potassium (100gm of dandelion contained 297mg of potassium (26 and 41).

In this study otucalm drop show the inhibitory effect Invitro and Invivo in growth of bacteria and repaired tissue damage, the study suggest that otucalm has analgesic action due to phenazone and antiseptic properties due to chlorbutol. Is a potent antiseptic agent with prominent antibacterial and antifungal properties, so it relieved pain and discomforting the ear. This evidence was in agreement with other studies showed the analgesic effect otucalm reduce pain generally is association with otitis media (42).

Probiotic bacterial effect study suggest that *Lactobacillus acidophilus* may has

antibacterial effect or eradication rates of bacteria (43). Numbers of mechanism work to prevent harmful bacteria from growing on and attaching to epithelium cell and secretion of antimicrobial agents such as bacteriocins and organic acids (44). This agree with others studies used of honey and probiotic to reduce colonization of many pathogens include *P. aerugenosa* (45). Some studies showed the probiotic prophylaxis may prevent colonization and delay the onset of pseudomonas infection (46). In this study *Lactobacillus* increase immunity by increase lymphocyte cell and splenomegaly that agree with study showed *lactobacillus acidophilus* enhancing immune response like IgG and secretary IgA and IgM (47 and 48).

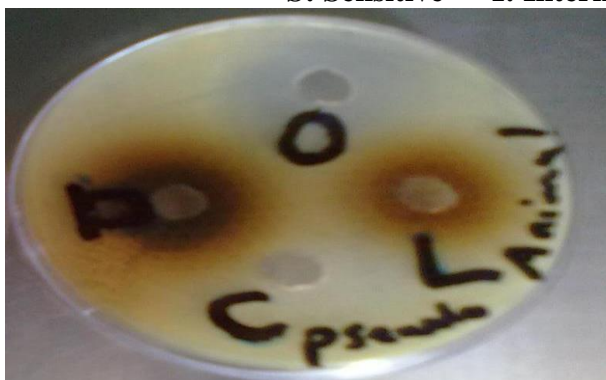**Table, 1: Show the inhibition effect of Dandelion cold alcoholic extract and Lactobacillus acidophilus, Outocalm against P. aerugenosazon.**

Bacteria	Cold extract of Dandelion			Mean ± S.E.	Lactobacillus Acidophillus			Mean ± S.E.	Otucalm drops			Mean ± S.E.
Pseudo. aerugenosa	23	24	23	23.33 ± 0.2722	16	15	16	15.66 ± 0.2722	21	22	21	21.33 ± 0.2722

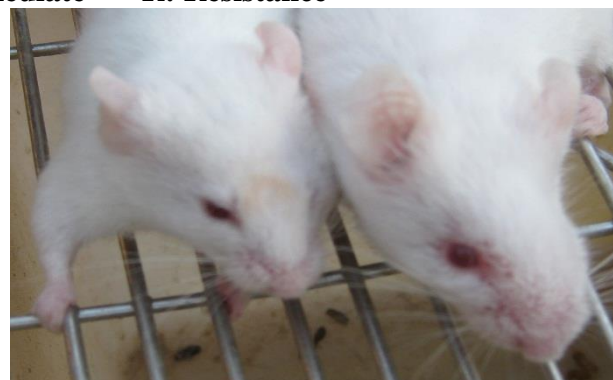**Table, 2: Inhibitory effect of some antibiotic disc against P. aerugenosa zone bacteria.**

Number	Antibiotic disc	P. aerugenosa zone inhibition	S.I.R.	Standard of S.I.R. according to (4)
1	Azithromycin(Azm)15mcg	25mm	S	20 of sensitivity
2	Gentamycin(CN)10mcg	7mm	R	12 of resistance
3	Amoxicilin + Clavulanic acid(Amc)30mg	Zero	R	13 of resistance
4	Doxycycline(Do)30mcg	8mm	R	13 of resistance
5	Cephalexin(CI)30mg	Zero	R	14 of resistance
6	Erythromycin(E)15mcg	Zero	R	13 of resistance
7	Carbenicilin(Py)100mcg	Zero	R	13 of resistance
8	Ampicilin(Am)10mg	Zero	R	13 of resistance
9	Trimethoprin (Tmp)	Zero	R	10 of resistance

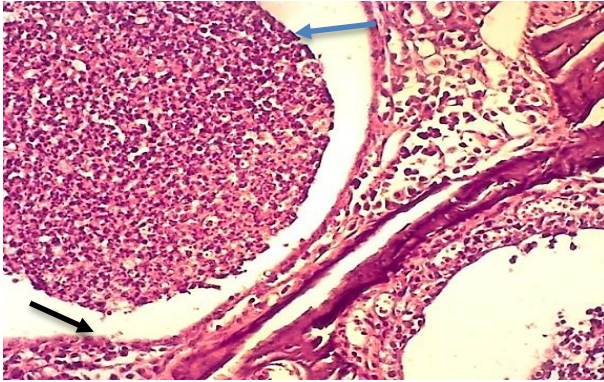
S: Sensitive I: Intermediate R: Resistance



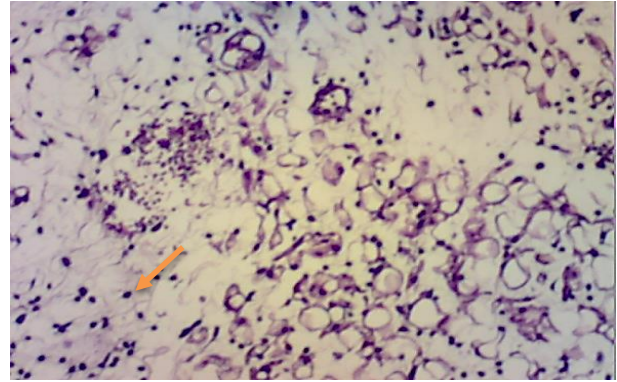
Figure, 1: Show the inhibitory effect of dandelion, lactobacillus and outocalm against Pseudomonas aerugenosa. D: dandelion, L: lactobacillus, O: Otucalm and C: control (alcohol).



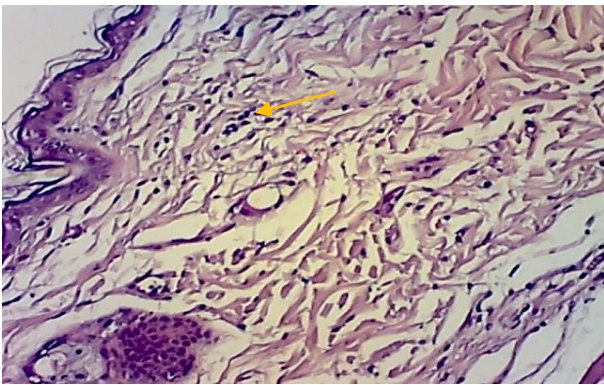
Figure, 2: Show swallowing of face and torticollis.



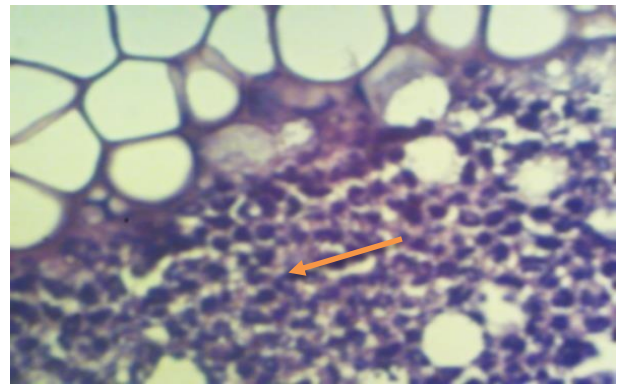
Figure, 3: Ear of animal at 48 hr. post infection show purulent exudates in the middle ear cavity —→ and focal thickness in the mucosa —→ H& E stain 40X.



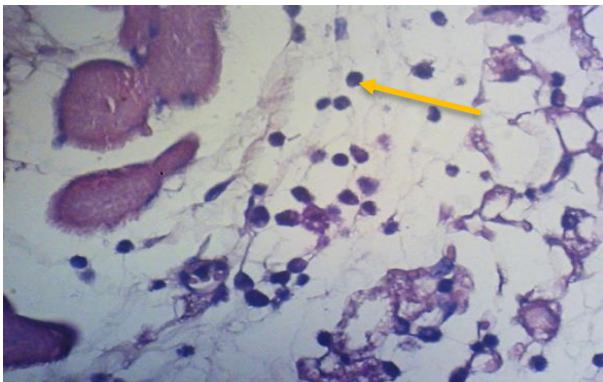
Figure, 4: Histological section show odema and neutrophil infiltration in sub epithelial layer of external ear. H &E stain 40X.



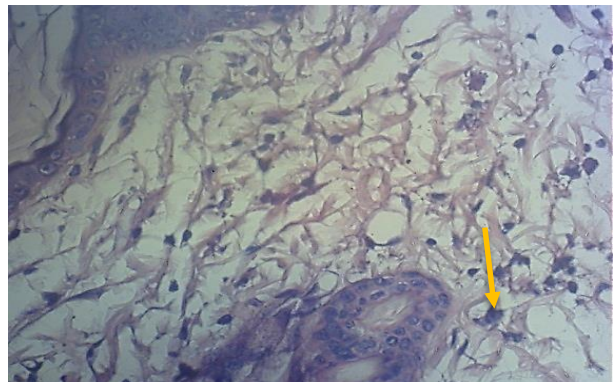
Figure, 5: Histological section show inflammation cell aggregation around blood vessel of external ear in other section hyper cellularity of fibrin network deposition in monolayer cavity of temporal bone. H &E stain 40X.



Figure, 6: Histological section shows market molecular cell infiltration in a deposition tissue of ear. H & E stain 40X.

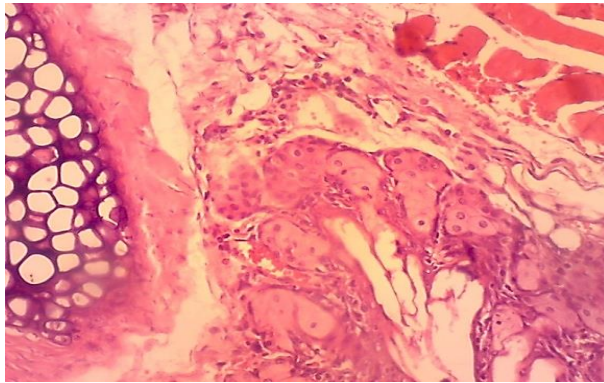


Figure, 7: Histological section show inflammation cell (Neutrophil) between muscle fiber. H&E stain 40X.

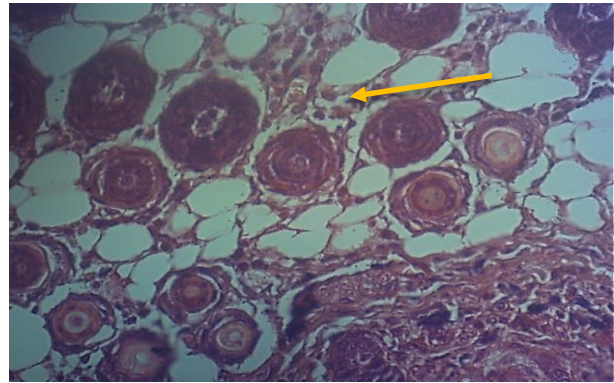


Figure, 8: Histological section of skin show inflammation cell around the hair floccules. H & E stain 40X.





**Figure, 9:** Section in ear of animal treated with dandelions extract at 48 hr of infection show little inflammation cell infiltration around hair floccule. H& E stain 40X.



**Figure, 10:** Section of ear show fibrous proliferation and mononuclear cell in external canal and between fibrous connective tissue of membrane of external ear . H& E stain 40X.

### References

1. Ryan, K.J. and Ray, C.G. (2004). Sherris Medical Microbiology. 4<sup>th</sup> Ed. McGraw. Hill, PP:8385-8529.
2. Todar, K. (2009). Opportunistic infection caused by *pseudomonas aeruginosa*. <http://textbookofbacteriology.net/pseudomonas.html>.
3. Winn, W.; Allen, S.; Janda, W.; Koneman, E.; Procop, G.; Schreckenberger, P. and Woods, G. (2006). Koneman's Color Atlas and Textbook of Diagnostic Microbiology, Color Atlas and Textbook of Diagnostic Microbiology. 6<sup>th</sup> Ed., Chapter 6, Willey, PP:236-238.
4. Quinn, P.T.; Markey, B.K.; Carter, M. E.; Donnelly, W.J. and Leonard, F.C.(2006). Veterinary Micro Diseases. Printed and bound in great Britanary international. Ltd padstow – cornwall.
5. Anzai, Y.; Kim, H.; Park, J.Y.; Wakabayashi, H. and Oyaizu, H. (2000). Phylogenetic affiliation of *pseudomonas* based on 16s rRNA sequence. *Int. J. syst. Evol. micrbiol.*, 50(4): 1563-1589.
6. Leung, A.Y. and Foster, S. (1996). Encyclopedia of common natural ingredients Used in food, Drugs and Cosmetics 2<sup>nd</sup> ed . New York, NY: Willey, PP:205-206.
7. Dyeovich, D. and Bogenschutz, M.P. (2001). Herbal diuretics and lithium toxicity *AM. J. Psychiatry*, 158:1329-1329.
8. Marcy, S. (2011). Infections of the ear and sinuses. *Audio-Digest Famly Pracctice.*, 59 (35):1-10.
9. Collins, J.K.; Thoruton, G. and Sullivan, G.O. (1998). Selection of probiotic strain for human applications. *Int. Dairy J.*, 8:487-490.
10. Schrezenmei, J. and Devrese, M. (2001). Probiotics, Probiotics and synbiotics-approchig a definition. *Am. J. Clin. Nutr.*, 73: 3615-3645.
11. Fuller, R. (1989). A review: Probiotics in man and animals. *J. Appl. Bact.*, 66:365-378.
12. Giobson, G. R. and Fuller, R. (2000). Aspects of invitro and invivo research approaches directed toward identifying probiotics and probiotics from human use. *J. Nutr.*, 130: 3915-3955.
13. Jay, J. M. (2000). Fermentation and fermented dairy product. P.P: 113-130. In modern food microbiology, 6<sup>th</sup> ed. An aspen publication, aspen publishers, Inc. Gaithers burg, U.S.A.
14. Knorr, D. (1998). Technology aspects related to microorganisms in functional foods trends. *Food Sci.*, 9:295-306.
15. David, M. and Moore, D.V. (1997). Reference Paper: *Pseudomonas* and the laboratory animals. *J. Appl. Biotechnolo.*, 1 (1): 54- 62.
16. Michale, J. and Burtone, E. (2005). A photographic atlas for laboratory microbiology, Section Thirteen: Bacterial pathogens : *Pseudomonas aerogenusa* 3<sup>rd</sup> Ed . PP:149- 150.
17. Coconnier, M. H.; Lievin, V. and Servin, A. L. (1998). Antagonistic activity against *Helicobacter* infection invitro and invivo by the human *lactobacillus acidophilus* strain LB. *Appl. Environ Microbiol.*, 64(11):4573-4580.
18. Luna, L.G. (1968). Manual of histologic staining method of the armed forces Institute

- of pathology. 3<sup>rd</sup> Ed. Mc Graw Hillbook Company, New York.
19. Mcvay, C.; Velasquez, M. and Fralick, J. (2007). Phage therapy of *Pseudomonas aeruginosa* infection in mouse burn wound model. *Antibact. agents Chemoth.*, 51(6):1934-1938.
  20. Yasuko, H.; Sasuki, H.; Kawamoto, E.; Ishikawa, H.; Matsumoto, T.; Aoyama, N.; Kawasum, K. and Amao, H. (2010). Prevalence and analysis of *Pseudomonas aeruginosa* in chinchillas. *MBC Veterinary Research*, 6 (52):1-10.
  21. Ahmed, I.; Agil F. and Owais, M. (2006). *Modern Phytomedicine: Turning Medicinal Plants into Drugs*. VHC, Weinheim Germany.
  22. Smith, (2003). *Therapeutic herb manual*. Liquid extract with root dandelion. [http://herbaled.com/THM/Singles/dandelion\\_fs.html](http://herbaled.com/THM/Singles/dandelion_fs.html).
  23. Steel, R.G. and Torrie, J.H. (1980). *Principles and procedure of statistic* 2<sup>nd</sup> Ed. Mc Graw Hill, New York.
  24. Doyle, W.J. (1989). Animal models of otitis media: the pathogens *pediatr. infect. Dis. J.*, 8: 545-547.
  25. Ehrlich, G.D.; Veeh, K.; Wang, X.; Costerton, J.W.; Hayes, J.D.; Huf, Z. and Daigle, B. (2002). Mucosal biofilm Formation on middle ear mucosa in the chinchilla model of otitis media. *J.A.M. J.*, 287: 1710 – 1715.
  26. American academy of family physicians. (2009). [www.aafp.org](http://www.aafp.org).
  27. Trinidad, A.; Ramírez-Camacho, R.; García-Berrocal, J.R.; Verdaguerm J. M.; Vicente, J. and Daza, R. (2007). Tissue changes induced by *Pseudomonas aeruginosa* in an otitis media rat model with tubal obstruction. *Acta otolaryngol.* 127(2): 132-137.
  28. Sudstrom, J.; Agrup, C.; Kronvall, G. and Wretlind, B.(1997). *Pseudomonas aeruginosa* adherence to external auditory canal epithelium. *Arch. Otolaryngol. Head neck surg.*, 123(12): 1287-1292.
  29. Gyles, G.L.; John P. Glenn S. and Charles, O. (2010). *Pseudomonas pathogenesis of bacterial infection in animals*. 4<sup>th</sup> Ed, Wiley-Blackwell, PP: 443-460.
  30. AL-Zamily, K.Y.(2007).The role of listeria monocytogenes in immune response against *pseudo. aeruginosa* infection in mice . MSc Thesis, College of Vet. Med. University of Baghdad.
  31. Cockerill, F. R.;Wikler, M. A. ; Alder, J.; Dudley, M.N.; Eliopoulos, G.M.; Ferraro, M.J.; Hardy, D.J. and Hecht, D.W. (2012). *Methods for dilution antimicrobial susceptibility tests for bacteria that grow aerobically*. 8<sup>th</sup> edition. Clinical and Lab. Standards Institute, 32(2): 12-54.
  32. Jawetze, E. ; Melink, J. L. and Adelberg, E. A. (2004). *The pseudomonas group*. Medical microbiology, 2<sup>3rd</sup> Ed . Lang medical book. PP: 262-264.
  33. Petermann, S. R.; Doetkott, C. and Rust, L. (2001). *Clinical and vaccine Immunology for clinical and diagnostic laboratory Immunology*. Am. society Microbi., 8(3): 632-636.
  34. *Clinical and vaccine immunology*. (2011). American society for microbiology journals. Asm. Org. 1752 N street N. W. Washington DC20036202. 737. 3600.202. 942. 9355.Fax. Journals @ asmusa. Org.
  35. Zhum, W.L. (1999). Effects of *Taraxacum mongolicum* on the bioavailability and disposition of ciprofloxacin in rat. *J. Phram. Sci.*, 88(6): 632-634.
  36. Eric, Y. and Abascal, K. (2009). Dandelion (*Taraxacum officinal* and *T mongolicum*). *Integrative Med.*, 8(2):35-38.
  37. <http://www.naturalstandard.com/>
  38. Schutzk, C.R. and Schieber, A. (2006). *Taraxacum – A review on its phytochemical and pharmacological profile*. *J. thno. pharmacol.*, 107(3): 313-323.
  39. Brown, R.W.(1956). *Composition sciention of scientific words*. Smith sonian in stitutional press.ISBNO-87474-286-2.
  40. The herbalist of MDidea extract professional dandelion and taraxacum officinal dandelion extract.<http://www.mdidea.com/products/new/new02308.html>.
  41. Hook, I.; McGee, A. and Henman, M. (1993). Evaluation of dandelion for diuretic and variation in potassium content. *Int. Pharmacol.*, 31(1):29-34.
  42. Edward, P. (2010). List of pediatric ear drops. Mar,<http://WWW.Livstrong.Com/article/97834-pediatric-ear-drops/#ixzz2Bcyqdbdy>.
  43. Canducci, F.; A. Armuzzi, F.; Cremonini, G.; Cammorota, F.; Bactolozzi, P.; Pola, G.;



- Gasbarrini, A. and Gasbarrini, K. (2000). Alyophilized and activatal culture of lactobacillus acidophilus increase Helicobacter pylori eradication rates. *Alment. Pharmacol. Ther.*, 14: 1625-1629.
44. Reid, G.(2001). Probiotic agents to protect the urogenital tract against infection. *Am. J. Clin. Nutr.*, 73:4375-4435.
45. Kwakman, P.H.; Vanden-Akker, J.P.; Boszhardl, P.F.; Middlhoek, P.; Tevelde, A.A.; Vandenbroucke, S.; Grauis, C.M.; Schultz, M.J. and Zaat, S.A. (2008). Medical grade honey kills antibiotic –resistant bacteria invitro and eradicates skin colonization. *Clinic. Infect. Dis.*, 46(11):1677-1682.
46. Forestier, C.; Guelon, D.; Cluytens, V.; Gillart, T.; Sirot, J. and Dechamps, C. (2008). Oral probiotic and prevention of *Pseudomonas aeruginosa* infections: randomized, double -blind, placebo- controlled pilot study in ICU-Patients, 19;12(3):69- 73.
47. Cross, M.L. 2002. Microbes versus microbes: Immune signals generated by probiotic lactobacilli and their role In protection against microbial pathogens. *FEMS Immunol. Med. Microbiol.*, 34:245-253.
48. Grangette, C.; Muller-Alonf, H.; Gouder, D. Court, M.; Geoffroy, C.; Turneer, M. and Mercenier, A. (2001). Mucosal Immune response and protection against tetanus toxin after intranasal immunization with recombinant lactobacillus plantarum infect, *Immune.*, 69:1547-1553.

## دراسة تجريبية لإصابة الأذن الوسطى في الفئران بجرثومة الزوائف الزنجارية وعلاجها بالمستخلص الكحولي المبرد للهندباء مقارنة باستخدام العلاجات الحديثة الأوتوكالم والمعزز الحيوي (بكتريا الحامض اللبني)

نرجس عامر عبد الرزاق الخفاجي

وحدة الأمراض المشتركة - كلية الطب البيطري - جامعة بغداد

### الخلاصة

تمت هذه الدراسة لمعرفة دور النواتج الطبيعية للأعشاب للسيطرة على الجراثيم المقاومة للمضادات الحيوية والتي تشكل خطورة على حياة الإنسان والحيوان كذلك تسلط الدراسة الضوء على قوة فعالية المستخلص النباتي الكحولي المبرد للهندباء كمضاد بكتيري ضد الزوائف الزنجارية، ودراسة وبائية الزوائف الزنجارية كمسبب لالتهاب الأذن الخارجية والوسطى ليس فقط لسلامة الحيوانات المخبرية من الأصابة ولكن للحد من أصابة العاملين. تعتبر الفئران الحيوان الأمثل لدراسة العلاقة مابين المسبب البكتيري والضرر الذي يلحق قناة اوستاكي، كذلك تهدف الدراسة لتحليل بداية ونهاية الأصابة في النسيج في الأذن الداخلية والوسطى للفئران. وتشتمل الدراسة ايضا توصيف قابلية العترة المعزولة وحساسيتها ضد المضادات الحيوية وتباينها مع حساسيتها مع العلاجات البديلة كأستخدام المستخلص النباتي المبرد للهندباء مقارنة بالعلاجات الحديثة لقطرات الأذن (الأوتوكالم) والبكتريا الحيوية المثبطة داخل وخارج الجسم. أشتملت التجربة داخل الجسم على 18 فأرة من كلا الجنسين والتي قسمت عشوائيا الى 6مجاميع (كل مجموعة 3 فئران). حقنت المجاميع الخمسة الأولى بجرثومة الزوائف الزنجارية وبتركيز 106 وحدة تكوين مستعمرة / مل، بينما حقنت المجموعة السادسة (سيطرة سالبة) بمحلول الملح الفوسفاتي المتعادل. قتلت المجموعة الأولى بعد 48 ساعة من الأصابة (سيطرة موجبة) وعوملت المجموعة الثانية بقطرات الأذن (الأوتوكالم) بعد 48 ساعة من الأصابة ولمدة 10 أيام، كما عوملت المجموعة الثالثة بمستخلص الهندباء المبرد، أما المجموعة الرابعة فقد عوملت بالمستخلص النباتي المبرد والمستخدم موضعيا مع تجريع الحيوانات بالمعزز الحيوي البكتيري، في حين أعتبرت المجموعة الخامسة مجموعة سيطرة حيث حقنت بالجرثومة وقتلت في نهاية التجربة. أثبتت النتائج ان المجموعة الرابعة المعاملة بالمستخلص النباتي المبرد للهندباء والمستخدم موضعيا مع تجريع الحيوانات بالبكتريا المثبطة هي الأفضل لتحسس البكتريا في الزجاج وتراجع للنمو في النسيج من غير ظهور واضح للأفة داخل النسيج وزيادة مناعة الحيوان وتحسن صحته وعدم سمية النبات وعدم تداخله مع علاجات اخرى مقارنة مع المعاملات المستخدمة وكدت الدراسة زيادة ضراوة جرثومة الزوائف الزنجارية المعزولة من التهاب الأذن الوسطى مقارنة بنفس الجرثومة المعزولة من اعضاء اخرى لنفس الحيوان.

الكلمات المفتاحية: التهاب الأذن الوسطى، الهندباء، الأوتوكالم، الزوائف الزنجارية .