

Morphological changes of descending testes during postnatal developmental stages in the Rabbit (*Oryctolagus cuniculus*)

Ammar Ismail¹ and Mahdi Abdul kareem Atyia²

¹. Department of Anatomy and Histology, College of Veterinary Medicine, Diyala University

². Department of Anatomy and Histology, College of Veterinary Medicine Baghdad University, Iraq

E-Mail: ammam_histo@yahoo.com

Accepted in: 27/1/2013

Summary

This study was conducted to elucidate the morphological changes of the testis of the domestic rabbit (*Oryctolagus cuniculus*) during the postnatal life. The animals were divided in to seven age groups, eight animals for each group. The age of these groups were (1, 15, 30, 60, 90, 120, and 150 days). The mean weights, volume, length, width, and thickness of both left and right testes were recorded. The positions of testes in all ages were described. The results showed the testes were found at sub lumbar region at one day postnatally, moved and start ingress the inguinal canal at 15 days of age, and mostly located moving in the inguinal canals and near to the developing scrotum between 30 and 60 days. This become completely within the scrotum at 90 days. The testes weight showed sharply increasing at 15 days. Then continued grew gradually, until 90 days of age when the greatest growth rate. After 90 days of life the testicular weight show slower rate of growing to reach adult weight at 150 days.

Keywords: Morphology change, Testis, Postnatal development, Rabbit.

Introduction

The domestic rabbit *Oryctologus cuniculus* has proven to be a valuable animal in biomedical, reproduction research and testing (1) also widely used in Physiology and immunology laboratories (2). The mammalian testes perform two function, the production of male gametes (spermatozoa) by spermatogenesis and male sex hormones (androgens) (3). The male gonads (testes) are present in sublumber region then descent to the semi pendulous scrotum which is located in the inguinal region lateral and ventral to the anus. This descending steps are effected by several factor involve androgen effect (4). The puberty depends on the action of testosterone (5). Thus the aim of this study is to investigate the sequential morphological changes of the descending testis from birth up to the puberty 4-5 months.

Materials and Methods

The animals were maintained at room temperature ($24 \pm 2C$) and in 12:12 = a light: dark regimen (lights off at 19:00 h and on at 07:00 h) (6). The animals were fed with Standard pelleted dry diet, green roughage and tap water ad libium. The date of parturitions and number of kits for each mother (doe) were recorded.

After sexing of animals they are divided into seven groups of male rabbits aged 1, 14, 30, 60, 90, 120 and 150 days (n=8 rabbits per group) 56 animals were used. Each animal was weighed alive and sacrificed by dislocation of cervical vertebrae after anesthesia with chloroform.

A midline incision through the skin and abdominal muscles was made through the septa separated the two scrotal sacs. After removing the intestine, the reproductive tracts with both testes were photoed in all age groups in situ by digital camera (*Sony 12.1 mega pixels*) to describe their shape, location, position and orientation in the abdominal cavity. The left and right testes were removed and, to kept them moist and cools they put in the covered petri dish and weighted, measured separately (length, width, and thickness) and photoed. Volume of the testis was estimated by the water displacement method (7), there is a modification by using insulin syringe as a fin cylinder for the very small specimens like testis at 1 day age. The weight was measured after removed the surrounding connective tissue and fat by using a sensitive electronic balance. The length, width and thick were measured with the help of electrical digital vernier. All data were analyzed using SPSS version 17 (SPSS Inc., Chicago, IL, USA) for Windows. One-way analysis of variance was

used to detect age-related variations. The results are expressed as means \pm SE. The results were regarded as significant at ($P < 0.05$) level.

Results and Discussion

In one day, the male gonads (testes) of neonatal rabbits (kits) are small, oval in shape, with wide cranial pole and narrow caudal pole, and has an epididymis. (Fig. 1). This results are Compatible with the results of (8) in opossum. Each testis and its epididymis is measured together because of difficult separation anatomically between them. The left and right testis with their epididymis have mean weight (0.00396 ± 0.00006 , 0.00297 ± 0.00007 gm) respectively. The left testis is significantly larger than right. This result is differ from that of (9) whom they recorded that both testis of Himalayan rabbit at newborn have the same weight and larger than the weight of testis in the current study. The testes are located at the sublumber (intra-peritonally) region on both sides of the descending colon, about few millimeters caudally to the kidneys. The right testis is lower than the left testis, and the left testis is located about 1.5 mm caudal to the left kidney while the right testis is located about 3 mm caudal to the right kidney. This location in the rabbit is similar to that in guinea pig (10). The peritoneal layer surrounded the testes and connects laterally and cranially with the fascia that surrounding the kidney (cranial suspensory ligament). The gubernaculum is undifferentiated mesenchymal gelatinous structure consider as guidance of the descending testes to the correct site in the scrotum. It's present as a thick cord connects the caudal end of the testis toward and through the inguinal canal. (Fig. 2).

In 15 days the mean testes weights with their epididymis at this age are sharply increased for about 20 folds from the previous age. It is about (0.074 ± 0.0034 gm) of the left testis and (0.069 ± 0.0033 gm) of the right testis table (1). This sharply increased folds of the testis is similar to the results noticed by (11) in the hamster at the same age, the testis is a thin and more elongated, has appearance as a grain of rice (Fig. 3). The testis descends markedly

after released from the kidneys when the cranial suspensory ligaments degenerated. The descending of the tests dependent upon the regress of cranial suspensory ligaments and the tension of gubernaculum, so that by day 15th the testis start ingress the inguinal canal in some kits, (Fig. 4) although in others the testes still lies in the lowest region of retroperitoneum, near the level of bifurcation of the abdominal aorta. In this result the descending of the testes to the inguinal canal in the rabbit are beginning from the 15th day. This is in agreement with (8) in the opossum. But in contrast to the (11) who noticed that the descending of testis in the hamster beginning at 26 days postnatally, and (9) whom they recorded the descending of Himalayan rabbit testis at six weeks).

In 30 days, the gubernaculum become short and swelling, and the distal end of gubernaculum which extended through the inguinal canal to groin. The gubernaculum enlarged rapidly as thick as the testis itself to provide the space into which the testis will be descent in the later through the superficial ring of the inguinal canal. The testes of all animals in this period located intrainguinal canal (Fig. 5). There are rapid increased in the length of testes about double times from the previous age to become more elongated (Fig. 6) (Table, 1), and the mean testes weight of both left and right testis were continuous slightly grew (0.13 ± 0.007 , 0.12 ± 0.0054 gm) respectively.

In 60 days, the testes have little increased in weight and sharply grows in the volume about six times since the previous age of 30 days. The mean testicular weight of left and right testes were (0.18 ± 0.009 , 0.17 ± 0.0098 gm) respectively and the mean volumes of both left and right testis are (1.15 ± 0.032 , 1.19 ± 0.011 gm) respectively (Table, 1).

The testis has elongated shaped, mostly located moving in the inguinal canals and through the inguinal opening near to the developing scrotum and intra-abdominal. The gubernaculum still connected with caudal end of testis the trans-inguinal descending of the testis is androgen dependent (4), (Fig. 7).

In 90 days, the testis was continued to grow at a slower rate, until 90 days of age when observed rapid growth is about seven folds from the previous age. The mean testicular

weight of both left and right testes were (1.23±0.033, 1.22±0.032gm) respectively (Table 1). This observation coincide with (12) in the pig, who observed that the testicular weights were progressively increased during pubertal period. The testis become more bulky and has elongated oval shape. The testes are completely located within the scrotum, but pass easily between scrotum and abdominal cavity through the inguinal canal. These

observations disagreement with the result of (11) who recorded that the testes of hamster were completely descent in the scrotum at 36 days. This differences may be due to variations between species when the time of puberty is differ and high level of androgen at this age, thus lead to presence this difference. The gubernaculum become more short and thick attach the caudal end of testis with the vaginal process. (Fig. 8).

Table, 1: Showing Weights, Volumes, Length, width and thickness of left and right Testes of

| Age Parameters | | 1-day | 15- days | 30- days | 60- days | 90- days | 120- days | 150- days |
|--------------------------------|-------|---------------------|------------------|-----------------|----------------|------------------|------------------|------------------|
| Body weight (gm) | | 35.68 ± 0.47 g | 137.13 ±3.13 f | ±7359.13 .75 e | 528.38 ±6.66 d | ± 874.25 31.49 c | ±1218.50 18.86 B | 1555.75±4 0.86 a |
| Testis weight (gm) | Left | 003960. ±0.00006 ed | ±0.0740. 0034 d | 0. 13±0.007 cd | 0.18±0.0 09 c | ±0.01.23 33 b | ±0.02.30 47 A | 2.34±0.045 a |
| Testis weight (gm) | Right | 0.00297 ±0.00007 e | 0.069±0. 0033 de | 0.12±0.0 054 cd | 0.17±0.0 098 c | 1.22±0.0 32 b | 2.25±0.0 51 A | 2.32±0.049 a |
| Testis volume(mm) ³ | Left | 0.0034± 0.00018 e | 0.088±0. 006 e | 0.205±0. 007 d | 1.15±0.0 32 c | 1.21±0.0 31 c | 1.48±0.0 56 B | 2.15±0.035 a |
| Testis volume(mm) ³ | Right | 0.0030± 0.00015 e | 0.084±0. 007 e | 0.194±0. 023 d | 1.19±0.0 11 c | 1.17±0.0 34 c | 1.46±0.0 59 B | 2.12±0.036 a |
| Testis Length (mm) | Left | ±0.02.80 12 g | ±0.05.95 16 f | ±0.11.20 019 e | ±0.12.75 042 d | ±0.16.51 16 c | ±0.24.88 10 b | 27.39±0.04 8 a |
| Testis Length (mm) | Right | 0.±2.797 170 g | ±0.05.89 34 f | ±0.10.97 113 e | ±0.12.75 115 d | ±0.16.04 14 c | z±024.70 .13 b | 27.31±0.06 8 a |
| Testis Width (mm) | Left | ±0.01.55 06 g | ±0.02.01 10 f | ±0.03.55 39 e | ±0.04.32 56 d | ±0.08.25 52 b | ±0.10.54 029 a | 8.06±0.032 c |
| Testis width (mm) | Right | ±0.01.55 066 f | ±0.02.07 078 e | ±0.03.49 43 d | ±0.04.23 67 c | ±0.08.20 64 b | ±0.10.33 17 a | 8.04±0.033 b |
| Testis Thick (mm) | Left | ±0.01.36 056 f | ±0.01.84 23 e | ±0.04.01 43 d | ±0.04.87 79 c | ±0.028.1 9 b | ±0.09.65 63 a | 9.72±0.087 a |
| Testis Thick(mm) | Right | ±0.01.34 046 f | ±0.01.81 32 e | ±0.04.03 5 d | ±0.04.76 93 c | 8.03±0.0 36 b | ±0.19.75 5 a | 9.65±0.078 a |

rabbit in different days of postnatal life.

In 120 days, with advancing age progress the tests are oval shape and slightly wider in the cranial portion and pointed in the caudal portion, (Fig. 9). The testis tends to be located

under the skin of semi-pendulous scrotum, nearly horizontal position. This result is in agreed with the result of (13) in bonnet monkey. All the parameters are increased from

the previous age especially the length which increased about 1.5 folds from the previous age to become about (24.88±0.10 mm) in left testis and about (24.70±0.13 mm) the right testis (Table, 1).

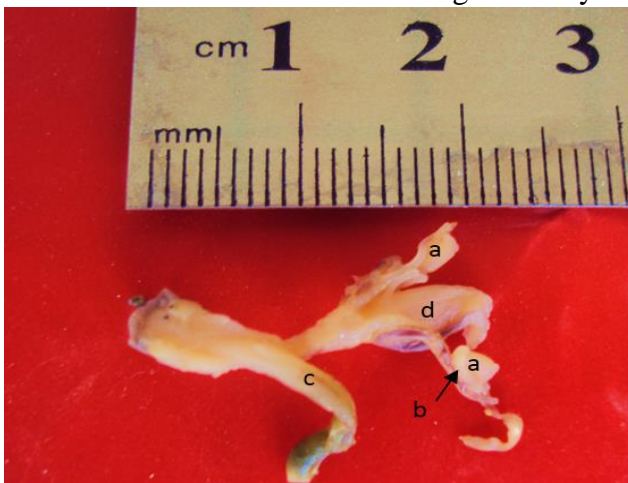
In 150 days the testis has an elongated oval shape with wide round cranial end and pointed caudal end, (Fig. 10). The average testicular weight of left and right testes are (2.34±0.045, 2.32±0.049 gm) respectively.

The mean of the testis weight after 90 days of age show slower rate of growing to reach adult weight. The mean testicular weight at this age is identical to the result of (14) in New Zealand rabbit. The testis is large usually

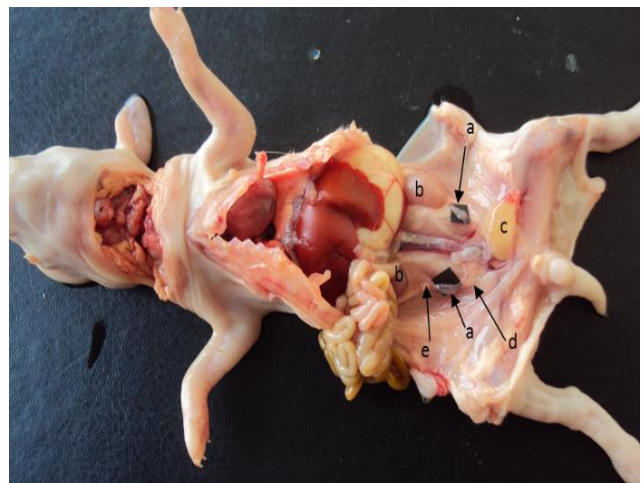
confined to scrotal sacs, have mean volume (2.15±0.035, 2.12±0.036mm³) (Table, 1).

The testes are located in the midline just ventral to the anus and above the external genitalia suspended laterally to them, (Fig. 11). The perineal position of the testis in the rabbit is similar to the location reported by (15) in camel. The testis remains connected from the caudal end to the scrotum by gubernaculum.

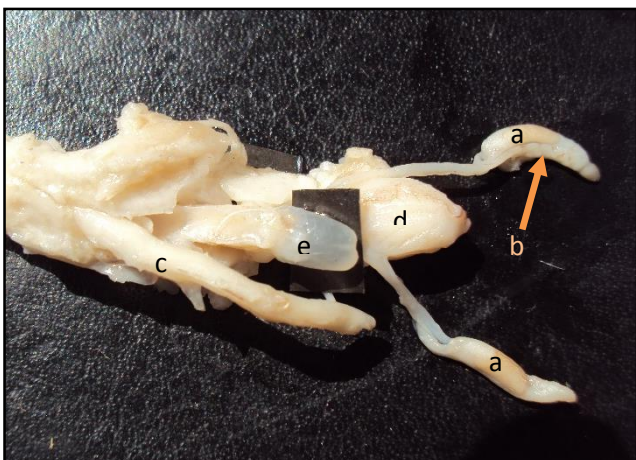
The right testis is slightly smaller than left testis in all age group but not significantly except at 1 day and 15 days of age the right testis is significantly smaller than the left testis (Table, 1).



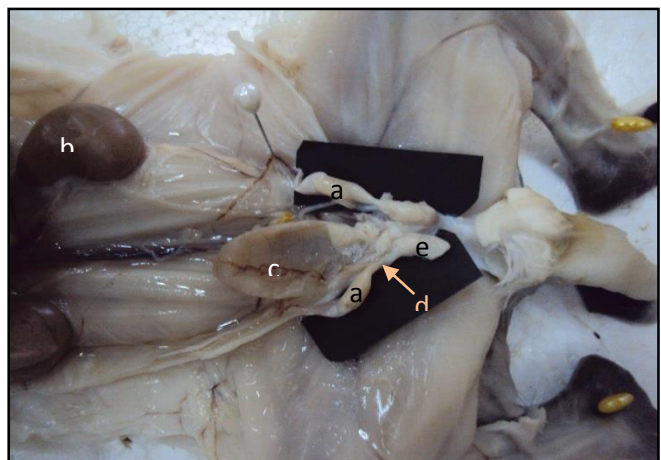
Figure, 1: Urogenital system of the Kit rabbit at 1-day age, shows the shape of the testes and epididymis a- testis b- epididymis c- rectum d- urinary bladder.



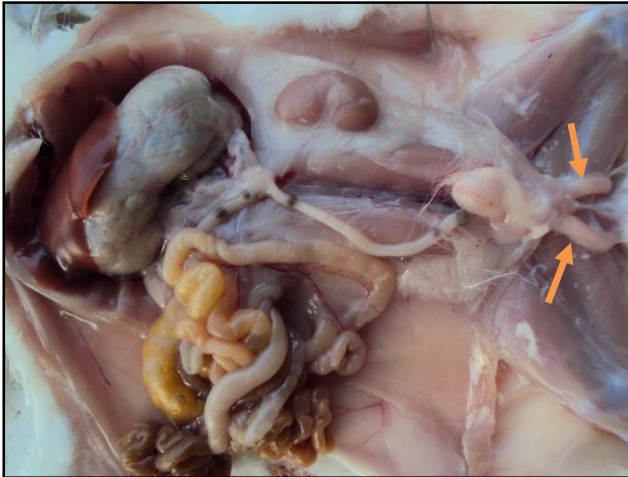Figure, 2: shows the shape and position of testis in situ in the Kit rabbit at 1- day age a- testis b- kidney c- urinary bladder d- gubernaculum e- cranial suspensory lig.



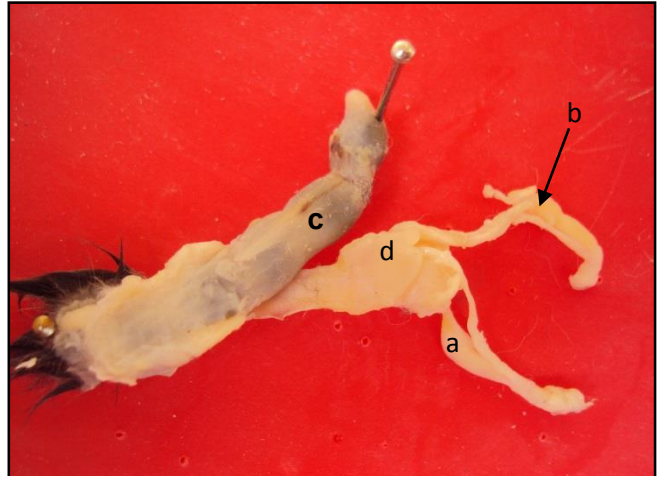
Figure, 3: Urogenital system of the Kit rabbit at 15- days age, shows the shape of the testes and epididymis a- testis b- epididymid c- rectum d- urinary bladder e- seminal vesicle gland.



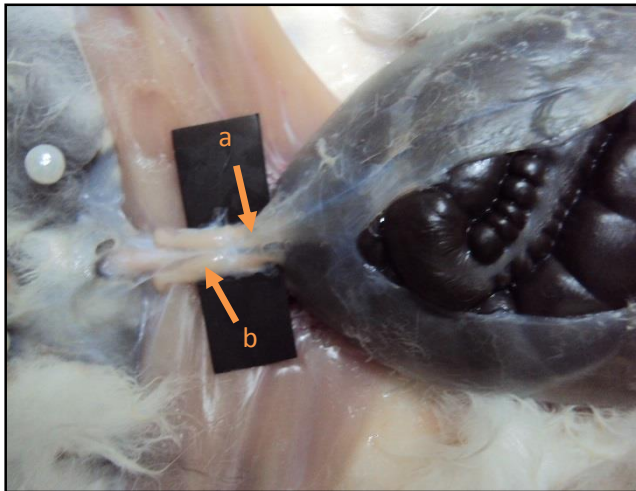
Figure, 4: Show the shape and topographic position of the testes in situ of kit rabbit at 15 days age a- testis b- kidney c- urinary bladder g- gubernaculum e- part of inguinal canal.



Figure, 5: Shows topographic location of the testes at 30 days old rabbit kits descent to intra-inguinal canals.



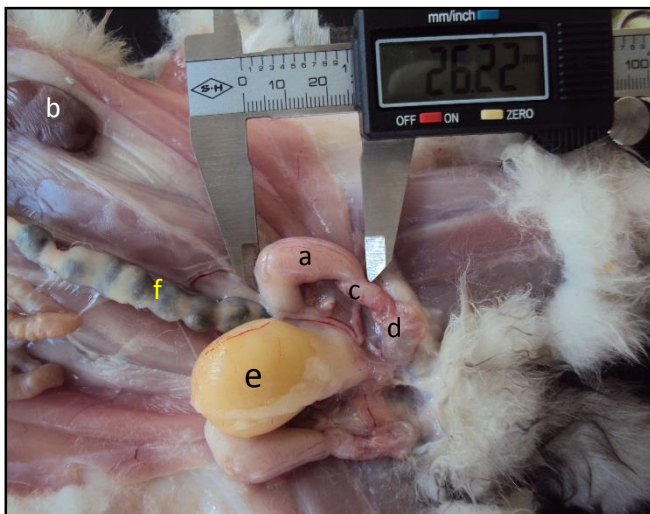Figure, 6: Reproductive organs of the Kit rabbit at 30-days age, shows the shape of the testes a-testis b-epididymisc- rectum d- seminal vesicle gland.



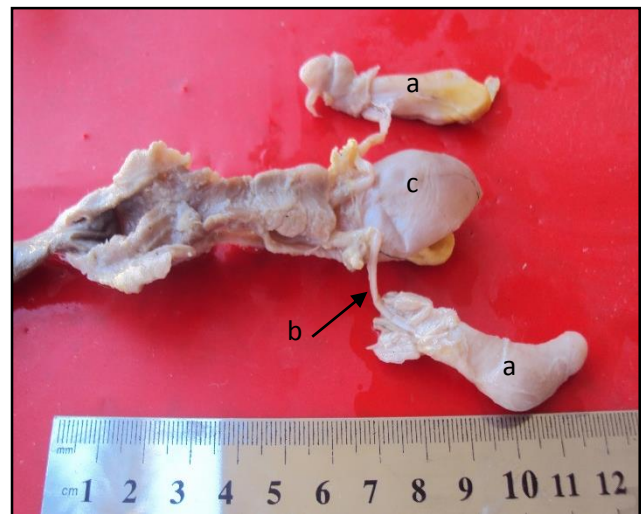
Figure, 7: Shows the testes position of 60 days olds rabbit intra-inguinal canals a- Wall of inguinal canal b- testis.



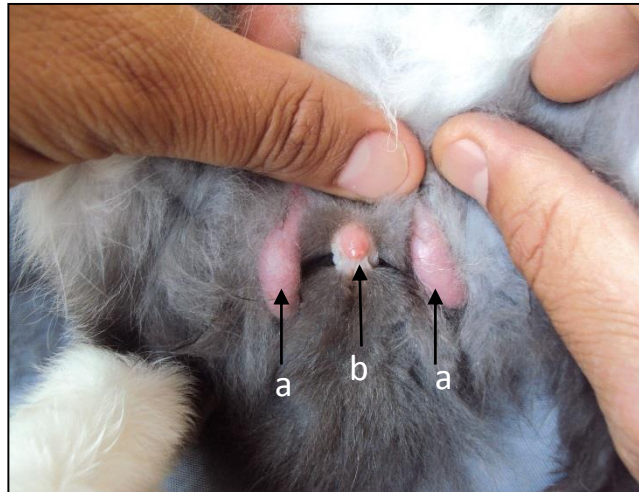
Figure, 8: Shows the shape, size and position of testis in situ in the rabbit at 90- days age a-testis b- kidney c-ligament of the tail of epididymis d- part of inguinal canal.



Figure, 9: Shows the shape, size and topographic position of testis in situ of the rabbit at 120- days age a-testis b- kidney c-ligament of the tail of epididymis d- part of inguinal canal e-urinary bladder f- rectum.



Figure, 10: Reproductive organs of the Buck rabbit at 150 days age, shows the Shape of the testes a- testis b-Ductus deferens c- urinary bladder.



Figure, 11: Shows the perineal position of the testes in semi-pendulous scrotal sacs in the buck rabbit at 150 days old a- testis b- penis.

References

1. Suckow, M.A., and Schroeder, V. (2010). The laboratory Rabbit. 2nd edition, CRC press, Taylor and Francis group. PP:1-2.
2. Mclaughlin, C.A. and Chiasson, R.B. (1990). Laboratory anatomy of the Rabbit. 3rd ed., McGraw-hill USA, PP:80-83.
3. Lodhe, L.A. and Qureshi, Z.I. (2000). The bovine testis –Pre and post natal development Pakistan J. Biol. Sci., 3(10):1691-1696.
4. Hyttel, P.; Sinowatz, F.; Vejlsted, M. and Betteridge, K. (2010). PP:261-267. Essential of domestic animal embryology. Saunders, Elsevier, USA.
5. Castro, A.C.; Berndtson, W.E. and Cardoso, F.M. (2002). Plasma and testicular testosterone levels, volume density and number of Leydig cells and spermatogenic efficiency of rabbits. Brazilian J. Med. Biol. Res., 35:493-498.
6. Dorostghoal, M.; Sorooshnia, F. and Zardkaf, A. (2011). Stereological analysis of Wistar Rat testis during early Post-natal development. Anat. Histol. Embryol., 40: 89–94.
7. Elias, H., and Hyde, H. (1980). An elementary introduction to stereology. Am. J. Anat., 159:411–446.
8. Mackay, S.; Xie, Q.; Ullmann, S.L. Gilmore, D.P. and Payne, A.P. (2004). Postnatal development of the reproductive system in the grey short-tailed opossum, *Monodelphis domestica*. Anat. Embryol., 208:121–133.
9. Tsunenari, I. and Kast, A. (1992). Developmental and regressive changes in the testes of the Himalayan rabbit. Lab. Ani., 26:167-179.
10. Al-Zubaidiy, K.A. (2012). Anatomical and Histological study of Pituitary gland and Testis in Fetal, Newborn and dult Guinea pig (*cavia porcellus*). PhD Thesis, College Veterinary Medicine. University of Baghdad, PP:78-79.
11. Ortiz, E. (1947). Postnatal Development of the Reproductive System of the Golden Hamster (*Cricetusauratus*) and Its Reactivity to Hormones. Physiol. Zool., 20:45-66.
12. Franca, L.R.; Valdemiro, A.; Silva, V.A.; Garcia, H.C.; Garcia, S.K. and Luciano Debeljuk, L. (2000). Cell proliferation and hormonal changes during postnatal development of the testis in the Pig. Biol. Reprod., 63:1629–1636.
13. Prakash, S.E.; Prithiviraj, E. and Suresh, S. (2008). Developmental changes of seminiferous tubule in prenatal, postnatal and adult testis of Bonnet Monkey (*Macaca radiata*) Anat. Histol. Embryol., 37:19–23.
14. Thompson, T.L. and Berndtson, W.E. (1993). Testicular Weight, Sertoli Cell Number, Daily Sperm Production, and Sperm output of sexually mature rabbits after Neonatal or Prepubertal

Hemicastration. Biol. of reprod., 48:952-957.

epididymis of camels (*Camelus dromedaries*). Acta. anat., 101:275-279.

15. Singh, U.B. and Bharadwaj, M.B. (1978). Morphological changes in the testis and

التغيرات الشكلية للخصى اثناء النزول خلال المرحلة التطورية بعد الولادة في الارانب (*Oryctolagus cuniculus*)

عمار اسماعيل جبار¹ ومهدي عبد الكريم عطية²

¹ فرع التشريح والانسجة - كلية الطب البيطري - جامعة ديالى² فرع التشريح والانسجة - كلية الطب البيطري - جامعة بغداد - العراق

الخلاصة

اجريت الدراسة الحالية لتبيان الضوء على التغيرات الشكلية لخصى الارانب المحلية خلال فترة ما بعد الولادة. قسمت الحيوانات إلى سبع مجاميع عمرية (1 و 15 و 30 و 60 و 90 و 120 و 150) يوماً من العمر وبواقع ثمانية حيوانات لكل مجموعة. تم تسجيل معدل الوزن والحجم والطول والعرض، والسماك لكل من الخصيتين اليمنى واليسرى. وتم وصف موقع الخصيتين في جميع الأعمار. أظهرت النتائج ان الخصيتين في عمر يوم واحد بعد الولادة تقعان في المنطقة تحت القطنية، ثم تتحرك بعد ذلك لتشرع بالنزول الى القناة الأربية بعد 15 يوماً من العمر، وغالبا ما توجد متحركة في القنوات الأربية وبالقرب من كيس الصفن النامي في عمر ما بين 30 و 60 يوماً، ويكتمل نزولها داخل كيس الصفن عند العمر 90 يوماً. وظهر وزن الخصيتين زيادة حادة في يوم 15، ثم واصلت النمو تدريجياً، حتى اليوم 90 من العمر حيث اظهر اعظم معدل زيادة وزنية. بعد 90 يوماً من العمر اظهر معدل وزن الخصية تباطؤ في النمو للوصول إلى الوزن البالغ عند عمر 150 يوماً.

الكلمات المفتاحية : التغيرات الشكلية , الخصى, المرحلة التطورية بعد الولادة, الارانب.