

Diagnosis of *Eimeria* spp. in *Capra ibex* (local meriz goat)Saad M Al-Bayati¹, Adnan M Al-Rekani² and Ahmed A Hamed²¹Duhok Technical Institute, Polytechnique University of Duhok, ²Faculty of Agriculture, Duhok University, Iraq.E-mail: bayati196459@gmail.com

Accepted: 1/6/2015

Summary

Out of 77 of local meriz goats (*Capra ibex*), 29 (37.67%) were diagnosed as infected with coccidia. The infection percentage was 22.08% in kids less than six months of age as compared with older age (15.59%). A moderate diarrhea was the only clinical sign which was observed in three infected kids (3.9%). Six *Eimeria* (*E.*) species were diagnosed, they were *E.alijevi*, *E.christenseni*, *E.caprovina*, *E.minasensis*, *E.megaembryonica*, *E.ninakohlyakimovae*. *E.megaembryonica* was suggested to be a new species as it has a bigger embryonic mass which could be depended as a new parameter for coccidia classification. The germinal disk with two layers was very clear and observed in pre-sporulation Oocyst of most diagnosed species. The last three criteria are new in their mentioning. Also, Pot. Dichromate with 5% concentration is essential for follow-up of sporulation process to prevent of high bio - pollutants of fecal samples but without any effects upon biological features of isolated coccidia species.

Keywords: *Eimeria*, coccidia, Meriz goats.**Introduction**

Capra ibex (var *Kurdistani*) occur throughout Kurdistan, especially in mountains and valleys where they are in sometimes domesticated for local purposes. The public name is Meriz goats which are found along the northern border region of Iraq. This breed is hardy and is mainly raised for its fine fibers (1). Meriz was studied previously for the presence of some parasites (2) but not for coccidial infection. The number of *Eimeria* spp. (coccidia parasites) which were considered as a parasite for domestic goats are variable and controversial, also depend upon the acceptance of validity of some species (3) but may reach 17 species (4-8). Goat's coccidiosis have many epidemiological and economical aspects according to species' diversity and seasonal appearance which reflexes the prevalence and distribution of the disease's infection rate (3 and 4). Coccidiosis of small ruminants have host specification and cause sporadic clinical cases but most infection was chronic and undiagnosed. Economic losses of coccidiosis might be related to the high rate of mortality in kids, poor growth, environmental pollution with coccidian Oocysts and the cost of anticoccidial medicates (4 and 5). Current paper aimed at investigation the presence of Coccidiosis in local meriz (*Capra ibex*) for the first time in Duhok area and detailing their feature, as well

as some epidemiological categories will be investigate.

Materials and Methods

Fecal samples of 77 of local meriz (37 < 6 months and 40 > 6 months) were collected directly from the rectum, for the diagnosis of infection with coccidia protozoal parasite (*Eimeria* spp.). Samples weight were about 10-20 g, collected individually and transferred to the clinical pathology laboratory of Animal Production dept. for successive investigation. Direct smear, flotation in saturated salt solution, and culturing with 2.5% and 5% Pot. Dichromate (wt./vol.) Methods at room temperature are used for the diagnosis and classification of various *Eimeria* spp. (9). Photomicrograph, micrometer microscopy, and parasitology lab- wares were used. Statistical analysis was done with ANOVA, Chi square and other descriptive statistic methods have been used.

Results and Discussion

Eimeria spp. in local meriz (*Capra ibex*) were diagnosed by observation of undeveloped Oocysts and fully mature one that contains 4 sporocysts with various diagnostic methods. In a relation to the infection rate, kids (<6 months) show high infected rate (17/77 = 22.08%) as compared to others that they were over 6 months age (12/77 = 15.59%) with total

infection rate of about 29/77 (37.67%) as a cross sectional study results (Table, 1). The relationship between infection and clinical signs occurred only in 3 (3.9%) which were suffering from moderate diarrhea and only in small age (≤ 6 months) animal while the rest had normal fecal formation (Table, 1). Patent period was 55-56 to 56-58 days with no differences to the age of infected animals. Sporulation time was reach 7-10 days among diagnosed species depending on 5% Pot. Dichromate (Table, 2). Six *Eimeria* spp. were recognized among infected animal with sporadic or mixed infection. The measurement (in Micrometer - μm) of these species were differentiated according to dependent taxonomy kit (9), they are arranged in 16.03-15.03 (± 0.55) μm for Oocyte, 0.42 \pm 0.09 μm for Embryonic mass area to L \times W ratio, unclear germinal disk was observed in pre sporulation Oocyst, 4 sporocysts are present with 7 \times 8 μm in there measurement with no polar cup neither micropyle for the Oocyst, sporulation time was 7-10 \pm 2 days at room temperature. The suspected diagnosis is *Eimeria* (*E.*) *alijevi* (Fig. 1- A and B). The second suspected species was *E. christensenii* (Fig. 2- A and B) with measurement of 24.04 - 36.07 (± 1.61) μm for Oocyst, and 0.18 \pm 0.08 μm for embryonic mass area to L \times W ratio, clear germinal disk with clear Outer 1.6 \times 2.08 \pm 0.25 and Inner 0.83-1.25 \pm 0.25 μm layers was observed in pre sporulation Oocyst, 4 sporocysts are present with 7 \times 11 μm in there measurement, with polar cup and micropyle for the Oocyst. The sporulation time was 7-10 \pm 2 days at room temperature. The third suspected species was *E. caprovina* (Fig. 3- A and B) with measurement of 26.45-31.26 (± 2.41) μm for Oocyst, and 0.18 \pm 0.08 μm for embryonic mass area to L \times W ratio, clear germinal disk and clear outer 1.6 \times 2.08 \pm 0.25

and Inner 0.83-1.25 \pm 0.25 μm layers were observed in pre sporulation Oocyst, 4 sporocysts are present with 8 \times 10 μm in there measurement with no polar cup but micropyle. The sporulation time was 7-10 \pm 2 days at room temperature.

The fourth suspected species was *E. minasensis* (Fig. 4-A) with measurement of 28.86 -40.88 (± 1.89) μm for Oocyst, and 0.18 \pm 0.09 μm for embryonic mass area to L \times W ratio, clear germinal disk with clear outer 1.6 \times 2.08 \pm 0.25 and inner 0.83-1.25 \pm 0.25 μm layers was observed in pre sporulation Oocyst, sporocysts measurement were not followed up. There was no polar cup but micropyle clear in the Oocyst. The sporulation time was not detected. The fifth suspected species was *E. megaembryonica* (Fig. 4-B) with measurement of 33.67 - 40.88 (± 0.92) μm for Oocyst, 0.67 \pm 0.07 μm for embryonic mass area to L \times W ratio, clear germinal disk with clear outer 1.6 \times 2.08 \pm 0.25 and inner 0.83-1.25 \pm 0.25 μm layers were observed in pre sporulation Oocyst. Sporocysts measurement were not followed up. There was no polar cup but micropyle clear in the Oocyst. The sporulation time was not detected. The sixth suspected species was *E. ninakohlyakimovae* (Fig. 4-C) with measurement of 14.34-19.24 (± 1.44) μm for Oocyst, and 0.39 \pm 0.09 μm for embryonic mass area to L \times W ratio, clear germinal disk with clear outer 1.6 \times 2.08 \pm 0.25 and inner 0.83-1.25 \pm 0.25 μm layers were observed in pre sporulation Oocyst. Sporocysts measurement were not followed up. There was no polar cup but micropyle clear in the Oocyst. The sporulation time was not detected. In a comparison with diagnostic methods (Table, 3), direct culturing with 5% Pot. Dichromate and saturated salt solution were more sensitive (P=0.001) than direct wet smear preparation or culturing with 2.5 % Pot. Dichromate.

Table, 1: Eimeriosis infection rate of local meriz (*Capra ibex*) goats.

Animal age (month)	Number of animal	Infection rate			Patent period (days)
		With clinic. Signs	Without clinic. Signs	Total	
≤ 6 months	37	3 (3.9%)	14	17 (22.08%)	20
≥ 6 months	40	-	12	12 (15.59%)	28
Total	77			29 (37.67%)	48

Table, 2: Characteristics features of *Eimeria* spp. isolated from local meriz (*Capra ibex*) goats.

Species number	Measurement* ($\bar{Y} \pm SE$)	Embryonic mass area/ L x W ratio	Germinal disk occurrence and measurement	Examined Oocysts	Sporocysts Number (Measurement)*	Polar cup	Micropyle	Sporulation time (days at room temp.)**	Suspected diagnosis
1	16.03-15.03 (± 0.55)	0.42 \pm 0.09	NC	100	4(7x8)	-	-	7-10 \pm 2	<i>Eimeria alijeivi</i> (Fig. 1- A and B)
2	24.04 -36.07 (± 1.61)	0.18 \pm 0.08	Clear Outer 1.6x2.08 \pm 0.25 Inner 0.83-1.25 \pm 0.25	100	4(7x11)	+	+	=	<i>E. christensenii</i> (Fig. 2- A and B)
3	26.45-31.26 (± 2.41)	0.23 \pm 0.08	=	100	4(8x10)	-	+	=	<i>E. caprovina</i> (Fig. 3- A and B)
4	28.86 -40.88 (± 1.89)	0.18 \pm 0.09	=	100	NA	+	+	NA	<i>E. minasensis</i> (Fig. 4-A)
5	33.67 -40.88 (± 0.92)	0.67 \pm 0.07	=	100	NA	-	+	NA	<i>E. megaembryonica?</i> (Fig. 4-B)
6	14.34-19.24 (± 1.44)	0.39 \pm 0.09	=	100	NA	-	+	NA	<i>E. ninakohly akimovae</i> (Fig. 4-C)

* In Micrometer ** Manual agitation NA= Not available L/W=Length/Wide NC=Not clear

Table, 3: Sensitivity rate of various diagnostic methods that are used for the diagnosis of *Eimeria* spp infection in local meriz (*Capra ibex*) goats.

Diagnostic methods	Infection rate		Sensitivity rate	Note
	+	-		
Direct wet smear preparation	4	25	13.8%	Repeated is essential
Saturated salt solution	27	2	93.1%***	Dry soon and massive flake were seen
Culturing with 2.5 % Pot. Dichromate	10	19	34.5%	Massive fungal growth was observed
Culturing with 5 % Pot. Dichromate	29	zero	100%***	Directly or after floatation

P***=0.001

The Infection rate of local meriz (*Capra ibex*) coccidiosis reached 37.6% which was less than which has been recorded in other goat species like that of Poland (10), Iran (11), Spain (12), Turkey (13 and 14), Pakistan (15), Jordan (16) and Czech (17) as well as for adult (15.6%) is lesser than others (16 and 18). These variation in infection rate might be related to host-parasite relationship as *Capra ibex* is a wild species and sometime used as a semi domesticated animal, and also the hot climate of the area might be prevent the higher infection rate from rising. This conditions were stated in previous studies (13 and 14). In relation with clinical signs, diarrhea was the most observed sign in adequate with (19 and 20). Sporulation time was 7-10 days which resembled the most of other studies (8 and 14) and that might be related to essential temperature and humidity. Six species of coccidia were diagnosed in current study according to available diagnosis key (5, 7, 9, 12, 13 and 21) .The infection was mixed in all

cases but number of species in each case was not determined. These mixed infection occurrence might be attributed to free feeding style of *Capra ibex* which was dependent on the geographical area of this work. The mixed infection has been observed in (13, 14, 17, 22 and 23) which were dealing with the same subject. A suggestion of new species in *Capra* goat should be expected and putting it in mind, because of the nature of the studied animal and the measures of the Oocyst. The suggested species name was *E. megaembryonica* (Fig. 4-B) because of higher (0.67 \pm 0.07 μ m) embryonic mass area to L \times W ratio. This species needs more conformational studies. Also the relationship between Oocyst total size and embryonic mass could be used in classification of different species and that what was observed in the current study for the first time. This subject depend on two dimensional measurements as by multiplying length and wide of a particular Oocyst and the circular area rule for the embryonic mass area.

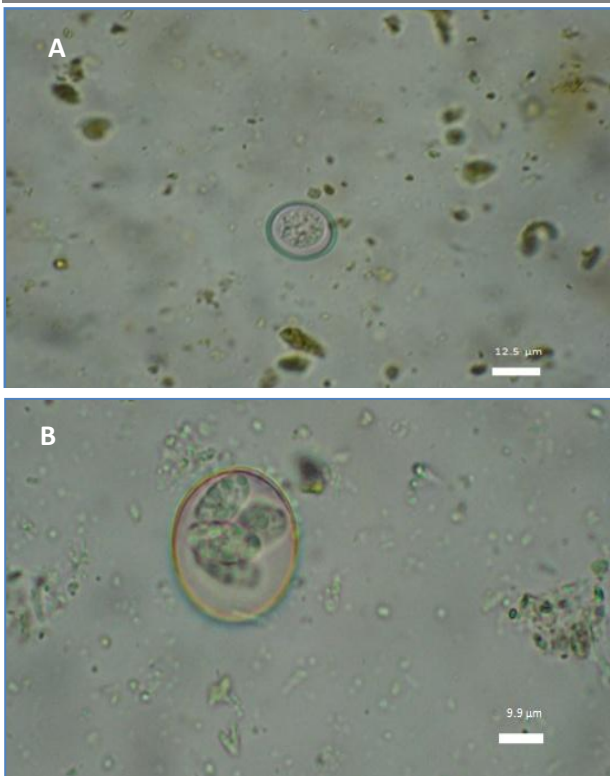


Figure 1: *Eimeria alijeivi*, round Oocyst with no micropyle or cup (A) with four elongated sporocysts in full sporulated Oocyst (B) by saturated salt solution (X100).

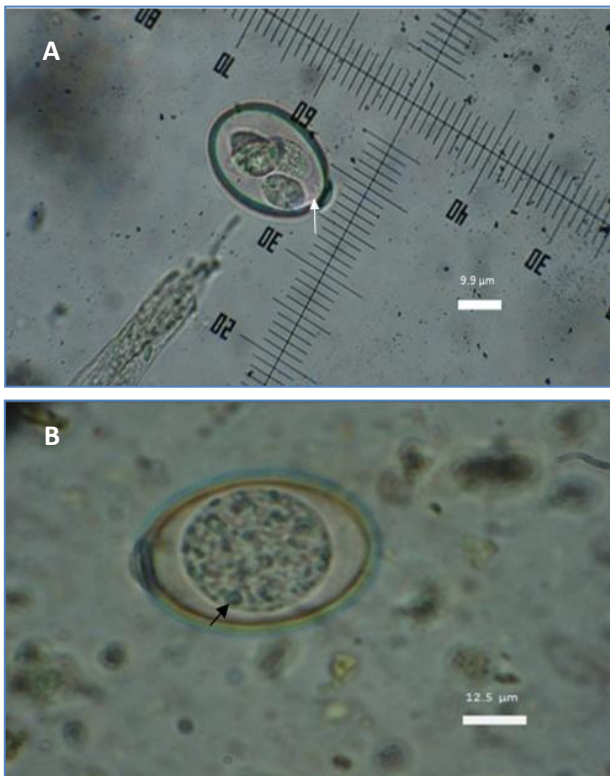


Figure 2: *Eimeria christenseni*, oval Oocyst with micropyle (white arrow) and cup (A) with four elongated sporocysts in full sporulated Oocyst and the germinal disk (black arrow) clear (B) with outer and inner layer by saturated salt solution (X100).

Other methods related to three dimension technology might be more conventional as stereoscopy facilities. Another criteria is the observation of germinal disk which was composed from two parts outer and inner. The outer was clear and transparent while the inner was gray and condense with fixed dimensions in allover detected species. This foundation mentioned for the first time for coccidia and needs more investigation with advanced laboratory technique like Electron microscopy. Finally, it should be mentioned that current study showed that saturated salt solution and 5% Pot. Dichromate were better for diagnosis, clear sporulation as compared with others especially for preventing of bio- pollutants with higher efficiency at least for using of animal fecal samples and that contra versa to others (4, 8, 13 and 14).

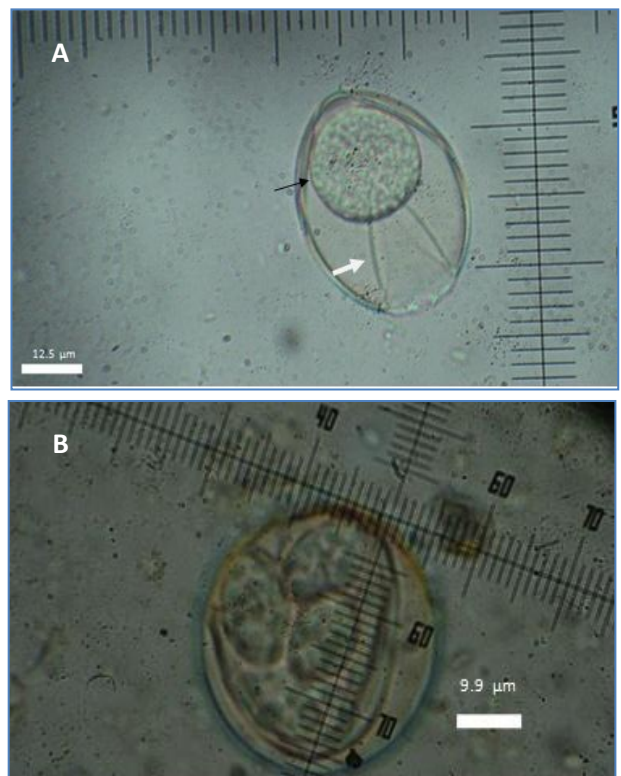


Figure 3: *Eimeria caprovina* oval Oocyst with micropyle (white arrow) and no cup (A) with clear germinal disk (black arrow) with outer and inner layer as well as four elongated fat sporocysts (B) were observed by saturated salt solution (X100).

Using of high Pot. Dichromate concentration 5% did not inhibit the development of Oocysts sporulation or prolonged needed time in this study. This could be considered as a biological variation or more reliable technique for both of these

species of coccidia and might be the fecal sample properties of *Capra ibex* spp. The biological pollutants which are related with this might be not related to other things rather than they were grown in high rate on hot climate even with using of incubator or other material, and that what was clearly observed within current study.

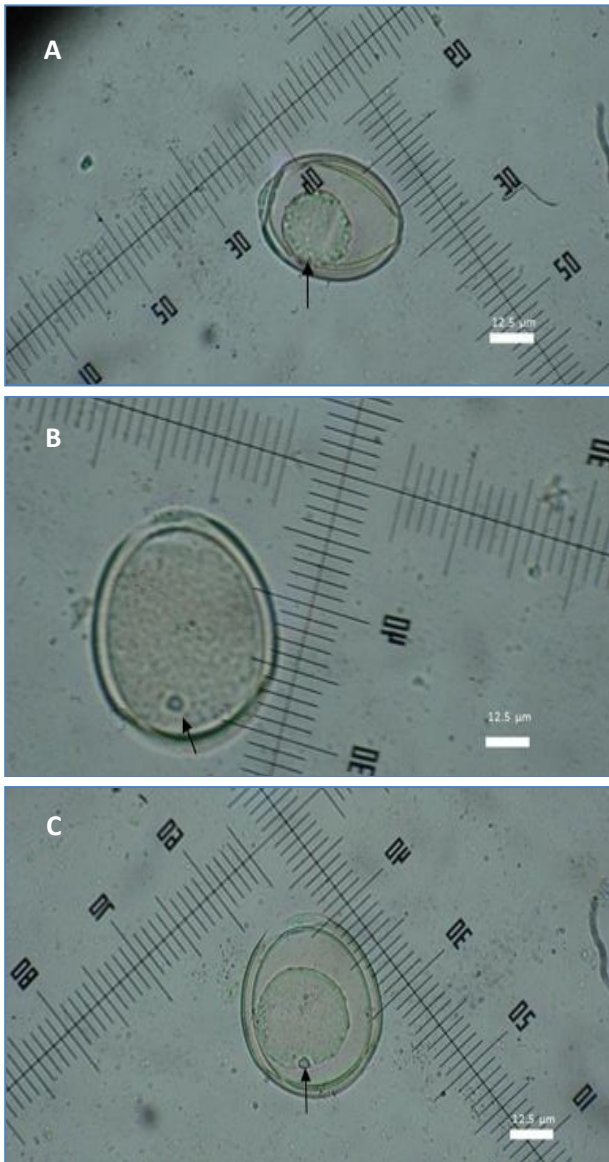


Figure 4: *Eimeria minasensis* (A), with cup and micropyle, *E. megaembryonia* (B) with no cup but micropyle and *E. ninakohlyakimovae* (C) with no cup but micropyle, all species have clear germinal disk with outer and inner layer by saturated salt solution (X100).

In conclusion, Local meriz goats infected seriously with many species of coccidia which in some faces gain special characters. This might be include new species, new variation and new diagnostic modification. All these aspects need more research and attention as these animal mainly stay wild and might be

affect some epidemiological directions especially in a relation to local goat's species which are bred dominantly in this area and for the occurrence of coccidiosis.

Acknowledgments: Many thanks for Animal production department laboratory staff for their generous and kind help for finishing this research.

References

1. Alkass, J. and Merkhan, K. (2013). Meriz goat in Kurdistan region/Iraq: A Review, *Adv. J. Agric. Res.*, 1(7): 105-111.
2. Al-Nakshabandi, A. and Al-Bayati, S. (2007). Mixed parasitic infection on native mountain goats (Big Horne goats) of Dohuk area, *Bas. J. Vet. Res.*, 6(2):138-145.
3. Levine, N. and Ivens, V. (1970). The Coccidian Parasites (Protozoa, Sporozoa) of Ruminants, Illinois Biological Monographs 44, University of Illinois Press, Urbana.
4. Levine, N. and Ivens, V. (1986). The Coccidian Parasites (Protozoa, Apicomplexa) of Artiodactyla. Illinois Biological Monographs 55; University of Illinois Press, Urbana and Chicago. Pp: 121-128.
5. Levine, N. (1985). *Veterinary Protozoology*. Iowa State University Press, Ames, 1985; Pp: 367- 278.
6. Levine, N. D. (1988). *The Protozoan Phylum Apicomplexa*, Vol. II, CRC Press Inc., Boca Raton.
7. Soe, A. and Pomroy, W. (1992). New species of *Eimeria* (Apicomplexa: Eimeriidae) from the domesticated goat *Capra hircus* in New Zealand, *Syst. Parasitol.* 23:195-202.
8. Soe, A. and Pomroy, W. (1992). *Eimeria menasensis* n. sp. (Apicomplexa: Eimeriidae) in the domestic goats *Capra hircus* from Brazil. *Mem inst Oswaldo Cruz*, Rio de Janeiro, 93(6):741-744.
9. Eckert, J.; Braun, R. and Shirley, M. (1995). Coudert P, Guidelines on techniques in coccidiosis research, EUR 16602 en.
10. Balicka-Ramisz, A.; Ramisz, A.; Vovk, A. S. and Snitynskyj, V. (2012). Prevalence of coccidia infection in goats in Western Pomerania (Poland) and West Ukraine region, *Ann. Parasit.*, 58(3): 167-171.
11. Radfar, M.; Sakhaee, E.; Shamsaddini, B. and Haj, M. (2011). Study on gastrointestinal

- parasitic infections of Raeini goats, Iranian J. Vet. Res. Shiraz Uni., 12(1): 76-80.
12. Ruiz, A.; Gonzales, J.; E Rodriguez, E.; Marti, S. and Molina, J. (2006). Influence of climatic and management factors on *Eimeria* infection in goats from semi-arid zones. J. Vet. Med., 53: 399-402.
 13. Deuer, S.; Abdurrahman, G.; Ayaz, E. and Kamile, B. (2003). The Prevalence of *Eimeria* Species in Goats in Van. Turk. J. Vet. Anim. Sci., 27: 439-442.
 14. Gul, A. (2007). The Prevalence of *Eimeria* Species in Goats in Igdır. Turk. J. Vet. Anim. Sci., 31(6): 411-414.
 15. Rehman, T.; Khan, M.; Khan, I. and Ahmad, M. (2011). Epidemiology and economic benefits of treating goat coccidiosis. Pak. Vet. J., 31(3): 227-230.
 16. Mahmoud, N. and Hossam, A. (2003). Prevalence of *Eimeria* species among goats in northern Jordan. Small Rum. Res., 49: 109-113.
 17. Strnadová, P.; Svobodová, V. and Vernerová, E. (2008). Protozoal infections in lambs and kids from farms in the Czech Republic. Veterinářství, 58: 451-454 (in Czech).
 18. Strnadová, P.; Svobodová, V. and Vernerová, E. (2008). Effect of inorganic and organic zinc supplementation on coccidial infections in goat kids, Acta. Vet. Brno., 80: 131-137.
 19. Bakunzi, F.; Thwane, S.; L Motsei, L. and Dzoma, L. (2010). Diversity and seasonal occurrence of *Eimeria* species in a mixed flock of communally reared sheep and goats in Mafikeng in the North West Province, South Africa. Tydskr. S. Afr. Vet. Ver., 81(3): 148-150.
 20. Bandyopadhyay, P. K. (2004). A new coccidium *Eimeria sundarbaensis* n. sp. (Protozoa: Apicomplexa: Sporozoa) from *Capra hircus* (Mammalia: Artiodactyla). Parasito., 3(4): 223-225.
 21. Silva, A. and Lima, J. (1998). *Eimeria minasensis* n. sp. (Apicomplexa: Eimeriidae) in the Domestic Goat *Capra hircus*, from Brazil, Mem Inst Oswaldo Cruz, Rio de Janeiro, 93(6): 741-744.
 22. Chhabra, R. and Pandey, V. (1991). Coccidia of goats in Zimbabwe. Vet. Parasitol., 39: 199-205.
 23. Deger, S. A.; Gül, A. E. and Biçek, K. (2003). The prevalence of *Eimeria* species in goats in Van. Turk. J. Vet. Anim. Sci., 27: 439-442.

تشخيص الأكريات الطفيلية (الكوكسيديا) في الماعز (*Capra ibex*)

سعد محي حيدر البياتي¹ و عدنان محمد الريكاني² و احمد عبدالله حمد²
¹ معهد دهوك التقني، جامعة دهوك التقنية، ² كلية الزراعة، جامعة دهوك، العراق.

E-mail: bayati196459@gmail.com

الخلاصة

لوحظت طفيليات الأكريات (الكوكسيديا) في 29 (37.67%) رأساً من 77 رأساً من ماعز المرعز *Capra ibex* وكانت نسبة الإصابة في جدها تصل إلى 22.08% في الأعمار أقل من 6 اشهر مقارنة بنسبة 15.59% بالأعمار الأكبر وكان الإسهال المتوسط هو العلامة الوحيدة في الجداء وبنسبة 3.9%. وشخصت ستة أنواع هي (*E.alijevi*, *E.christenseni*) ويعتقد إن النوع *E.megaembryonica* جديداً كونه يحتوي على كتلة جنينية كبيرة مع ملاحظة القرص الجنيني محاطاً بطبقتين قبل مرحلة التبويض وهذا في أغلب الأنواع المعزولة، وتعد المعايير الثلاثة الأخيرة جديدة في ذلك. وكانت نسبة محلول البوتاسيوم ثنائي الكرومات والبالغة 5% هي الأفضل لإنجاح عملية التبويض ومنع الملوثات الإحيائية للفضلات وبدون أن تؤثر في الصفات الحيوية للأنواع المعزولة من الكوكسيديا.

الكلمات المفتاحية: الأكريات الطفيلية، كوكسيديا، ماعز المرعز.