

نتائج موجبة لأختبار الروزبنكال في الخيول

نبيه محمد عطا ، محمد جويد علوان ، سعدي أحمد غناوي السامرائي
شاكر محمود مرهش ، حيدر بدري عبود ،أياد عبد الجبار
كلية الطب البيطري - جامعة بغداد

ملاحظات قصيرة

لوحظت حالات متفرقة في مجموعة من الخيول شملت ناسور الحارك، التهاب المفاصل وتورم كيس الصفن. سحبت عينات دم من بعض هذه الحالات ومن خيول تبدو سليمة لقياس خضاب الدم وأجراء اختبار الروزبنكال (Rose Bengal test). كذلك تم سحب نموذج من السائل في كيس الصفن. أظهرت الفحوصات أن مستوى خضاب الدم كان ضمن الحدود الطبيعية (11.6-16.2)غم/100سم³. وان خمسة خيول من عشرة (50%) أظهرت نتيجة موجبة لأختبار الروزبنكال وكانت من الجنسين وبأعمار مختلفة ، ولم تقتصر على الخيول التي أظهرت ناسور أو تورم . ولم تعزل جراثيم من السائل المصلي الرائق والحاوي على كريات دم حمراء وخلايا قلبية والمسحوب من كيس الصفن لأحد الخيول .

EFFECTS OF FENUGREEK SEED ON HEPATIC CELLULAR FUNCTION'S IN LAYING HENS

M. A. AL-Qayim

Dep. Of Physiology and Pharmacology. College of Vet.
Med. University of Baghdad.

SUMMARY

The seeds of *Trigonella foenum graecum* (Fenugreek) was fed to laying hens at dietary level of 6% for 28 days. FG seeds generally had no toxic effects as evidence by normal liver function tests. Histological examination of liver sections from FG seeds fed hens (groupT) lack of any histopathological changes as compared with hens fed basal diet (groupC), and the activities of plasma transaminases enzymes were not altered. On the other hand the plasma level of ALP enzyme significantly increased under the effects of feeding FG seeds. Plasma sugar of groupT revealed a significant elevation correlated with a decrease in plasma proteins. The results of the present work indicate a nontoxic effect of FG seeds on hepato cellular function.

INTRODUCTION

Fenugreek (*Trigonella Foenum Graceum*), in Arabic Hulbah, is an annual plant from the family Papilionaceae-Legiomenosis, and is extensively cultivated as a good crop in India, the Mediterranean region, North Africa and Yemen. Fenugreek (FG) seeds are employed as a herbal medicine in many parts of the world. It is used for their carminative, tonic and aphrodisiac effects (1). It is assumed to have stimulating effects on the digestive process (2). FG seeds have been known for a long time for their antidiabetic effect (3,4). Acurative gastric antiulcer action of the FG seeds (5) and hypocholesterolemic effects (6) have been reported, in addition of its action as a good antioxidant (7).

Short term (90 days) feeding of FG seeds to rats at level equivalent to 2 and 4 times the therapeutic dose recommended for humans (25g/day) produced no toxic effects as evidence by normal liver function tests, lack of any histopathological changes in the liver and no changes in haematological parameters (8).

The present work was designed to study the effects of FG seeds on some physiological functions of

hepatic cells in laying hens fed diet containing fenugreek seeds.

MATERIAL AND METHODS

Experimental design : Twelve , 42 week old new-Himpshir laying hens were equally divided into two groups and placed in individual cages (30*45*40 cm³) in an environmentally controlled room (24C and 16 hours of light daily). Birds were a signed to one of two dietary treatments : basal diet as control group and 6% FG diet for treatment group, according to findings of previous study (7). All diets were formulating according to (9). Feed and water were supplied for *adlibitum*. At the end of 4 weeks experimental period, body weight for all birds was recorded, and before birds were sacrificed the individual blood samples were withdrawn from the wing vein into a tube containing a drop of 10% EDTA. Blood samples were centrifuged for 10 minutes at 2500rpm and the plasma was separated for biochemical analysis.

Histological preparation: Livers were removed, weighted, fixed in buffered formalin and processed in a series of graded ethanol for dehydration. Paraffin section were cut out at 6 micrometer in thickness,

stained with Harris hematoxylin and eosin stain. Five consecutive sections from each sample were examined.

Biochemical analysis: Plasma sugar was estimated by reduction of phosphomolybdenic method as described by (10) and plasma total proteins were determined by Biuret method (11). Plasma enzymes levels estimated by using a commercial Kits, transaminase enzymes AST and ALT levels (Randox company) and ALP activity (Biomeurex .Sa).

Statistical analysis: All results are expressed as means \pm SE, and all data were statistically analyzed using students t-test at the level of $P < 0.05$ (12).

Table: 1. The ingredients and nutrient composition of experimental diets.

Ingredients %	Added Fenugreek	
	0% (Control)	6% (Treatment)
Corn	51.0	58.5
Barly	21.0	10.2
Soy been(44% protein)	11.0	8.5
Concentrated protein (CP)*	10.0	10.0
Ca Cl ₂	6.5	6.5
NaCl	0.3	0.3
Fenugreek seeds**	0.0	6.0
Calculated nutrient composition (% dry mater).***		
Metabolizable energy Kcl/Kg (ME)	2752	2752
Crude protein (CP) (%)	16.50	16.51
Lenoleic (%)	1.52	1.34
Calcium (%)	3.32	3.32
Phosphorus (%)	0.51	0.51
Crud Fiber (%)	3.32	3.31
Fat (%)	3.43	3.01

* Concentrated protein contain CP50% , ME 2500 Kcl/Kg , Lysin 3% , Methionin +Cystine 6.2% , Calcium 1% , Phosphorus 4%

** Fenugreek seeds chemical analysis: soluble carbohydrate 46% , CP 28-2% , Fat 7.6% , C.F.

*** Nutrient values of other ingredients estimation base on values obtained from (9).

RESULTS

Histological changes: The histological sections of liver tissue from control group showed normal hepatic histology Fig (1). The results showed in Fig (1-A) indicate that feeding FG diet induce intense cellular infiltration especially of plasma cells in the portal area or as a follicles Fig (1-B), these findings were not observed in liver sections of control birds.

Biochemical analysis: Birds fed 6% FG diet showed a significant ($P < 0.05$) increase in plasma sugar, while the level of total proteins decreased significantly table (2). The activities of the serum transaminase enzymes (ALT and AST) were not altered under the effects of feeding FG seeds Fig (2). On the other hand the plasma level of ALP enzyme significantly ($P < 0.05$) increased in all birds fed basal diet Fig (2).



Figure1: Liver section of control birds with normal hepatic histology. h = terminal hepatic venule, p = portal tract. Hematoxylin and eosin stained (100x).

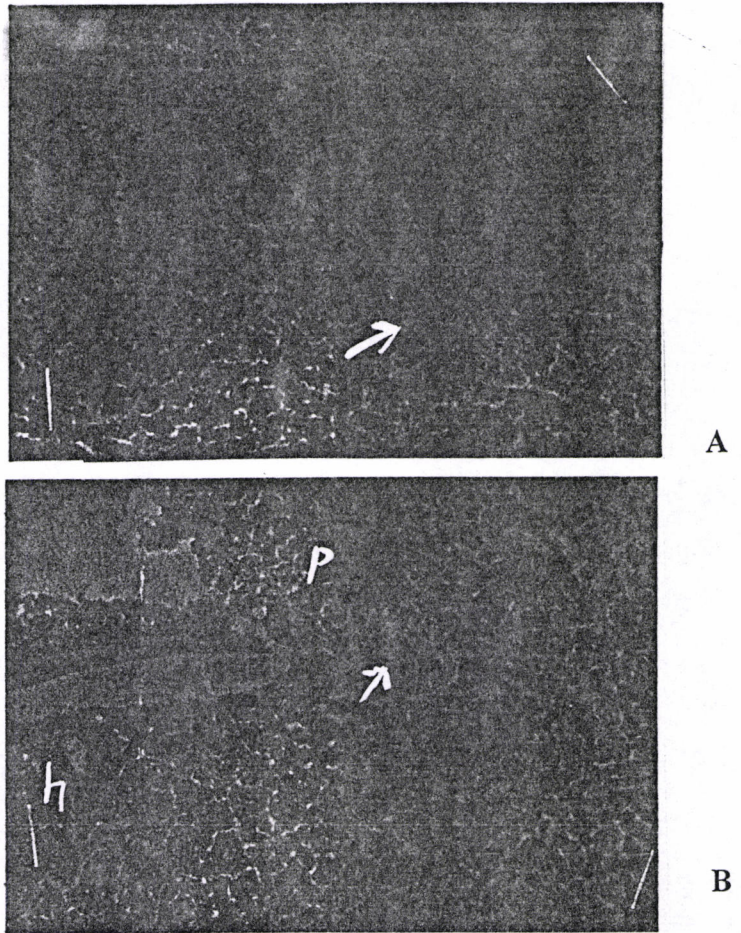


Figure2: Liver sections of treated birds: A= liver parenchyma infiltrated with lymphocytes. B = lymphocytes follicle. h terminal hepatic venule, p= portal tract. Hematoxylin and eosin stained (100x).

Table 2 : Effects of Fenugreek seeds on plasma sugar and proteins in laying hens (means \pm SE).

Diet	Plasma sugar (mg/dl)	Proteins (g/dl)
Basal diet (control)	164.8 \pm 4.5	3.9 \pm 0.31
6% FG (treated)	212.0 \pm 9.5*	3.0 \pm 0.26*

* means with different super scripts are significantly different (P < 0.05) n=6

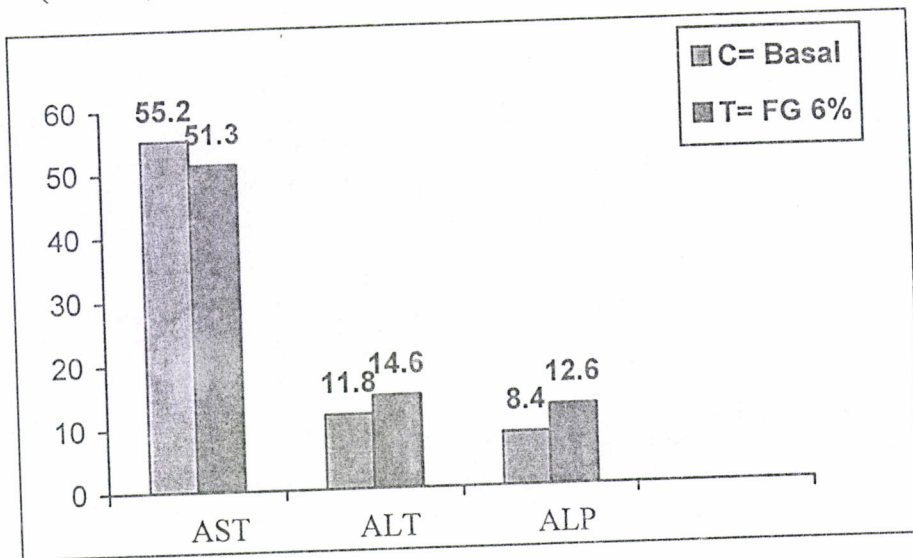


Figure 3: Effect of Fenugreek seeds on plasma transaminase and ALP in laying hens (means).

DISCUSSION

The results of the present study indicate that the feeding of 6% FG seeds diet did not cause any toxic effects on hepatic cellular histology, except the cellular infiltration which can be attributed to the effect of FG components in increasing glucocorticoides (15), since elevation of glucocorticoides cause lymphocytes infiltration in different tissues (16). However these nontoxic effects of FG were manifested by normal value of liver function enzymes level (ALT, AST) showed in Fig.3. A similar observations was cited in rats and rabbits fed FG seeds (8,13). Further more (14) found that i/m injection of FG saponins caused cytoplasmic necrosis, and cellular infiltration in liver of hisxus broelar.

The plasma glucose was significantly influenced by FG seeds (table 2). In laying hens increase of plasma glucose can be account for the increase of effect of hormones related to gluconeogenesis from protein catabolism such as corticosteroides (17). However, the results of the present study suggest that FG seeds increase plasma sugar as a result of protein

catabolism, since protein level decreased significantly in treated birds (table 2). Fenugreek seeds have been known for their activity in increasing of glucocorticoids (15).

The significant increase of ALP enzyme in plasma of birds Fed 6% FG diet can be attributed to the effects of FG seeds components. FG seeds are known to contain steroidal saponin (18) carotenoids and vitamins E and C (19, 20). Confirmatory evidence for an effects of these component on ALP, Ca^{++} and Po_4^- was reported in laying hens (21, 22, 23).

REFERENCES

- 1- Chopra, R.N., Chopra, I.C., Honda, K.L., and Kapur, L.D. (1982) *Chopras Indigenous Drug of India*, P. 582. Academic publisher, Calculate, New Delhi, India.
- 2- Fazli, F.R.Y., and hardman, R.(1968) The spice, Fenugreek (*Trigonella foenum graceum*): Its commercial varieties of seeds as source of diosgenin. *Tro.Sci.*10,66.
- 3- Ghafghazi, T., Sheriat, H.S., dasmalchi, T., and Barnett, R.C., (1977) Antagonis of cadmium and alloxan- induced hyperglycemia in rats by *Trigonella fenum graceum*. *Shiraz. Med*, J.8, 14-25.
- 4- Ribes, G.; Sauvaire, Y.; Da-Costa, G.; Bacco, J.C.; Loubatieere, M.M., (1986) Antidiabetic effects of subfractions from fenugreek seed indiabetic dogs. *Proc. Soc. Exp. Med.*, 182, ISS2: 159-166.
- 5- AL-meshal, I.A.,parmer, N.S., Tariq, M., and Aqeel, A.M.,(1985) Gastric anti-ulcer activity in rats of *Trigonella foenum graceum*. *Fito terapia* 56, 233-235.
- 6- Sharma,r.d.,sarkar,a.,andhazar,d.k.etal.(1996) hypo-lipidaemic effect of fennugreek seeds:achwnic

- study in non-insuline dependent diabefic patients. phyto ther-res. 10,332-334.
- 7- AL-Qayim, M.A., (1999) Effect of fenugreek seeds on egg yolk lipids and some blood constituenst in the chicken. PhD thesis in Veterinary medicine physiology. University of Baghdad.
 - 8- Rao, P.U.; Sesikerau, B.; Rao, P.S.; naidu, A.N. and Ramachandram, E.P., (1996) Short Term Nutritional safety evaluation of fenugreek. Nutrition-research. V.(6,9):1995-1505.
 - 9- National research Council (N.R.C.) 1994 Nutrient Requirement of poultry 9th ed. Washington DC. National Academy Prees.
 - 10- Wootton I.D.P., (1964) micro analysis in medical Biochemistry 112-114th ed. J&A Churchill. London
 - 11- Coles. E.H., (1986) Avian clinical pathology in: veterinary clinical pathology 4th ed. W.B., Saunders company Philadelphia.
 - 12- Steel R.G.D., and Torrie, J.H. (1980) Principles and Procedures of statistics Mc graw- Hill Book company.
 - 13- AL-Habori, M.A. and Raman A., (1998) Antidiabetic and hypo cholesterolemic effects of fenugreek. Phytotherapy Research (U.K.), 12 (4): 233-242.

- 14- Nakhla, H.B.,; Mohamed, O.S.; Abu, I.M; Fatuh, Al.and Adam, S.E.,(1991) The Effects of trigonella foenum graceum (Fenugreek) crude saponins on Hisex-type Chick. Vet. Aum. Toxicol. 33, ISS6: 561-645.
- 15- Guyton, M.D.A. (1986) Text book of Medical Physiology, 7th ed. Chapter (6). W.B. Saunders Company.
- 16- Freeman, B.M., (1988) Stress and domestic fowl in biochemical research: Physiological effects of the environment. Wids. Poultry Sci. J., 44,41-61.
- 17- Baue, P.S.; Spinivasn, K.,(1993) In Fluence of dietary spices on adrenal steroidogenesis in rats. Nutrition on research, 192,85-94.
- 18- Sanvaire, Y., Baissac, Y., Leconte, O., Petit, P. and Ribes, G.(1996) Steroid Saponins from Fenugreek and Some their biological properties. Adv. Exp. Med-Bio. 405,37-46.
- 19- Chadha, Y.R., (1976) Trigonella foenum graceum. In wealth of India, V.X., Industrial products publication and information Direct rate Cs/R New Dalhi. Pp:580-585.
- 20- Varshney, I.P., and Sharma, S.C (1996) Saponins XXX11-Trigonella foenum graceum seeds. J. Indian Chem. Soc. 43,564-567.

- 21- Weiser, H. and Probst, H.P.(1990) Biopoteny of ascorbic acid and its derivatives determined by plasma alkaline phosphataes activity in Guinea Pigs. In: Ascorbic Acid in domestic animals preceeding of 2end symposium. Kartause Lettingen, Switzerland.
- 22- Rath, N.C.; huff W.E.; and Bayyari, G.R.(1996) Effects of gonadal steroids on bone and other physiological parameters of male brolier Chicknes. Poultry Sci. 75,556-562.
- 23- AL-Daraji, H.J.,(1998) Effects of ascorbic acid supplementation on reproductive and physiological traits of fawbro broiler breeders veared under hot climate. PHD thesis. University of Baghdad. Animal resources.

تأثير بذور الحلبة في وظائف خلايا الكبد في الدجاج البيوض

ماجدة عبد الخالق جعفر القيم
فرع الفلسفة والأدوية/ كلية الطب البيطري جامعة بغداد

الخلاصة

غذيت مجموعة من الدجاج البيوض البالغ على علائق تحتوي بذور الحلبة بنسبة 6% ولمدة 28 يوماً. أظهرت نتائج الدراسة إن تناول بذور الحلبة لم يحدث أي تأثيرات سمية على خلايا الكبد، حيث أتعدم ظهور أي تغيرات نسيجية مرضية في خلايا الكبد بالإضافة إلى ذلك فأن مستويات الأنزيمات (AST, ALT) ذات العلاقة بوظائف الكبد قد حافظت على مستوياتها الطبيعية في الطيور المعاملة عند مقارنتها مع طيور السيطرة.

أظهرت طيور مجموعة المعاملة زيادة ملحوظة في سكر الدم رافقها انخفاض في بروتينات الدم الكلية. وفي الوقت نفسه كان هنالك ارتفاع مهم إحصائياً في مستوى أنزيم ALP تحت تأثير تناول بذور الحلبة.