

نتائج موجبة لأختبار الروزبنكال في الخيول

نبيه محمد عطا ، محمد جويد علوان ، سعدي أحمد غناوي السامرائي
شاكر محمود مرهش ، حيدر بدري عبود ، أياد عبد الجبار
كلية الطب البيطري - جامعة بغداد

ملاحظات قصيرة

لوحظت حالات متفرقة في مجموعة من الخيول شملت ناسور الحارك، التهاب المفاصل وتورم كيس الصفن. سحبت عينات دم من بعض هذه الحالات ومن خيول تبدو سليمة لقياس خضاب الدم وأجراء اختبار الروزبنكال (Rose Bengal test). كذلك تم سحب نموذج من السائل في كيس الصفن. أظهرت الفحوصات أن مستوى خضاب الدم كان ضمن الحدود الطبيعية (11.6-16.2)غم/100سم³. وان خمسة خيول من عشرة (50%) أظهرت نتيجة موجبة لأختبار الروزبنكال وكانت من الجنسين وبأعمار مختلفة، ولم تقتصر على الخيول التي أظهرت ناسور أو تورم. ولم تعزل جراثيم من السائل المصلي الرائق والحاوي على كريات دم حمراء وخلايا قاحية والمسحوب من كيس الصفن لأحد الخيول.

TOPOGRAPHICAL AND HISTOLOGICAL STRUCTURE OF DUCTUS EPIDIDY MIDS OF COMMON QUAIL (*Coturnix. c. coturnix* L.)

Al-Samarrae*, N.S; Al-Jobori*,
KH.A.; Al-Hathry**, S.A., and Al-Shamary* .B.F.

* Dept. of Anatomy, Histology and Embryology,
College of Veterinary Medicine, University of Baghdad,

** Dept. of Biology, College of Education (Abin Al-
Hytham), University of Baghdad

SUMMARY

The epididymal region of the common quail was located on the dorso-medial aspect of the testis, extending from cranial pole to the caudal pole of the testis and connected the urodeum via the vas deferens and the receptaculum. The ductus epididymidis in common quail showed a series of coiled ductules which were closely bounded to the testis by connective tissue. The lining epithelium of these ductules were ciliated columnar epithelium, but non ciliated columnar epithelium were also noticed.

INTRODUCTION

The male reproductive system of birds have been studied by a number of researchers viz:; Lake (1), Florentin et al (2), Yamamoto et al (3), Marvan (4), March and Sadler (5), Tingari and Lake (6), Aire et al (7), King and Mclelland (8), Hess et al (9), Hussian and AL-Samarrae (10). The quail has become a very important animal in avian endocrinology and reproductive research and this makes it imperative that the normal structure and function of the relevant organs especially the epididymal region could be investigated as a guide for further physiological and pathological studies.

MATERIALS AND METHODS

Ten common quail were purchased from the local market at Baghdad city. These common quails were killed with an overdose of sodium pentobarbital and dissected immediately for topographical and histological examination of the epididymal region (Ductus epididymidis) The ductus epididymidis of these birds were quickly fixed in Bouin's fluid, dehydrated in alcohol, cleared in xylol and embedded in paraffin wax. The wax blocks were serially sectioned at five micrometer in different orientation . Histological

sections were stained with hematoxylin and counter stained with eosin – phloxine; and Masson trichrome (11).

RESULTS AND DISCUSSION

The location of the epididymal region in the common quail (*Coturnix. c. coturnix L.*) was found on The dorso – medial aspect of the testis . This epididymal region was attached very intimately and extending from the cranial pole to the caudal pole of the testis. The caudal region of the epididymis formed a very dark gray region which represent the ductus deferens. The present finding further support the previous finding of Aire (12). Histological observations of the epididymal region of common quail showed a series of ductules surrounded by discrete mass of connective tissues which was linked to the tunica albuginea of the testis. These ductules represent the ductus epididymidis. The lining epithelium of these ductules was columnar epithelium (Fig. 1) This epithelium consists of ciliated and non ciliated cells. The former cells were tall columnar with ovoid nuclei and have protoplasmic extensions or microvilli on their free surface (Fig. 1) while the later cells have no cytoplasmic evagination or at least contained less

extensive cilia (Fig. 2). The luminal content of these ductules contained mainly of spermatozoa. The ductus epididymidis was surrounded by loose connective tissue rich in fibroblasts which increased gradually toward the tail of the epididymis. Smooth muscle fibers were found intermingled with the connective tissue. Our finding confirmed the observations of Lofts et al (13) in British Columbidae. The ductus epididymidis of common quail continues distally as the ductus deferens and before entering the Urodeum of the cloaca, the ductus deferens expanded to form a seminal sac or receptaculum which was also heavily charged with spermatozoa. Tingari (14) stated that that epididymal region of the fowl, turkey and Japanese quail gradually widened and lost its ciliated cells. Stoll and Maraud (15) and Bailey (16) left the impression that the lining epithelium of the ductus epididymidis of the cockerels and fringillid birds consist of both ciliated and non-ciliated columnar cells. This impression is in agreement with our histological observations but generally, the ciliated columnar epithelium of the epididymal region in the common quail have had lighter staining than the non-ciliated columnar epithelium. The observation of Tingari (17) on the

epididymal region of the domestic fowl showed no differences in the stain ability of these two columnar cell types.

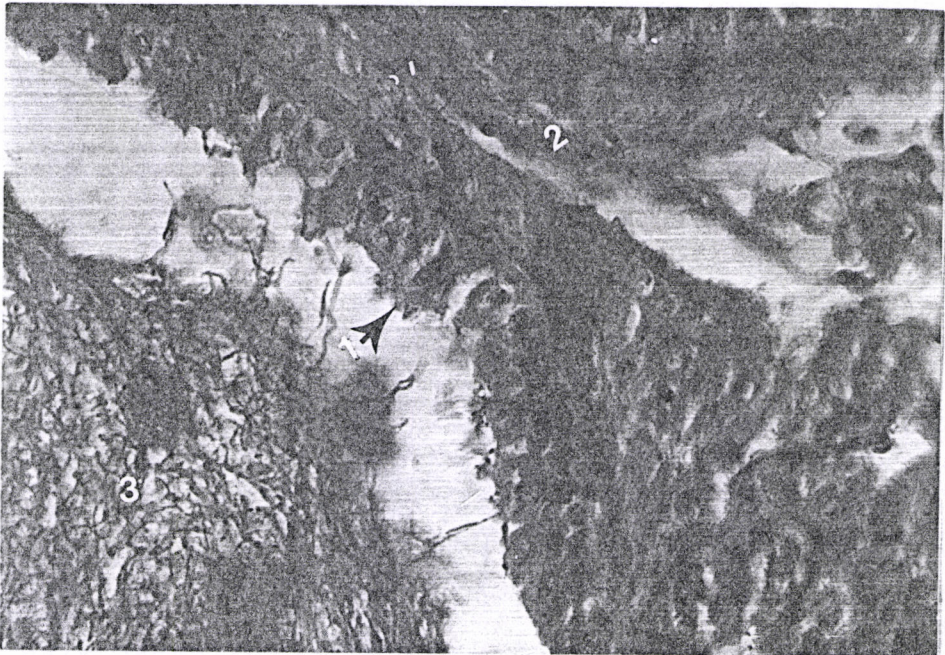

Fig. 1: Section of ductus epididymidis showing 1- ciliated epithelium surrounded by 2- masses of connective tissue, 3- the lumen of ductule charged by spermatozoa. Hematoxylin eosin-phloxin X500.




Fig. 2: Section of ductus epididymidis showing; 1- non-ciliated epithelium,2-bundles of collagen fibers,3- spermatozoa.Masson trichrome X 250.

REFERENCES

- 1-Lake, P.E (1957) The male reproductive tract of the fowl. J. Anat 91:116-129.
- 2-Florentin, P.P., Blin, T.A., Cuq, P.I. (1961) L'appareil genital male du canard. Rev. Med. Vet. 112: 421-444.
- 3-Yamamoto,S., Tamate,H., Hikawa, O. (1967) Morphological studies on the sexual maturation in the male Japanese quail (*Coturnix coturnix Japonica*). Tohoku J. Agr Res. 18: 27-30.
- 4-Marvan, F.(1969).Postnatal development of the male genital tract of the *Gallus domesticus*. Anat. Anz. 124: 443 -462.
- 5-March, G.L., Sadler, R.M. (1970) Studies on the Band-tailed pigeon (*Columba Fasciata*) in British Columbia . 1- Seasonal changes in gonadal development and crop gland activity . Cand. J. Zool. 48: 1353-1357.
- 6-Tingari, M.D. Lake,P.E. (1973) Ultrastructural evidence for resorption of spermatozoa and testicular fluid in the excurrent ducts of the testis of the domestic fowl (*Gallus domesticus*) J. Reprod. Fertil. 31: 373-375.

- 7-Aire, T.A., Ayeni, J.S., Okorun, M.O. (1978) The structure of the excurrent ducts of the testes of the guinea fowl (*Numida meleagris*). *J. Anat.* 129: 633-643.
- 8-King, A.S., McLelland, J. (1984) *Birds; their structure and function. Male reproductive system.* 2nd. Ed. Billari company. London, pp: 166-171.
- 9-Hess, R.A., Thruston, R.J., Biellier, H.V. (1976) Morphology of epididymal region and ductus deferens of the turkey (*Meleagris gallopavo*). *J.A nt* 122:241-252.
- 10- Hussin, A.M., AL-Sammarrae, N.S. (1999) Anatomical and Histological study of the male reproductive system in turkey (*Meleagris gallopavo*). *Iraqi J. Vet. Sci.* 12: 1-17.
- 11- Vacca, L. (1985) *Laboratory manual of histochemistry*, 1st ed. Ravan Press. New York, U.S.A., pp. 118-121;308-310.
- 12- Aire, T.A. (1979) The epididymal region of the Japanese quail (*Coturnix coturnix japonica*) *Acta. Anat.* 103: 305-312.
- 13- Lofts, B., Murton, R. K., Westwood, N. J. (1966) Gonad cycles and the evolution of breeding

- seasons in British Columbidae. T. J. Zool. 150: 249-272.
- 14- Tingari, M.D. (1971) On the structure of the epididymal region and ductus deferens of the domestic fowl (*Gallus domesticus*). J. Anat. 109: 423-425.
 - 15- Stoll, R. and Maraud, R.(1955) Sur la constitution de l'epididymal du coq. C. R. Seanc. Soc. Biol. J. 149: 687-689.
 - 16- Bailey, R. E. (1953) Accessory reproductive organs of male fringillid birds. Seasonal variations and response to various sex hormones. Anat. Rec. 115: 1-20.
 - 17- Tingari, M.D. (1972) The fine structure of the epithelial lining of the excurrent duct system of the domestic fowl (*Gallus domesticus*). Q. Exp. Physiol. J. 57: 271-295.

التركيب الطبغرافي والنسيجي للقناة البربخية في طائر السلوى (المريعي) *Coturnix c. coturnix L.*

نعمان سلمان السامرائي* ، خالد أحمد حسين الجبوري* ، ستار عبود

الحضري** ، بسام فليح الشمري*

* فرع التشريح والأنسجة والأجنة ، كلية الطب البيطري ، جامعة بغداد

** قسم البايولوجي ، كلية التربية (أبن الهيثم) ، جامعة بغداد

الخلاصة

تقع منطقة البربخ في الجهة الظهرية الإنسية لخصية طائر السلوى المريعي ، وتمتد من القطب القحافي إلى القطب الخلفي للخصية وتتصل مع المسلك الحالبي من خلال قناة الأسهر والصحريج . تظهر القناة البربخية لطائر السلوى ، سلسلة من القنويات الكثيرة الالتفافات تلتصق بشدة مع الخصية بواسطة النسيج الضام. كان نوع ظهارة القنويات البربخية ، هي الظهارة العمودية المهدبة ولكن لوحظ وجود ظهارة عمودية غير مهدبة .