



Stereological and Histopathological Effects of *Trigonella foenum-graecum* Seeds on Rabbits Ovary

Ahmed S Al-Araji¹, Tamara N Dawood^{2*} , Dhyaa Ab Abood¹ 

¹Department. of Anatomy and Histology, College of Veterinary Medicine, University of Baghdad, Iraq,
¹Department. of Veterinary Public Health, College of Veterinary Medicine, University of Baghdad, Iraq

*Correspondence:
tamara.natiq@covm.uobaghdad.edu.iq

Received: 23 March 2020
Accepted: 1 September 2020
Published: 28 December 2020

DOI:
[https://doi.org/10.30539/ijvm.v44i\(E0\).1016](https://doi.org/10.30539/ijvm.v44i(E0).1016)



This article is an open access distributed under the terms and conditions of the Creative Common Attribution License (CC BY 4.0)

Cite

Al-Araji AS, Dawood TN, Abood DA. Stereological and histopathological effects of *Trigonella foenum-graecum* seeds on rabbits' ovary. Iraqi J. Vet. Med. 28 Dec. 2020; 44(E0):29-33.

A B S T R A C T

This study aimed to investigate the impacts of the *Trigonella foenum-graecum* (*T. foenum-graecum*) seeds on the female gonad. A total of twenty local rabbits were used in this study; were divided into four groups (5 each): first group (G1) was considered as the control group. The second group (G2), third group (G3) and fourth group (G4) were fed daily 1.5%, 3%, and 4.5% of *T. foenum-graecum* seeds respectively for 60 days (twice daily). At the end of the experiment, the animals were euthanized by diethyl ether (C₂H₅2O). Then the abdomen was incised, and the samples of ovaries were collected and fixed by 10% neutral buffered formalin. The histological assessment was done with a paraffin embedding technique and the histological sections were stained with Hematoxylin and Eosin stain. The result showed that the numbers of primary and secondary follicles were significantly ($P < 0.05$) decreased in G3 and G4 compared with the control (G1) and G2. The numbers of Graafian follicles were significantly $P < 0.05$ decreased G4 compared with other groups. The diameters of the primary, secondary, and Graafian follicles were significantly smaller than the other groups. The thickness of the granulosa cell layer in G3 and G4 were significantly thinner than the other groups. The histological figures declared that the ovary of G2 was similar to that in G1. The histological sections of G3 and G4 were revealed marked cortical and medullary vascular congestion and focal hemorrhage; there were also marked follicular degeneration and cystic necrosis. The study concluded that the low concentration of *T. foenum-graecum* (fenugreek) seeds do not have any positive effect in terms of ovarian stimulation.

Keywords: rabbits, ovary, *Trigonella foenum-graecum*, seeds, fenugreek, follicles

INTRODUCTION

The chief objective of the plants' is the food source, several types of uses as the provenance of medicine (1). *Trigonella foenum-graecum* (Fenugreek) is a leguminous grass cultivated in different countries around the world such as Asia and Africa; seeds of Fenugreek are known in

ancient before 2500 years ago; it is utilized as a classical feed and feed additive in addition to its medicinal uses flatulence, dyspepsia, bronchial asthma and antitussive (2), other uses in cook as flavoring agents (3). The most active medical ingredient of fenugreek seeds, progesterone and estrogen-like effect (4, 5). The rabbit ovaries are relatively small in size and have flattened oval shape. Each ovary cell surface is separated from underlying tissue by tunica

albuginea (fundamental basement membrane) which is divided into medulla (inner part) and cortex (outer part). Cortex is divided into follicles and stroma components (6, 7). Seeds of *T. foenum-graecum* possess estrogen-like activity, so it can increase the size of ovary through folliculogenesis enhancement. The increment of ovarian size is promoted by a growing and increase the number of resurgent follicles types as a result to estrogenic effect dominants (5). In the female, the main site of estrogen secretion is the ovarian granulosa cells and theca interna (8). Therefore, this study was aimed to determine the effect of *T. foenum-graecum* seeds on the female gonads.

MATERIALS AND METHODS

Experimental Animals

The procedures used in this study were reviewed and approved by the scientific committee at the University of Baghdad's College of Veterinary Medicine in compliance with animal welfare ethical standards.

This study used a total of twenty local female rabbits that were 8-10 months old and weighed 1.6-1.8 kg. The animals were housed in the animal house of the College of Veterinary Medicine, University of Baghdad during September to November 2019, at a temperature of 25 ± 2 °C, with a light-dark cycle of 12:12 hours, and standard ventilation system and humidity (2). Rabbits were divided into four groups; (of 5 each). The first group (G1) was served as a control group which fed 100 g/daily concentrate diet (pellets) and green forage. The second group (G2) was fed 100 g/ daily of ration supplemented with 1.5% *T. foenum-graecum* seeds. The third group (G3) was fed daily of 100 g of ration supplemented with 3% *T. foenum-graecum* seeds and the fourth group (G4) was fed daily 100 g of ration supplemented with 4.5% *T. foenum-graecum* seeds. The study lasted for 60 days. Rabbits fed on a concentrate diet (pellets) and green forage as a preliminary period for 2 weeks for acclimatization.

Plant

The *T. foenum-graecum* seeds were obtained from a local market at Baghdad province, Iraq, cleaned and authenticated in the Iraqi National Herbarium.

Histopathological and Stereological Evaluation

Histopathological processes were performed at the end of the experiment after euthanizing the rabbits by diethyl ether and incising the abdomen of animals. The ovaries were obtained and fixed with 10% neutral buffered formalin, then prepared for paraffin embedding technique and sectioned at 5-6µm and stained with hematoxylin and eosin stain (9). Tissue sections were examined and photographed by Olympus microscope SC 35 camera.

The stereological assessment was included the numbers, diameters of different types of ovarian follicles and thickness of their granulosa cells layer. The images was analyzed and scored using Fiji image analyzer system (10).

Statistical Analysis

Data were analyzed by SPSS (version 24.0). All numerical results were expressed as the mean \pm standard error (SE). For comparisons, the statistical significance was assessed by ANOVA. The significance level was set at $P < 0.05$ (11).

RESULTS AND DISCUSSION

Stereological Analysis

The results revealed significant ($P < 0.05$) decrease in numbers of the primary follicles in the G1 and G2 (3.4 ± 0.5099 and 2.0 ± 0.3162), respectively. The numbers of secondary follicles also significantly ($P < 0.05$) decreased in G3 and G4 (2.3 ± 0.37 and 2.2 ± 0.36), respectively, while a significant decrease of the numbers of the mature Graafian follicles were only seen ($P < 0.05$) in G4 (1.7 ± 0.37) (Table 1).

The diameters of all types of follicles were significantly ($P < 0.05$) decreased in G3 and G4 primary follicles (100 ± 5 µm and 97 ± 8 µm), secondary follicles (185 ± 21 µm and 171 ± 15 µm) and Graafian follicles (317 ± 28 µm and 302 ± 18 µm), respectively (Table 2).

Table 1. Numbers of the primary, secondary, and mature Graafian follicles of local female rabbits (µm) fed 1.5%, 3%, and 4.5% of *T. foenum-graecum* for 60 days (Mean \pm SEM, n=5)

Groups	Primary follicles	Secondary follicles	Graafian follicles
Group 1 (Control)	5.00 \pm 0.31	3.60 \pm 0.24	2.60 \pm 0.22
Group 2 (1.5%)	5.30 \pm 0.24	3.90 \pm 0.20	2.90 \pm 0.29
Group 3 (3%)	3.40 \pm 0.50 *	2.30 \pm 0.37 *	2.50 \pm 0.19
Group 4 (4.5%)	2.00 \pm 0.31 *	2.20 \pm 0.36 *	1.70 \pm 0.37 *

*Means differ significantly at $P \leq 0.05$

Table 2. Diameter of the primary, secondary, and mature Graafian follicles (µm) of local female rabbits fed 1.5%, 3%, and 4.5% of *T. foenum-graecum* for 60 days (Mean \pm SEM, n=5)

Groups	Primary follicles	Secondary follicles	Graafian follicles
Group 1 (Control)	171 \pm 11	273 \pm 31	548 \pm 31
Group 2 (1.5%)	166 \pm 4	279 \pm 31	556 \pm 12
Group 3 (3%)	100 \pm 5 *	185 \pm 21 *	317 \pm 28 *
Group 4 (4.5%)	97 \pm 8 *	171 \pm 15 *	302 \pm 18 *

*Means differ significantly at $P \leq 0.05$

The thickness of granulosa cells layers significantly ($P < 0.05$) decreased in G3 and G4 with primary follicles (24.8 ± 1.85 µm and 21.30 ± 3.81 µm, secondary follicles (99.1 ± 4.02 µm, 82.3 ± 8.47 µm) and Graafian follicles (82.2 ± 3.98 µm and 73.4 ± 2.40 µm), respectively (Table 3).

This study agreed with the result of (12, 13) who referred to a decrease in the number of primary and secondary follicles and the diameter of secondary and

antrum follicles, on the other hand this result disagreed with the result of (13). The current results agree with opinion of (14) who referred to the adverse effect of methanolic extract of *Rumexstuedelii* which induced decreasing the number of follicles, corpora lutea and atrophic changes in the uterus.

Table 3. Thickness of the primary, secondary, and, mature Graafian follicles (μm) of local female rabbits fed 1.5%, 3%, and 4.5% of *T. foenum-graecum* for 60 days (Mean \pm SEM, n=5)

Groups	Primary follicles	Secondary follicles	Graafian follicles
Group 1 (Control)	68.4 \pm 2.26	113.2 \pm 5.08	99.8 \pm 4.44
Group 2 (1.5%)	61.4 \pm 0.42	119.3 \pm 2.72	91.6 \pm 1.92
Group 3 (3%)	24.8 \pm 1.85 *	99.1 \pm 4.02 *	82.2 \pm 3.98 *
Group 4 (4.5%)	21.3 \pm 3.81 *	82.3 \pm 8.47 *	73.4 \pm 2.40 *

*Means differ significantly at $P \leq 0.05$

The decrease in numbers of ovarian follicles is attributed to the effect of *Toenum-graecum* seeds on the levels of FSH and LH that cause disturbance of folliculogenesis (14) and this disturbance could be attributed to the affecting of the normal negative feedback mechanism. (15). Additionally, it could be attributed to the plant extract for containing phenolic compound effects on the secretion of estrogen and progesterone. Jhon et al. (16) showed that plant extract may have an effect on the production and secretion of FSH which secret from the pituitary gland and these changes in the secretion of the FSH and LH may occurred as a result from the effect of caffeic acids and cause a reduction in reproduction. On the other hand (17) revealed that the exogenous sources of estrogen may lead to decrease the number of different types of follicles, cause of cystic follicle and decrease in the number of the corpus luteum in female rat. Other study revealed that 3% of *T. foenum-graecum* seeds increased the concentration of estrogen and the concentration of progesterone has significantly decreased at 1.5% of *T. foenum-graecum* (18). The research also revealed that the offspring percentage increased significantly at 1.5% and 3% (19).

Histopathological Examination

Histopathological examination of ovaries in local female rabbits fed 1.5%, of *T. foenum-graecum* seeds for 60 days revealed that there were no significant effects when compared to the control group (Figures 1 and 2). However, the histological sections of female rabbits fed 3% and 4.5% seeds of *T. foenum-graecum* showed marked cortical and medullary pathological changes including marked vascular congestion, focal hemorrhage, follicular degeneration, and necrosis with cystic like- depletion. The degenerated follicle revealed marked vacuolar degeneration and necrosis of granulosa cells in addition to sloughing of granulosa cell layer from zona pellucida, edema of theca externa, and the stromal cells showed severe cellular swelling and necrosis

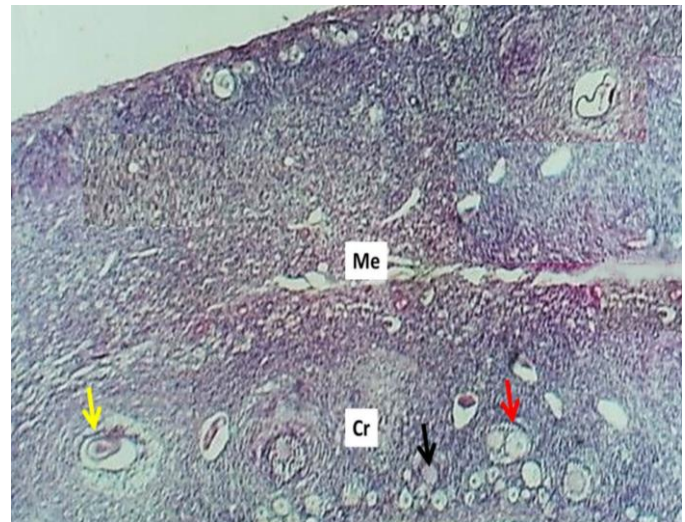


Figure 1. Histologic section of of female rabbit's ovary (Control) shows: cortex (Cr), medulla (M), primordial follicles (Black arrow) primary follicle (red arrow) and mature follicles (yellow arrows) H&E stain,40 \times

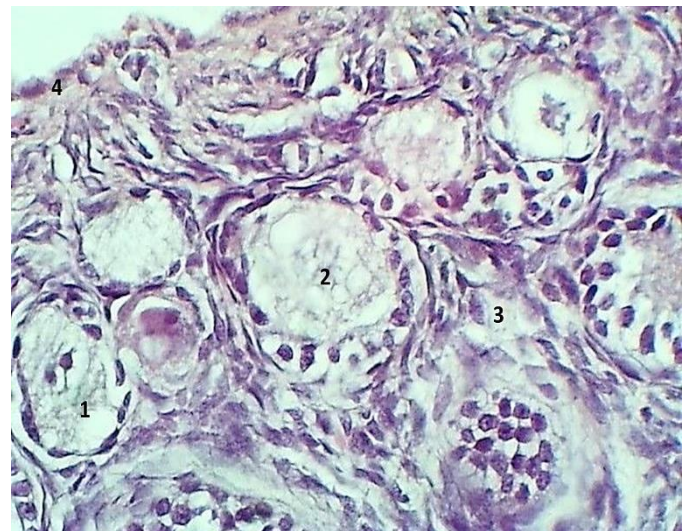


Figure 2. Histologic section of female rabbit's ovary (Control) shows: primordial follicles (1) primary follicle (2), stromal tissue (3) and germinal epithelium (4). H&E stain, 40 \times

(Figures 3, 4, 5, and 6). Such result agreed with the result of (1) who referred to many histological changes involved atretic changes. The histopathological changes were related to the presence of the saponins, steroids, and amino acids in fenugreek seeds extract in a dose of 200 mg/kg BW (6). On the other hand, in male reproductive and adenohipophysis, there were significant effects of aqueous extract of fenugreek seeds which may lead to decrease the acidophilic cells and increase the basophilic cells with great numbers of round cell debris may be seen in the lumen of epididymis; an increase in desquamation of epithelial cells within fluid secretion of the seminal vesicle (15). In present result the follicular number decreased in the groups G3 and G4 that treated with 3% and 4.5% of *T. foenum-graecum* seeds, respectively.

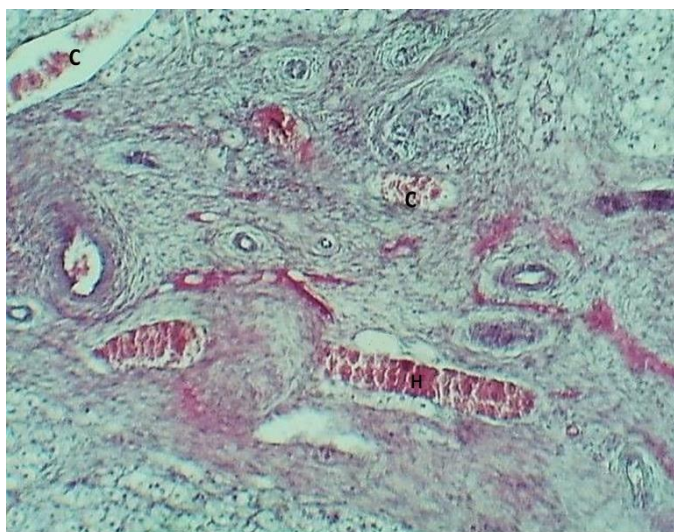


Figure 3. Section of ovarian medulla of female rabbits fed 3% *Trigonella foenum-graecum* for 60 days (G3) show: vascular congestion (C) and focal hemorrhage (H). H&E stain, 10×

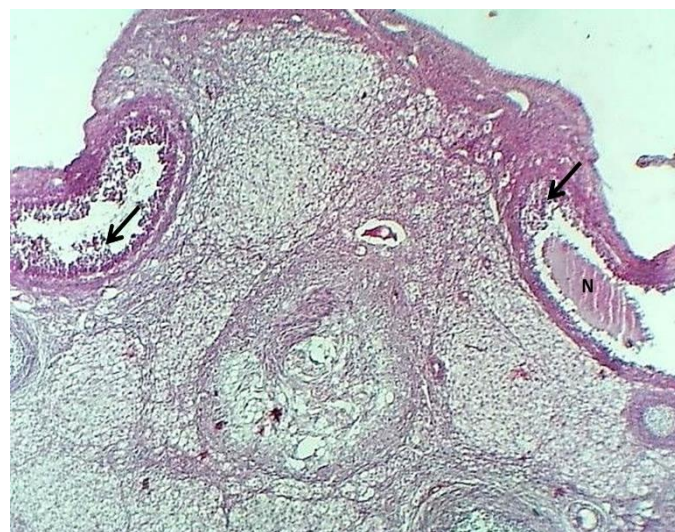

Figure 4. section of ovarian cortex of female rabbits fed 4.5% *Trigonella foenum-graecum* seeds for 60 days (G4) show: necrosis of oocyte (arrow) and degeneration of granulosa cells (arrows). H& E stain, 40×

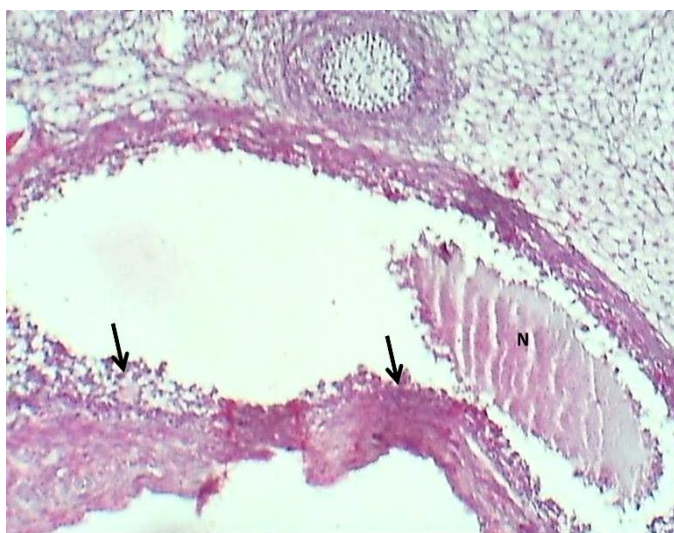


Figure 5. Section of mature follicle of female rabbits fed 4.5% *Trigonella foenum-graecum* seeds for 60 days (G4) shows: necrosis of granulosa cells (arrows) and oocyte (N). H&E stain. 10×

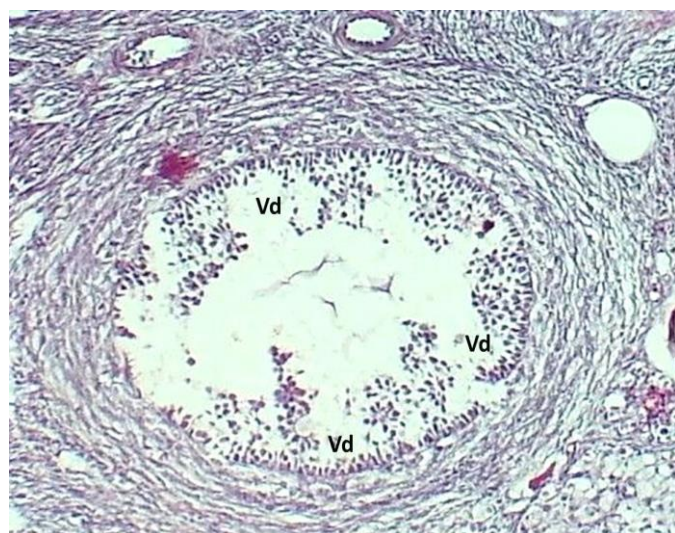


Figure 6. Section of late primary follicle of female rabbits fed 3% *Trigonella foenum-graecum* seeds for 60 days (G4) shows: vacuolar degeneration of granulosa cells (Vd) and depletion of oocyte. H& E stain, 10×

The above results agreed with (15) who mentioned that administration of *T foenum-graecum* extract may affect the fertility and prolificacy percentages. Kaiser et al. (19) showed that in treated rabbits, the number of Graafian follicles increased in addition to granulosa cell became associated with clear decrease in the fat percentage and their plasma membrane, while the primary and secondary follicle number was also decreased. On the other hand the current result disagreed with the result of (2) who revealed that the extract of *Toenungraecum* seeds act as anti-oxidative and anti-inflammatory and potential role in preventing hepatic and renal damage which induced by chronic NaNO_2 administration.

From the results of current study it could be concluded that low dietary concentration of fenugreek seeds do not have positive effect in terms of ovarian stimulation. On the

other hand, higher dietary concentration of *T. foenum-graecum* seeds could produce adverse effects on the reproductive efficiency and folliculogenesis.

ACKNOWLEDGEMENTS

The authors are appreciated the faculty members of the College of Veterinary Medicine, University of Baghdad for providing all facilities for completing this work.

FUNDING

These authors declare that above-submitted work was not funded by any governmental or private funding source nor supported by any financial projects.

CONFLICT OF INTEREST

The authors declare that there is no conflict of interest.

REFERENCES

- Allaw AK, Belqees AK, Yousof Z, Al-Ani I, Bracamonte M, Sadeeq A. Is there any effect of fenugreek seeds aqueous extract (FSA) on the quantity of ovarian follicles and estrus cycle of female rats. JMPR. 2016; 1(1): 55-63.
- Atila UG, Uslu H, AdaliY. Hepatoprotective and nephroprotective effects of *Trigonella foenum-graecum* L. (Fenugreek) seed extract against sodium nitrite toxicity in rats. BMRAT.2019;6 (5): 3142-3150.
- Al-Yasery AJ, Khaleel IM, Al-Aameli MH. Histological and hemato-biochemical study of fenugreek (*Trigonella foenum*) and ginger (*Zingiber officinale*) aqueous extracts on ovary structure in white swiss mice (*Mus musculus*). LSA.2017;3 (2): 962-973.
- Cahill LP, Mariana JC, Mauleon P. Total follicular populations in ewes of high and low ovulation rates. RRF. 1979;55 (1): 27-36.
- Danko J. Changes in ovarian mass, size and number of follicles in post parturientewes. ActaVeterinaria Brno. 1997;66 (2): 71-4.
- Dande PA, Patil SU. Evaluation of aponins from *Trigonella foenum graecum* seeds for its ant fertility activity. Asian J Pharm Clin Res. 2012;5 (3):154-7.
- Dawood TN, Al-Deri AH, Kareem EH. Effect of *Trigonella foenum graecum* seeds on the productive, reproductive performance and some biochemical traits in the local rabbits. IJSR. 2015; 6(5): 904-908.
- Dorostghoal M, Mahabadi MK, Adham S. Effects of maternal caffeine consumption on ovarian follicle development in wistar rats offspring. JRI. 2011;12 (1): 15-22.
- Bancroft JD, Gamble M. Theory and practice of histological techniques.6th. USA: Elsevier health sciences; 2008; 168-173 p.
- Suad KA, Al-Shamire JS, Dhyaa AA. Histological and biochemical evaluation of supplementing broiler diet with β -hydroxy-methyl butyrate calcium (β -HMB-Ca). IJVR. 2018; 19(1): 27.
- SAS. Statistical Analysis System, User's Guide. Statistical. 2010; V 9.1th ed. SAS. Inst. Inc. Cary. N.C. USA.
- Solomon T, Largesse Z, Mekbebe A, Eyasu M, Asfaw D. Effect of *Rumexstuedelii* methanolic root extract on ovarian folliculogenesis and uterine histology in female albino rats. AJOL. 2010;10(4): 353-361.
- Esson S, Ric L, Ekin O, Krush I. Effect of fenugreek (*Trigonella foenum*) on Gonad development and body vital values in mice. IJCH.2005; 64 (4): 387-395.
- Khaleel AA, Hamad KR. Effects of fenugreek (*Trigonella foenum-graecum*) seeds aqueous extract on the tissue structure of anterior pituitary gland and some organs of reproductive system in male albino rats. JOPAS. 2011; 3(3): 102-115.
- Prakash AO, Saxena V, Chand GK, Mathur R. Antifertility investigation on embelinan oral-contraceptive of plant-origin. Effect on Uterine Biochemical-Constituents of Ovariectomized Albino-Rats. Comparative. JOPAE. 1983; 8(4): 271-275.
- Jhon M, Cumberger H, Gandwinterhoff H. Oxidation product of caffeic acid mode of substance for the antigonadotrophic activity of plant extract. Planta Medica. 1989; 6: 14-17.
- Nikolić Z, Mrvić V, Ivanov I, Blagojević Z. Effect of neonatal estrogen and HCG treatment on the genital organs of adult female rats. ActaVeterinaria Hungarica. 1999; 47(1): 109-15.
- Lee CJ, Park H, HandKim JK. Natural and radiation induced degeneration of primordial and primary follicles in mouse ovary. ARS. 2003; 59(2): 109-117.
- Kaiser A, Gabari A, Habeb M, Majid M. Evaluation of the potential activity effect of fenugreek (*Trigonella foenum*) in female rabbits. IJBS. 2006; 7(3): 31-42.

دراسة نسيجية وامراضية مجسمة لتأثير بذور نبات الحلبة على المبيض في اناث الارانب

احمد سعد الاعرجي¹، تمارة ناطق داود²، وضياء عبد الأمير عبود¹

¹فرع التشريح و الانسجة، كلية الطب البيطري، جامعة بغداد، العراق، ²فرع الصحة العامة البيطرية، كلية الطب البيطري، جامعة بغداد، العراق

الخلاصة

هدفت هذه الدراسة إلى معرفة تأثير بذور الحلبة *Trigonella foenum-graecum* على الغدد التناسلية للإناث. تم استخدام عشرين أنثى محلياً في هذه الدراسة وتم تقسيم الحيوانات إلى أربع مجموعات (5 لكل مجموعة): المجموعة الأولى (G1) تم اعتبارها مجموعة السيطرة. المجموعة الثانية (G2) والمجموعة الثالثة (G3) والرابعة (G4) تم تغذيتها يومياً بنسبة 1.5% و 3% و 4.5% من بذور الحلبة-*T. Foenum graecum* على التوالي لمدة 60 يوماً (مرتين يومياً). في نهاية التجربة، تم قتل الحيوانات بطريقة القتل الرحيم باستخدام ثنائي إيثيلانثر (C2H52O). ثم تم شق البطن وتجميع عينات المبايض وتثبيتها بنسبة 10% من الفورمالين المتعادل. تم إجراء الفحص النسيجي باستخدام تقنية تضمين البارافين وتم صيغ السلايدات والعينات النسيجية بصيغة الهيماتوكسيلينوالأيوزين. أظهرت النتائج أن أعداد الحويصلات الأولية والثانوية انخفضت معنوياً ($p \leq 0.05$) في G3 و G4 مقارنة مع مجموعة السيطرة (G1) و G2. كانت أعداد حويصلات الجرافيان معنوياً ($p \leq 0.05$) أدت إلى انخفاض G4 مقارنة بالمجموعات الأخرى. كانت أقطار الحويصلات الأولية والثانوية والجرافيانية أقل بكثير من المجموعات الأخرى. سمك طبقة الخلايا الحبيبية في G3 و G4 كان أقل بكثير من المجموعات الأخرى. تشير الأرقام النسيجية إلى أن مبيض المجموعة الثانية G2 كان مشابهاً لمبيض G1. تم الكشف عن المقاطع النسيجية لـ G3 و G4 احتقان الأوعية الدموية القشرية والخاعية ونزيف بؤري ملحوظ. كما لوحظ وجود تنكس جرابي ونخر كبسي، وخلصت الدراسة إلى أن التركيز المنخفض لبذور *T. foenum-graecum* (الحلبة) ليس له أي تأثير إيجابي. من ناحية أخرى، أعطت التركيزات العالية نتائج سلبية بالإضافة إلى التأثير السلبي على الانسجة.

الكلمات المفتاحية: ارانب، بذور الحلبة، مبيض، جريبات مبيضية