

Histopathological study of the influence of platelet rich-plasma and low level laser therapy on healing of experimentally fractured proximal sesamoid bone in equine

Sinan A ; M J Eesa and Raffal A. Omar

Department of Surgery and Obstetrics, College of Veterinary Medicine, Baghdad University, Iraq.

E-mail: mohammed.jawad1956@gmail.com

Received: 27/1/2016

Accepted: 8/2/2016

Summary

The objective of this study was to evaluate the effects of platelet rich plasma and low level laser therapy (diode laser) on the healing of proximal sesamoid bone fracture. Eighteen healthy adult donkeys were divided into three equal groups: First group was used as control group, second group was treated by platelet rich plasma and the third group treated by diode laser. Also each group was divided to two equal subgroups according to period of postoperative macroscopical, histopathological examination: (one and three months post operation). All animals were exposed experimentally to transverse mid body fracture of lateral proximal sesamoid bone, in control group the bone fixed internally by screw and followed by external fixation with Plaster of Paris under general anesthesia, the second and third groups were exposed to similar surgical procedure except in second group injected of autologous platelet rich plasma in the fracture site, and the third group exposed to serial session of low level laser. All experimental animals were in a good health postoperatively, except hyper granulation tissue was observed in one animal belongs to the first group and another one belongs to the second group exhibited superficial exudates at the site of operation. Histopathological examination showed connective tissues and thin bone trabecular filling the fractured gap in first group at one month postoperatively, whereas, the bone trabecular was replaced by compact bone at three months postoperatively. Moreover lamellar bone and thick compact bone formation were seen at one month in third group, as well as to a lesser degree in the second group; however the fractured gap was filled with compacted bone mainly at three months postoperatively in third group. In conclusions, both laser and platelet rich plasma were enhanced healing of the proximal sesamoid bones fracture but the superiority of better healing was occurred by laser treatment.

Keywords: Proximal sesamoid bone, Low level laser, Platelet rich, Plasma, Fracture, Equine.

Introduction

The proximal sesamoid bones were paired bones consisting of spongy bone in its structure due to their position in the palmar/planter aspect of the fetlock. They give stability and support to the suspensory apparatus. These two bones act as single bone during the joint movement due to the attachment of inter sesamoid and ligaments on the axial aspect of both bones (1 and 2). Platelet rich plasma was prepared by centrifuging the blood with anticoagulant so it can be prepared easily and during the operation (3). Because of platelet rich plasma (PRP) is containing different growth factors and cytokines it can enhances the fractured bone and damaged soft tissue healing, for that reason studies advised to use PRP in inflammation, postoperative blood loss,

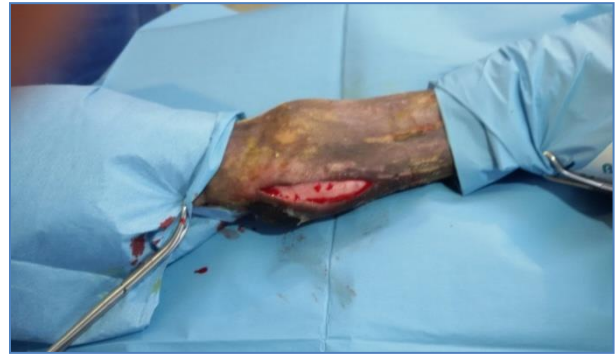infection, narcotic requirements, osteogenesis and wound, in addition to the local homeostasis at the sites of vascular injury (4). Laser effects on tissues may be attributed to thermal and non-thermal effects; the non-thermal effects of laser beam on tissue include photodynamic therapy and photobio-stimulation therapy. The beneficial biological effects of laser light therapy on tissues can accelerate tissue repairing and cell growth, improve vascular activity and increase metabolic activity (5). The use of laser could enhance callus development in the early stage of the healing process, with doubtful improvement in biomechanical properties of the healing bone; therefore, laser therapy may be recommended as an additional treatment in non-union fractures in humans (6). Our research tries to find the fate of proximal

sesamoid bones fracture healing histopathologically. The aim of this study was to evaluate the effects of PRP and low level laser therapy (diode laser) on healing experimental transverse proximal sesamoid bone fracture.

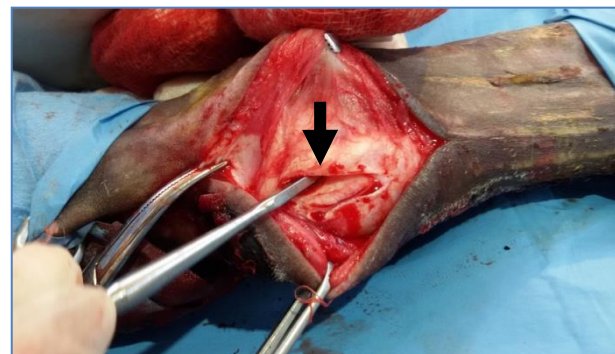
Materials and Methods

This study was carried out on eighteen apparently healthy donkeys; which were divided into three equal groups, first group (control group): In which transverse fracture of a lateral proximal sesamoid bone was made, and internal fixation (lag full-thread screw) was used to fix the two fragments of the fractured bone. Animals were allotted into two equal subgroups depending on macroscopical and histopathological examinations at one and three months post operation. The animals were fasted for 24 hrs. from food and 12 hrs. from water before the surgical operation. The surgical area which extended from mid-metacarpal bone up to the coronet was prepared aseptically. All operations were achieved under general anesthesia, intravenous administration of acepromazine 0.05mg/kg B.W. as a premedication, and after the appearance of action, a mixture of both chloral hydrate 50 mg and magnesium sulphate 25 mg at 7% was injected intravenously (7). The animal was placed on right lateral recumbency and 8-10cm longitudinal skin incision was made in the posterior aspect of the lateral proximal sesamoid bone of the left forelimb (Fig.1). Blunt dissection of subcutaneous tissue was done to identify the lateral proximal sesamoid bone. Then palpated groove between this bone and sheath of the superficial and deep digital flexor tendons and about 1.5-2cm longitudinal tendon sheath incision was made to investigate the area between tendons and lateral proximal sesamoid bone (Fig. 2). After these steps, the bone edge was clear and, mid fractured bone was induced by bone chisel (Fig.3). Electrical drill machine (0.8 Mm auger size) was used to induce longitudinal canal through two fragments of fractured bone, in order to facilitate insertion of lag full threaded screw (0.8 Mm size) (Fig.4). Normal saline was used during drilling to minimize heat, and screw driver was used to insert the

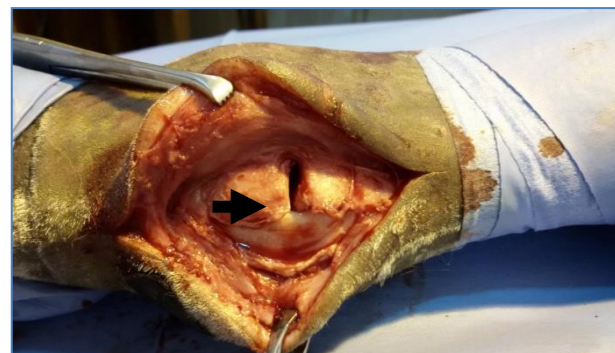screw in the canal upto approximate the two fragments of the fractured bone (Fig. 5).



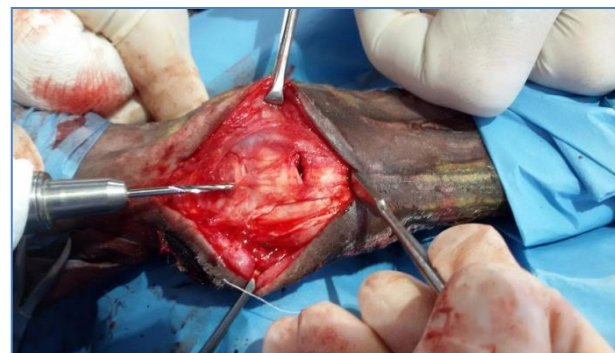Figure, 1: 18-10/cm longitudinal skin incision was made in the posterior aspect of the lateral proximal sesamoid bone of the left forelimb.



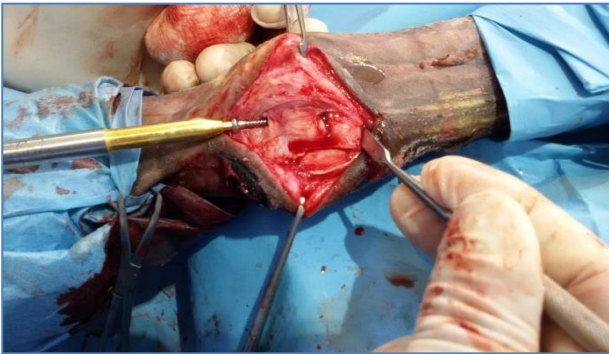
Figure, 2: 1.5-2cm longitudinal tendon sheath incision was made to investigate the area between the tendons and the lateral proximal sesamoid bone (arrow).



Figure, 3: Transverse fracture line in mid area of proximal sesamoid bone (arrow).



Figure, 4: Induce longitudinal canal through two fragments of fractured bone by (0.8 Mm) auger size (arrow).



Figure, 5: Screw driver used to insert the screw through the canal (arrow).

Polyglactine 910 (1.0 size) suture material was used to close the incision of tendon sheath by simple continuous pattern, and also subcutaneous tissue was closed by the same pattern. Skin was sutured routinely. Plaster cast with window was used to support internal fixation.

Penicillin and streptomycin (20,000 I.U, 20 mg/kg.B.w) respectively were injected intramuscular daily for four days postoperative, and dressing of wound was done daily until skin healing was completed and skin stitches were removed after 10-12 postoperative days. General conditions of animal such as appetite, movement, posture and surgical site through Plaster cast window were observed, daily in the first week post operation and weekly after that during the experimental period

Second group (PRP): Similar procedure as in the first group was done, but after internal fixation the fracture site was injected by PRP, which was prepared by collecting 20 ml of jugular blood sample from the same animal (autologous) before surgical interference in tubes with anti-coagulant (sodium citrate) and centrifuged at 2000 rpm for 20 minutes, where the upper layer was collected and centrifuged at 2000 rpm for 10 minutes. PRP from the resulting (1–1.5) ml sediment platelets were collected with small amount of plasma (8). PRP was administered at the site of the fracture via needle G 18. **Third group (laser group):** Surgical similar procedure (as in the first group) was done, but the fracture site was exposed to serial session of portable diode laser type K-laser.

K-Laser is the most versatile laser therapy in both power and frequency. Power can be adjusted from 100 mW (0.1 Watt) to 8000 mW

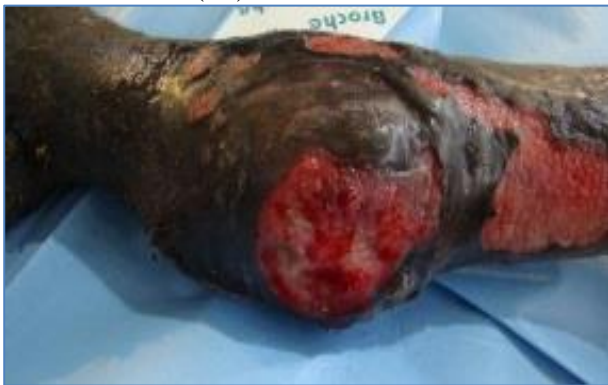(8 Watts) or 12,000 mW (12 Watts), and frequency from continuous wave (CW) to 20,000 Hz. Laser therapy was given for 3 days then 1 day rest and continued as the same system for three weeks in which 15 min. per day for each session (9). The dose was measured in joules, and means that a certain amount of energy per cm^2 (J/cm^2) Supplied: Dose= Time \times Treatment laser power per cm^2 (10).

Biopsies of Proximal sesamoid bone had been taken under aseptic technique with same regime of general anesthesia. The operation was started by skin incision over the fractured bone, then blunt dissection of tissue around the Proximal sesamoid bone was done to separate the bone from the surrounding tissues. Biopsy was kept in formalin buffer solution for 72 hrs. The samples were decalcified by using formic acid and sodium citrate (11) and then serial routine processes to prepare the paraffin section 4-5 μm thickness of tissues and stained by H and E. and Masson Trichrom Stain. The histopathological results were evaluated by scoring system according to the (12 and 13). The results were expressed as Mean \pm S.E. Data submitted to statistical analysis by using (ANOVA) and (LSD) used to differentiate among the means of parameters by using (SPSS) (14).

Results and Discussions

The physical parameters of experimental animals were within the normal level, but one animal in control group was suffering from hyper granulation tissue formation at surgical site (Fig. 6). This hyper granulation may be due to increase skin tension below the carpal and tarsal joints and increase movement in this area; this observation was coincided with others, they mentioned that the lower leg skin wounds have slower rates of wound contraction than those on the shoulder (15). Also this results was in agreement with previous work (16). It was reported that hyper granulation tissue was formed in wound healing below the carpal or tarsal joint in equine. One animal in the second group was exhibited superficial exudates at surgical site, this may be due to wound infection and this infection was treated through administration of systemic antibiotic and dressing by povidone

iodine for five days until healing. The clinical observation of walking after one month post-operative showed that animals in third group were able to bear weight on treated limb but lesser degree in other two groups was observed, while at the ends of three months, it revealed that animals in second and third group were normal in movement, but in control group the animal still lame. These observations may be related to effect of Laser on bone healing. This fact agree with other finding, who reported that Laser improved bone healing by increase osteoblastic proliferation, collagen deposition and new bone formation when compared to non-irradiated bone(17).



Figure,6: Shows the hyper granulation tissue formation at the surgical site for the control group.

Macroscopicall examination at one month postoperative, in control and second groups, the fracture line was filled with semi hard tissue during palpation and the fracture gap was appeared narrow in second group as compared with the control group(Fig. 7 and 8). While in the third group the texture of fracture line was more hard(by palpation) and narrow than in control and second groups(Fig. 9). This observation, may be related to the nature of tissue formation in fracture site in which more extensive tissue formation in the third group compared with other two groups it might be attributed to the important role of Laser in fracture healing as it improve vascularization of tissue (18). The narrowing of fracture gap in PRP group in comparison with control group might be due to the action of platelets growth factors. This fact was reported and explained that PRP enhanced the fracture healing; due to the higher concentrations of growth factors are present in PRP-bone graft material mix and have a greater response for osteogenesis as

compared to a physiological blood clot(3). Three months post-operation the fracture line was narrow and slight visible in second and third group post-operation (Fig.10 and 11). This variation might be owing to the action of platelet growth factors in the stimulation of osteoblast cells activity. This was coincid with other finding described that PRP and its soluble fraction stimulate the osteoblast differentiation in the presence of BMP-2, BMP-4, BMP-6 or BMP-7(19). The Laser could stimulate the collagen fibers to arrange in a lamellar structure and stimulate the mineralization in the new bone formation during surgically created bony defects (20).

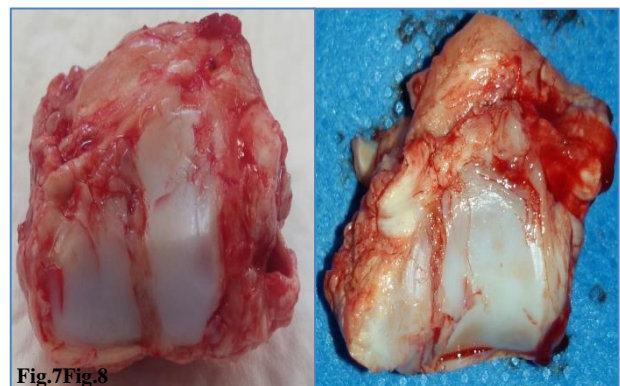
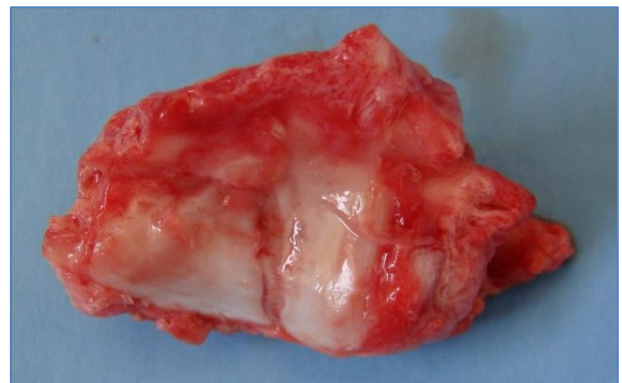

Fig.7Fig.8

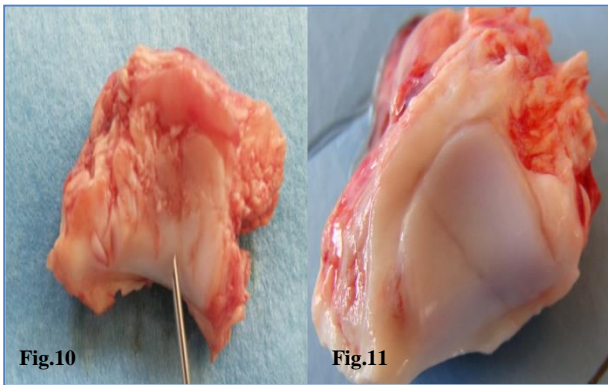
Figure, 7: Shows the fracture line filled with mass of tissues, at one month post operative for the control group.

Figure, 8: Shows fracture line filled with a dense mass of tissues at one month post operative for the second group.



Figure, 9: Shows fracture line filled with a dense mass of tissues at one month post operative for the third group.

The histopathological findings at one month revealed that, in control group the fracture gap was infiltrated with inflammatory cells, congested blood vessels, collagen and curved woven bone in addition to thin layer of trabecular bone (Fig.12-14).

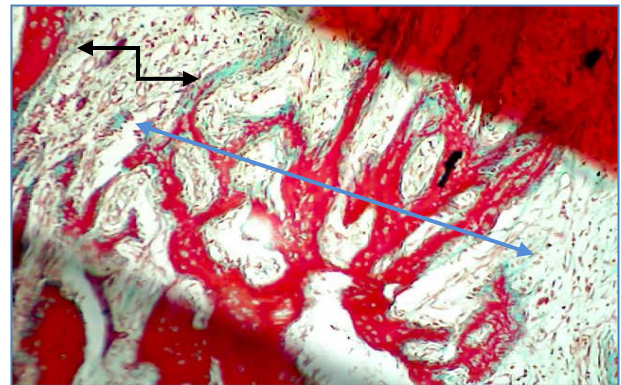


Figure, 10: Shows slight visible fracture line at three months post-operative for the second group.
 Figure, 11: Shows slight visible fracture line at three months post-operative for the third group

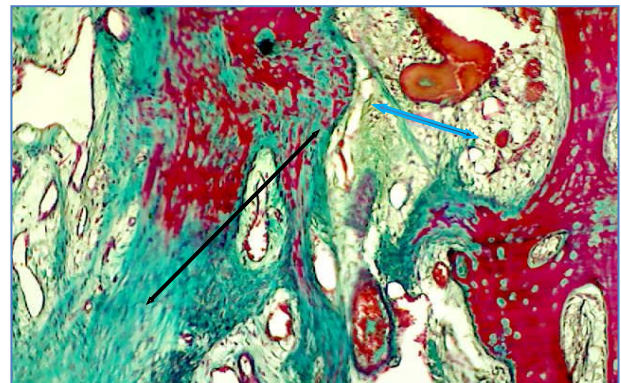
The inflammatory cells were still, this fact might be due to sesamoid bone was located under tension because of its attachment which connected with many ligaments and micro movement occurred which prolonged period of inflammatory phase. Other studies (21 and 22), revealed that during the inflammatory phase, a primitive callus was developed and reduced the uncontrolled mobility at the fracture site. Under a normal condition, the inflammatory phase is fastened and lasts up to one week after the fracture, endothelial cells, fibroblasts and osteoblasts were precipitated for filling the fracture gap by formation of granulation tissue. While in second group slight granulation tissue, more woven bone and trabecular bone were formed as compared with the control group at same period (Fig.15 and 16). The conversion of trabecular bone into bone lamellae was not seen in the control group at same period. This development may be due to the action of growth factor of PRP which plays an important role in fracture healing this was previously reported that PRP has been shown to activate osteoblasts and fibroblasts to produce additional growth factors (23). PRP is being used in delayed and non-union fracture cases because accelerate healing. Whilst in the laser group there was a mature trabecular bone, thickened layer of bone lamellae and small area of compact bone, with slight granulation tissue(Fig.17 and 18). Laser therapy might be increased osteogenesis; this was coinciding with other investigations (17 and 24).

In control group, at three months post-operation conversion of trabecular bone compact bone in fractured gap, was seen

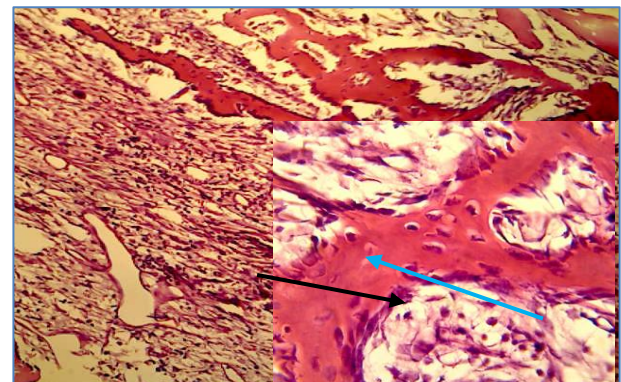
beside that newly formed trabecular bone in granulation tissue and infiltrated with mononuclear cells (Fig. 19). This fact might be due to the characters of the proximal sesamoid bones, as it was under tension and has spongy structure. Others (25) referred that the healing of proximal sesamoid bone fracture usually occurs by fibrous tissue union or nonunion may resulting in stability of the fetlock joint.



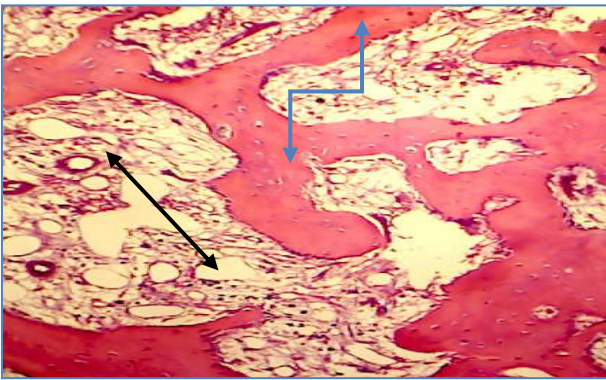
Figure, 12: longitudinal section of fractured bone, , Shows fibrous connective tissue infiltrated by inflammatory cells (Black arrows) and it converted into curved woven bones (Blue arrows) that contact both sides of fragment ends in control group, one month post-operative (Masson Trichrom Stain 100X).



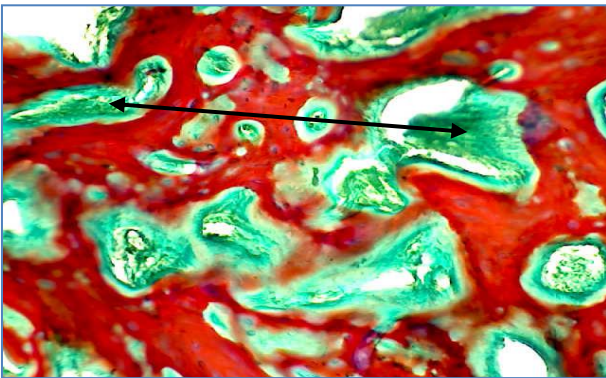
Figure,13: Shows highly cellular trabecular bone (Black arrows) extended in the pinkish granulation tissue (Blue arrows) in control group, one month post-operative (Masson Trichrom Stain 100X).



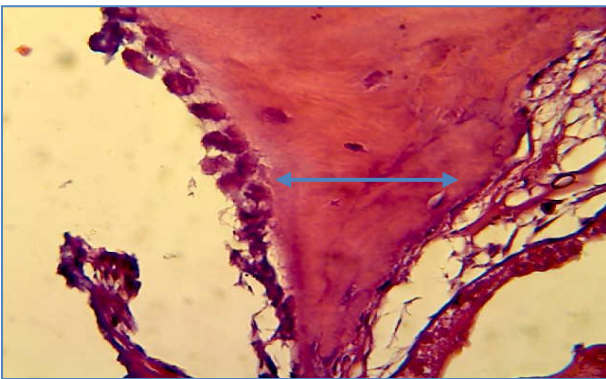
Figure, 14: Shows the gap of fracture was filled with woven bone characterized by high cellular with large cavity (Blue arrow) lining by active osteoblasts (Black arrow) with mononuclear cells infiltration in the granulation tissue in fractured gap in control group, one month post-operative (H and E stain 40X).



Figure, 15: Shows the gap of fracture was filled with granulation tissue (Black arrows) and thin trabecular bone contacted the (Blue arrows) two ends of bone fragments in second one month post-operative group (H and E stain 100X).



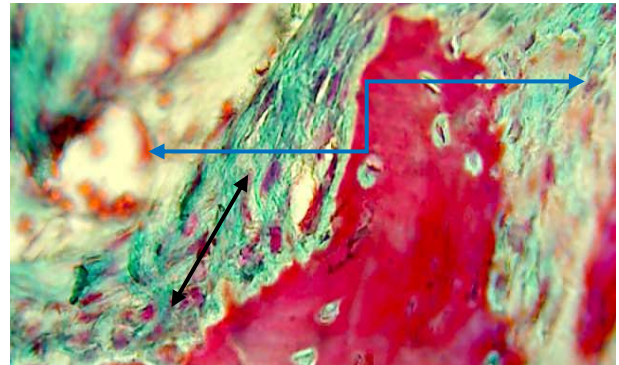
Figure, 16: Shows the gap of fracture was filled with thin trabecular bone contacted the two ends of bone fragments with connective tissue (Black arrows) in second group, one month post-operative (Masson Trichrom Stain 100X).



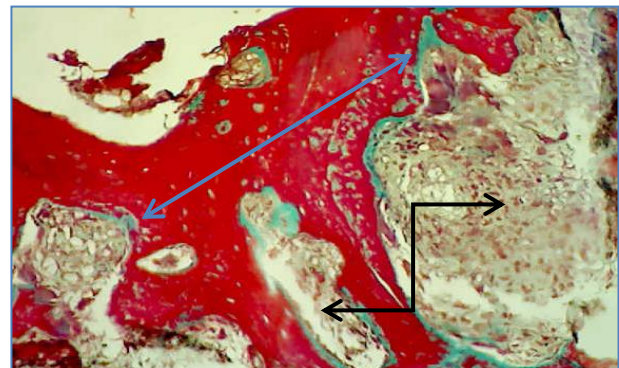
Figure, 17: In third group, one month post-operative, Shows thickened lamellar bone lining by active osteoblasts (Blue arrows) extended to vascular connective tissue in fractured gap In third group, one month post-operative (H and E stain 40X).

The second group showed thickened trabecular and compact bone, which connected two ends of fracture. In addition there were slight inflammatory cells as compared with the control group at the same period (Fig. 20). This indicated that PRP accelerated osteogenesis leading to efficient filling of fractured gap by osteoid tissue. These observations were agreed with (26) who described that platelets release many bioactive proteins responsible for attracting

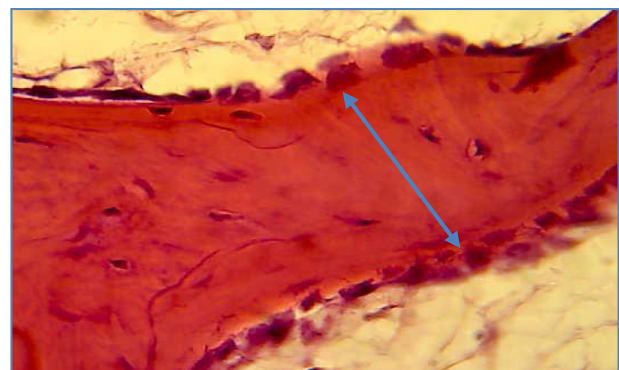
macrophages, mesenchymal stem cells, and osteoblasts which enhances tissue regeneration and healing.



Figure, 18: in third group, one month post-operative, Shows thickened lamellar bone lining by active osteoblasts (Black arrows) extended to vascular pinkish connective tissue (Blue arrows) in fractured gap one month post-operative (Masson Trichrom Stain 40X).



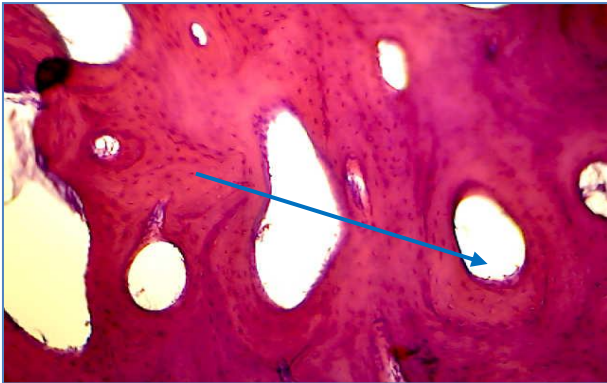
Figure,19: Shows highly cellular trabecular bone extended from one end of fracture bone to other end (Blue arrows)through granulation tissue which stained with pinkish color in fractured gap (Black arrows) in control group, three months postoperative (Masson Trichrom Stain 40X)



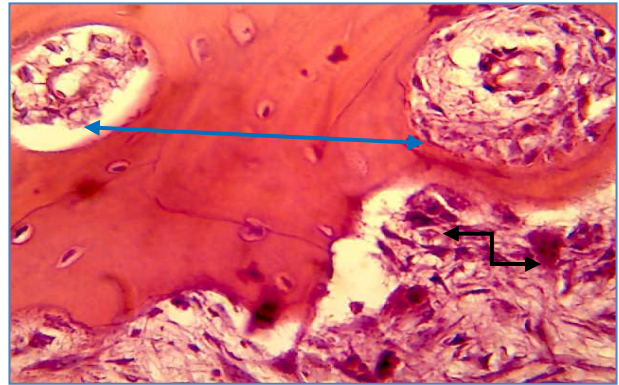
Figure,20: in second group, three months post-operative, Shows thickened trabecular bone lining by active osteoblasts in fractured gap(Blue arrows) in second group, three months post-operative (H and E stain 40X).

In the third group, the fractured gap was filled with compact bone associated with Haversian canal. There was a slight amount of granulation tissue converted into compact bone (Fig.21 and 22).These results might be owing to the effect of LLLT on fracture healing.

Other researchers (27) recorded that affirm LLLT could accelerate the bone formation by increasing the osteoblastic activity. The data analysis of histopathological scoring between groups were referred that significant differences in filling of the defect with more bone than fibrocartilage among three groups. Also bone defect closure was a significant difference between control with third and second with third group (Table, 1).



Figure, 21: Shows compact bone with large haversian canal lining by osteoblast (Blue arrow) contact both end of fragment bone in third group, three months post-treatment (H and E stain 40X).



Figure, 22: Shows compact bone with large haversian canal lining by osteoblast (Blue arrows) and osteoclasts in granulation tissue in (Black arrows) fractured gap in third group, three months post-operative, (H and E stain 40X).

These observations were coincide with other finding, whom reported that LLLT can favor bone formation with bone defect (28). Also platelets growth factors were increased proliferation of osteoblasts and enhance bone healing. This phenomena was consisting with (3) who registered that PRP was accelerated fracture healing.

Table, 1: Scoring of histopathological evaluation of the fracture healing (mean ± SE) (12 and 13).

Group and time	First group		Second group		Third group	
	30 n=6	90 n=3	30 n=6	90 n=3	30 n=6	90 n=3
1. Union No sign of union	0	0	0	0	0	0
Osteochondral union	5.8333±.16667	2.8333±.16667	5.8333±.16667	2.8333±.16667	5.8333±.16667	0
Bone union	A 0	Ab 0	A 0	Ab 0	a 0	Bb 2.8333±.16667
2. Cancellous bone No osseous cellular activity	0	0	0	0	0	0
Early apposition of new bone	2.8333±.16667	0	0	0	0	0
Active apposition of new bone	Aa 2.8333±.16667	b 0	B 2.8333±.16667	0	B 2.8333±.16667	0
Reorganizing cancellous bone	A 0	Ab .8333±.16667	A 2.8333±.16667	Bb .8333±.16667	a 2.8333±.16667	Bb 0
Complete reorganization of cancellous bone	Bb 0	Aa 0	Aa 0	Ab 1.8333±.16667	Aa 0	Bb 2.8333±.16667
3. Filling of defect with more fibrous tissue than fibrocartilage	5.8333±.16667	0	0	0	0	0
More fibrocartilage than fibrous tissue	Aa 0	b 0	B 1.8333±.16667	0	B 0	0
More fibrocartilage than bone	B 0	Aa .8333±.16667	Aa 2.8333±.16667	b 0	B 3.8333±.16667	0
More bone than fibrocartilage	B 0	Aa 1.8333±.16667	Ba .8333±.16667	Bb 2.8333±.16667	Aa 1.8333±.16667	Bb 1.8333±.16667
Filled only with bone	Cb 0	Ba 0	Bb 0	Aa 0	A 0	B .8333±.16667
4. Bridging of the bone defect No bridging of bone defect	0	B 0	0	B 0	b 0	Aa 0
Bridging with fibrous tissue	3.8333±.16667	0	1.8333±.16667	0	0	0
Bridging with fibrous and cartilaginous tissue	Aa 1.8333±.16667	b 2.8333±.16667	Ba 3.8333±.16667	b 2.8333±.16667	B 5.8333±.16667	B .8333±.16667
Bone defect closure	Cb 0	Aa 0	Ba 0	Bb 0	Aa 0	Cb 2.8333±.16667
		B 0		B 0	b 0	Aa 2.8333±.16667

Capital letters refers to significant difference between groups (P<0.05).

Small letters refers to significant difference between periods in the same group (P<0.05).

References

1. Kainer, R. A. (1987). Functional anatomy of equine locomotor organs, in Stashak TS (ed): Adams' Lameness in Horses. Philadelphia, Lea andFebiger, Pp:10-18.
2. Bertone, A.L. (1996). Fractures of the proximal sesamoid bones; in Nixon (ed): Equine Fracture Repair. Philadelphia; WB Saunders Co, Pp:163-171.
3. Schulz, K. (2015). Platelet Rich Plasma, regenerative medicine chapter of Small Animal Surgery, Peak Veterinary Referral Center www.peakveterinaryreferral.com, 158 Hurricane LaneWilliston.
4. Anitua, E.; Sanchez, M.;Nurden, A.T.; Nurden, P.; Orive, G. andAndia, I. (2006). New insights into and novel applications for platelet-rich fibrin therapies. Trends Biotechnol., 24:227-234.
5. Sells, B. (2002). Laser Physiological and Biological Effects. Vista prints California.
6. Kazem, S. S.; Soleimanpour, J.; Salekzamani, Y.; Oskuie, M.R. (2010). Effect of low-level laser therapy on the fracture healing process. Lasers Med Sci., 25(1):73-77.
7. Jim, E., Riviere Mark, G., Papich, H., Richard Adam (2013). Veterinary pharmacology and therapeutics 9^{ed}. Wiley-Blackwell. Pp:290-293.
8. Rachita, D. (2014). Principles and Methods of Preparation of Platelet-Rich Plasma: A Review and Author's Perspective. J.Cutaneous and Aesthetic Surg., 7(4):189-197.
9. Ueda, Y., Shimizu, N. (2001). Pulse irradiation of lowpower laser stimulates bone nodule formation. J Oral Sci, 1:55-60.
10. Jan, Thomas. (2010). Therapeutic laser buyer's guide .Trends magazine, November/ December 2010.
11. Luna, G. (1968). Manual of histological staining methods of the armed forced institute of pathology. 3rd Ed. McGraw Hill book Co. New York. Pp: 71- 98.
12. Verhaar, H.J.J. And Lems, W.F. (2010). analogues and osteoporotic fractures. Expert Opin. Biol. Th., 10:1387-94.
13. Oryan, A.; Moshiri, A.;Meimandiparizi, A. H. (2013). Effects of sodium-hyaluronate and glucosamine chondroitin sulfate on remodeling stage of tenotomized superficial digital flexor tendon in rabbits: a clinical, histopathological, ultrastructural, and biomechanical study. Connective Tissue Res., 52:329-39.
14. SAS.(2008). Statistical analysis system for windows V.6.12.
15. Jacobs, K. A.; Leach, D. H.; Fretz, P. B. and Townsend, H. G. G. (1984).Comparative aspects of the healing of excisional wounds on the leg and body of horses. Vet. Surg., 13(2):83-90.
16. Bader,O.A.;Eesa, M.J. (2011). Treatment of hyper-granulated limb wounds in horses. Iraqi J.Vet.Sci., 25(2):71-80.
17. Lopes, C. B.; Pacheco, M.T.T.; Silveira, J. (2007). The effect of association of NIR laser therapy BMPS, and guides bone regeneration on tibial fractures treated with wire osteosynthesis: raman spectroscopy study. J. photochem.Photobiol., 89(2-3):125-130.
18. Mercia, J. S.; Luis, A.; Michyele C.; Sbrana, G. F.; Accácio, L. and Ana, P.F. (2014). Effect of Low-Level Laser on Bone Defects Treated with Bovine or Autogenous Bone Grafts: In Vivo Study in Rat Calvaria. Bio. Med. Res. Int. J., 104230: 9.
19. Tomoyasu, A.; Higashio, K.; Kanomata, K.; Goto, M.; Kodaira, K.; Serizawa, H.; Suda, T.; Nakamura, A.; Nojima, J.; Fukuda, T. and Katagiri, T. (2007). Plateletrich plasma stimulates osteoblastic differentiation in the presence of BMPs. Biochem. Biophys. Res. Commun., 361:62-67.
20. Wowapi. (2002). Understanding low level laser therapy. J. Am. Vet. Med. Assoc., 55(8):5-83.
21. Brandi, M. L. (2010). How innovations are changing our management of osteoporosis. Medicographia, 32:1-6.
22. Goldhahn, J.;Fron, J.M.; Kanis, J. (2012). Implications for fracture healing of current and new osteoporosis treatments: an ESCEO consensus paper. Calcified tissue Int., 90:343-53.
23. Marx, R.E. (2006). Commentary on: Bone regeneration in standardized bone defects with autografts or bone substitutes in combination with platelet concentrate: A histologic and histomorphometric study in the mandibles of minipigs. Int. J. Oral Maxillofac. Implants, 21(2): 190-192.
24. Tavares, M.R.; Mazzer, N. and Patorello, M. (2005). Efeitodo laser

- terapêuticonacicatrizaçotendinosa. Estudo experimental em ratos. Fisioter. Bras., 6:96-100.
25. Jeremy, D.; Hmubert, F. G.; Latimer, R. M. and Moore. (2001). Proximal Sesamoid Bone Fractures in Horses; Equine Compendium J., 23(7):678-687.
26. Marx, R.E. and Garg, A.K. (2005). Dental and Craniofacial Applications of Platelet-Rich Plasma. Carol Stream: Quintessence Publishing, 39:31-49.
27. Shakouri, S. K.; Soleimanpour, J.; Salekzaman, Y. and Oskuie, M.R. (2009). Effect of low level laser therapy on the fracture healing process. Laser in medical Sci., 25(1):73-77.
28. Khadra, M.; Kasem, N.; Haanaes, H. R.; Ellingsen, J. E. and Lyngstadaas, S.P. (2004). Enhancement of bone formation in rat calvarial bone defects using low-level laser therapy. Oral Surg. Oral Med. Oral Pathol. Oral Radiol. Endod., 97:693-700.

الدراسة النسيجية المرضية لتأثير الصفائح الدموية الغنية بالبلازما و الليزر واطئ الطاقة على شفاء الكسر التجريبي لعظم السمسماني الداني في الفصيلة الخيلية : الجزء I

سنان عدنان محمد نوري و محمد جواد عيسى و رفل عبد الدائم عمر

فرع الجراحة والتوليد، كلية الطب البيطري، جامعة بغداد، العراق.

E-mail: mohammed.jawad1956@gmail.com

الخلاصة

هدفت الدراسة الى تقييم تأثيرات المعالجة بالبلازما الغنية بالصفائح الدموية والليزر واطئ الطاقة على شفاء كسر العظم السمسماني الداني. تم استخدام ثمانية عشر حماراً بالغاً وكانوا ظاهرياً بصحة جيدة. قسمت هذه الحيوانات الى ثلاث مجاميع متساوية المجموعة الاولى: (مجموعة السيطرة)، المجموعة الثانية: (المجموعة المعاملة بالبلازما الغنية بالصفائح الدموية) اما المجموعة الثالثة فهي (المجموعة المعالجة بالليزر واطئ الطاقة) وقسمت كل مجموعة الى مجموعتين فرعيتين متساويتين اعتماداً على المتابعة العيانية والنسجية المرضية بعد العملية لفترتين: شهر وثلاثة اشهر. اجري كسر مستعرض في وسط العظم السمسماني الداني الوحشي لجميع حيوانات التجربة تحت تأثير التخدير العام وهي المجموعة الاولى واستعملت البراغي لغرض التثبيت لطرفي العظم المكسور فضلا عن دعم التثبيت الداخلي بالتثبيت الخارجي باستعمال الجبيرة اما في المجموعة الثانية اتبعت نفس الخطوات ماعدا استعمال البلازما الغنية بالصفائح الدموية المحضرة نفس الحيوان حيث حققت في مكان الكسر بعد التثبيت. بينما في المجموعة الثالثة تم استعمال الليزر واطئ الطاقة. لعدة جلسات اظهرت النتائج ان كل حيوانات التجربة كانت بصحة جيدة ما بعد العملية، ماعدا حيوان واحد بمجموعة السيطرة عانى من فرط في النسيج الحبيبي في منطقة العملية، كذلك حيوان واحد في المجموعة الثانية اظهر نضحة سطحية في منطقة العملية. اظهرت نتائج الفحص النسيجي المرضي وجود نسيج حبيبي مع طبقة رقيقة من العظم التربيعي والذي مليء فجوة الكسر بعد شهر من العملية في المجموعة الاولى وبعد ثلاثة اشهر تحول الى العظم المصمد بينما ظهر العظم المصمد نهاية الشهر الاول في المجموعة الثالثة واقل درجة في المجموعة الثانية، وقد مليء العظم المصمد فجوة الكسر نهاية الشهر الثالث في المجموعة الثالثة. استنتج من هذه الدراسة ان استعمال الليزر واطئ الطاقة والبلازما الغنية بالصفائح الدموية سرع شفاء الكسور للعظم السمسماني الداني ولكن الافضلية لمجموعة المعالجة بالليزر واطئ الطاقة. الكلمات المفتاحية: العظم السمسماني الداني، الليزر واطئ الطاقة، البلازما الغنية بالصفائح الدموية، الكسور، الخيول.